

## Auricular prosthesis: A ray of hope

Arun Kumar N.<sup>1\*</sup>, Chitturi Ravi Kumar<sup>2</sup>, Duggineni Chalapathirao<sup>3</sup>, Gurram Sunil Kumar<sup>4</sup>

<sup>1</sup>PG Student, <sup>2</sup>Professor & HOD, <sup>3</sup>Professor, <sup>4</sup>Reader, Dept. of Prosthodontics, Mamata Dental College, Telangana

**\*Corresponding Author:**

Email: dr.arunrathod99@gmail.com

### Abstract

The absence of an associated part of an ear may be a considerable aesthetic drawback which affects the patient's scientific discipline and social behaviour. Prosthetic rehabilitation of auricular defects is often a demanding procedure due to broad variety of clinical approaches and a wide array of treatment options. This can be corrected surgically, prosthetically or through a combination of these approaches, however the choice of treatment depends on patient. Auricular prostheses have been retained by methods including implants, adhesives and spectacle frames however the selection of repair ultimately depends on patient factors, amount of soft tissue loss, and replacement of auricular defect. The patients opt for prosthetic rehabilitation over surgical procedures and retention became an essential issue in this approach. Replacement of such parts for restoring their loss of function and esthetics is done by using numerous biocompatible materials, strategies we tend to select new materials and used latest technology to ensure the best quality prosthesis. This case report describes the clinical and laboratory procedure for fabricating an auricular prosthetic device for a patient with trauma associated unilateral auricular deformity.

**Keywords:** Auricular defect, Maxillofacial prosthesis, Adhesive retained prosthesis, Room temperature vulcanizing silicone, Auricular prosthesis.

### Introduction

Facial tissue defects may be acquired, congenital. Facial deformity can cause functional and serious psychological issues that may affect an individual's social behaviour.<sup>(1,2)</sup> The field of maxillofacial prosthetics concerns with the prosthetic reconstruction of missing/disfigured head and neck tissue.<sup>(3)</sup>

Auricular reconstruction could be a difficult task for surgeons since it is a field of facial cosmetic surgery within which a large array of rehabilitative choices typically should be considered.<sup>(4)</sup> Ear is a major part of middle third of the face. Although it is a vital organ to facilitate hearing by receiving and diverting sound waves, it can also contribute to the aesthetic part of the face, such patients suffer from psychological and emotional stress, mostly from the cosmetic aspect.<sup>(5)</sup>

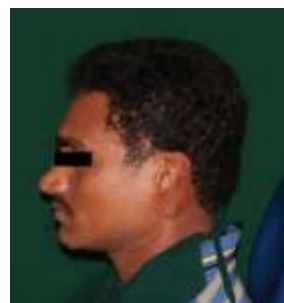The various treatment choice present now a days include traditional mechanically retained prosthesis, bio-adhesive retained prosthesis, implant retained and the recently developed rapid prototyping and computer aided designing - computer aided machining (CAD-CAM) developed prosthesis.<sup>(6)</sup>

Long term success of facial prosthesis depends primarily on retention and the maxillofacial prosthesis are retained with varied methods of retention like medical grade adhesives, anatomical undercuts, and mechanical devices like spectacles, hair bands, magnets, and implants.<sup>(7)</sup>

### Case Report

A 25-year-old patient visited the department of prosthodontics, with chief complaint of deficient left auricular tissue and wanted to get it corrected with an artificial prosthesis. Patient gave a history of trauma to the left ear because of electrocution. Burnt part with

irregular and keloid surface on the left side of the head. The wound was fully healed and the surrounding skin showed no signs of inflammation and infection. (Fig. 1)



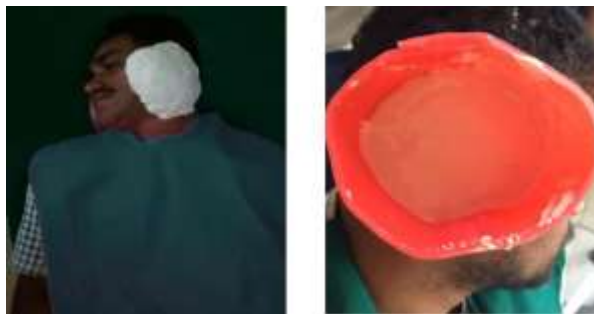
**Fig. 1: Lateral view showing auricular defect**

Clinical examination disclosed deformed helix, antihelix, concha, anti-helical fold, and lobules, but a part of tragus is left. The cartilaginous parts were completely missing. Only the dermis was present. Hence, ear prosthesis was fabricated to camouflage the damaged ear. The restorative choice like surgical autogenous reconstruction implant retained with soft tissue undercuts and skin adhesives were explained to the patient. Because the patient was apprehensive for surgical procedures, he opted for the prosthetic approach. Thus, the silicone prosthesis was opted as the treatment of choice.<sup>(8)</sup>

Patient education and counseling was done regarding the nature of function and limitation of the prosthesis. A written informed consent was secured and pre-operative photography was performed for assessment and evaluation.

**Procedure:** The patient was seated in a dental chair in upright position. He was draped such that only the rudimentary ear and a small area around it was exposed and his hair was protected by surgical cap covering the hairline and showing the prevailing condition of both the right and left ear. The external auditory meatus was sealed with gauze to prevent entry of impression material. Petrolatum was applied to the rudimentary ear and the skin around it. Impressions of the auricular defect were taken with irreversible hydrocolloid, (Algitex, Dental products India) following standard procedures. A double sided open cylindrical container of about 6 inches diameter, beaded with modeling wax was used to support the hydrocolloid impression material. A backing of plaster was given to support the impression. When set, it was removed keeping in mind the angle of existing undercuts to avoid tearing. The impression was inspected for accuracy. (Fig. 2, a) the impression was then poured with type IV die stone, by the standard procedures.<sup>(9)</sup> (Fig. 3)

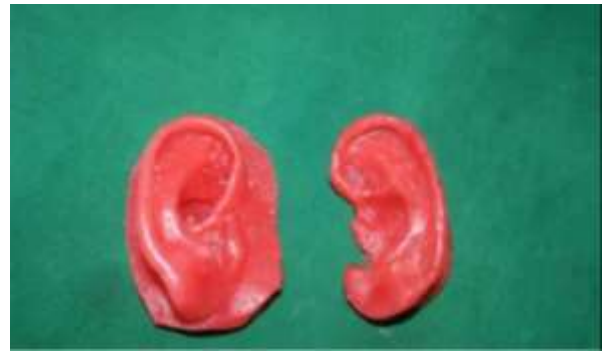Similar impression procedures were carried out for the contra lateral ear, in this case which is the right ear. (Fig. 2, b) Impression was poured with modelling wax. (Fig. 4, a)



**Fig. 2(a, b): Alginate impression of defect ear and contra lateral ear**



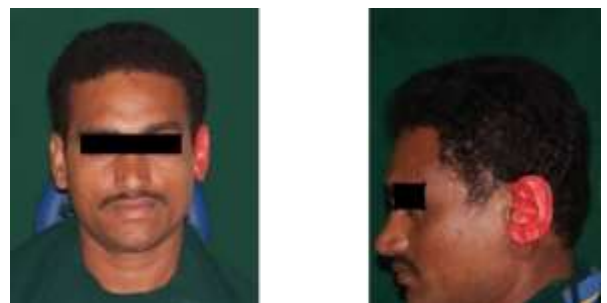**Fig. 3: Type IV gypsum cast of defect ear**



**Fig. 4 (a, b): Wax pattern of contralateral & defect ear**

A measurement of the patient's normal ear (right ear) was done with the calipers. The dimensions measured were the entire length of the ear, the antero-posterior dimension, the height of elevation of the pinna from the skin below the dorsal surface of the ear. The form and pattern of the helix, anti-helix, conchae and lobule. A donor ear of same dimension was chosen, an irreversible hydrocolloid, (Algitex, Dental products India) was placed on the donor ear supported by an Impression plaster to get the impression of the right ear. Melted modeling wax was then poured into the donor ear impression and allowed to cool down completely to avoid distortion. This could permit us to have a frame – work to do carving of the ear for the design of prosthesis.

Two uniform layers of sodium alginate (DPI, cold mould seal) separating medium was applied on the cast of defect, the wax pattern retrieved from the alginate impression of the donor ear was placed on the same. Free hand carving keeping the contra lateral ear model as reference was done (Fig. 4, b) with an effort to simulate the same ear it was then tried on the patient face for proper orientation superior-inferiorly and antero-posteriorly. A thorough assessment was done, Checking the prosthesis both from frontal and profile views. Due consideration was given to patient feedback regarding any modification with in the pattern. The wax pattern was optimally retentive and stable on his face.



**Fig. 5(a, b): Wax pattern trial procedure on patient**

A three part flasking was planned. The first half was to seat the bottom of rudimentary ear with its type II gypsum base. Modeling wax was used to give support to the second pour of type-II gypsum for the flasking.

Sodium alginate separating media was added and also the middle part of customized flask was poured. It was made sure that no gypsum flowed into any undercut of the wax pattern as this would cause a deformation of the pattern when removal of the middle part of the flask is attempted. Following this another modeling wax supported pour of type-II gypsum was made covering the ventral surface of the auricular wax pattern. Dewaxing procedures were performed in a very hot water bath, using the standard directions.<sup>(7)</sup> (Fig. 6)



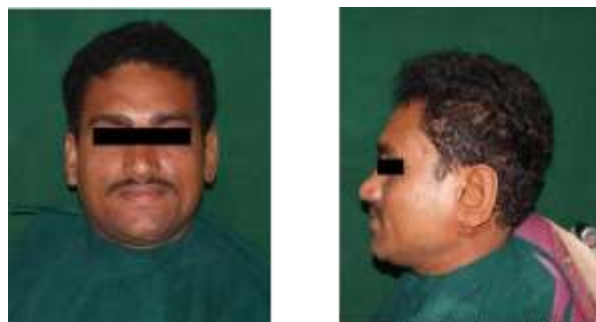**Fig. 6: Three pour flasking**

Shade selection using intrinsic coloration procedures were decided intrinsic stains (MP sai, enterprise) provided with the room temperature vulcanizing (RTV) silicone (MP sai, enterprise) was used for shade matching. Basic colors used were yellow, white, brown, purple and red. Little amounts of the base and catalyst pastes were mixed and incremental adding of the stains gradually was done with the constant comparison with the skin of the approximating area and also the contralateral ear. Separate shades were decided to accurately replicate the various components of the patient's natural ear. Different shades were chosen for the lobule, concha, helix, and anti-helix.<sup>(10)</sup> nearest possible simulation was tried to achieve by performing shade selection under different light sources, which consists of incandescent, fluorescent and natural sun light sources.

Packing of the tinted silicone material was done and the three parts of the flask were again re attached and seated to make sure that all the margins were flushed together. A time period of 48 hours was allowed to elapse as per the manufacturer's directions before opening the flask. The silicone prosthesis was then

examined for defects and porosities before being trimmed and finished by using a sharp pair of parrot beak scissors.

The final prosthesis was then tried on the patient, retention of the prosthesis was achieved by spraying skin adhesive (medical grade adhesive, cosmosil) on to the fitting surface for 1 to 2 minutes, the adhesive turns clear in color which gives the patient a sign that the prosthesis is ready to be secured.<sup>(11)</sup> (Fig. 7)



**Fig. 7: Silicone ear prosthesis retained with adhesive**

The patient was suggested to use the prosthesis frequently and avoid exposure to direct sun due to the limitations of silicone used for the fabrication of the same. He was instructed to regularly clean the prosthesis with a mild sodium lauryl sulphate solution. Use of strong detergent solutions and hard brushes for cleaning the prosthesis was discouraged. Patient was educated to maintain the skin surface clean and free from natural oil secretions to make sure proper adhesion of the prosthesis. He was educated not to wear the prosthesis while sleeping as accidental pressure would lead to distortion or tearing of the prosthesis.

A regular follow-up and evaluation of the patient and the prosthesis was undertaken to ensure that there are no eruptions and proper maintenance of the prosthesis was being carried out.

## Discussion

Loss of external ear can be congenitally missing or acquired because of accidental trauma or malignant disease. The patient referred in this article had a unilateral missing ear.<sup>(12)</sup>

Patient with auricular deformity or absence of auricle endures psychological affliction. The aim of maxilla facial rehabilitation is to provide a suitable prosthesis for patient with facial defects so that they can confidently face the society and accept the challenges of life.

Auricular defect can be repaired or reconstructed with autogenous tissue, however this might not be feasible for personal or medical reasons. A better alternative is to develop an auricular prosthesis with a suitable material. Hence, silicone is the material for choice for facial prosthesis due to its flexibility and life like appearance.

In this case, RTV silicone (MP sai, enterprise) was used. Intrinsic stains were used for the prosthesis coloration as these are more color stable and provided good esthetic results. Accelerated ageing studies and color evaluation studies using the reflection spectrophotometer analysis have shown that intrinsic stains undergo significantly less amount of color alteration as compared to extrinsic coloration methods. Moreover inorganic stains proved to be more color stable as compared to organic stains derived from plants and other natural sources. Hot, humid conditions and contact of the material with sweat, dust, pollen and other offenders only hastens the hardening and discoloration process. Gradual hardening and discoloration takes place over time period, however the material still remains in considerably acceptable condition for about 9 to 12 months. For retention of the prosthesis bio adhesive is not soluble in water so provided higher retention for more time period as it did not get dissolved when in contact with sweat.

Although this material has short comings of having esthetic limitations, and slight hardening with time it provided economic rehabilitation to the patient, improving his quality of his life and reintegrating him back to society. Treatment, in this case was patient centered combined with bio adhesives provide a very conservative approach to fabricate a maxillofacial prosthesis. Placement of implant supported hader bar and clip attachments would have considerably improved the retention properties of the prosthesis.in case where implants cannot be indicated or where the patient opt to undergo surgical procedures, the above mentioned treatment process remains the most effective noninvasive treatment option.

Fabricating unilateral prosthesis remains a difficult task as compared to a bi lateral auricular prosthesis as this presents a similar comparison with a natural counterpart. Whenever feasible implant retained prosthesis should be given prime consideration, which has improved retention, stability and comfort of the patient.<sup>(7)</sup>

Recent advances in techniques, consisting a new generation of computed tomography scanner and three dimensional systems facilitate the production of mirror image of auricular prosthesis with a high level accuracy, alleviating most of the disadvantages of conventional prosthesis. Limitations to it use is high cost. Development in the field of tissue engineering has resulted in the formation of new tissue equivalents of bone and cartilage which will augment the result of prosthodontics rehabilitation in the future.<sup>(13)</sup>

## Conclusion

Maxillofacial defects are emotionally traumatizing and often cause a social stigma as a result of a distorted physical appearance. An attempt to provide a cost effective and cosmetically acceptable auricular prosthesis for male patient was made and it is

aesthetically and functionally acceptable to him. Successful use of prosthesis of might rely up on patient psychological acceptance and the patients participation in the decision making process with realistic expectations is of vital significance.

## References

1. Ozturk AN, Usumez A, Tosun Z. Implant-retained auricular prosthesis: a case report. *Eur J Dent* 2010;4:71-4.
2. Beumer J, Zlotolow I. Restoration of facial defects: etiology, disability, and rehabilitation. In: Beumer J, Curtis TA, Firtell DN(eds). *Maxillofacial rehabilitation: prosthodontic and surgical considerations*. St. Louis; C.V. Mosby; 1979. p. 328-40.
3. Van Doorne JM. Extra-oral prosthetics: past and present. *J Invest Surg* 1994;7:267-74.
4. Gumieiro EH, Dib LL, Jahn RS, Santos JF, Nannmark U, Granström G, Abrahão M. Bone-anchored titanium implants for auricular rehabilitation: case report and review of literature. *Sao Paulo Med J*. 2009; 127(3):160-5
5. Sahah DN, Chouhan CJ. auricular prosthesis: the overlooked skill in prosthodontics. *J of ahammed college and hospital* 2019;1(1):37-40.
6. Al Mardini M, Ercoli C, Graser GN. A technique to produce a mirror-image wax pattern of an ear using rapid prototyping technology. *J Prosthet Dent* 2005;94:195-8.
7. Singh A, Ghosh S, Sumana Kar, Ahmed I. Silicone prosthesis for a patient with unilateral ear defect: A clinical case report. *European Journal of General Dentistry* 2013;2(3):315-9.
8. Naveen BH, Kashinath KR, Shankargouda SB, Halappa M.A Blue Tooth – Auricular Prosthesis: A Case Report. *Journal of Clinical and Diagnostic Research*. 2014;8(8):36-8.
9. Sneha Shivkumar Mantri, MDS, Ram U. Thombre, MDS, Daigavane Pallavi. Prosthodontic rehabilitation of a patient with bilateral auricular deformity. *J Adv Prosthodont* 2011;3:101-5.
10. Goiato MC, Haddad MF, Sinhoreti MA, dos Santos DM, Pesqueira AA, Moreno A. Influence of opacifiers on dimensional stability and detail reproduction of maxillofacial silicone elastomer *Biomed Eng Online* 2010;9:85.
11. Kiat-amnuay S, Gettleman L, Khan Z, Goldsmith LJ. Effect of adhesive retention on maxillofacial prostheses. Part I: Skin dressings and solvent removers. *J Prosthet Dent* 2000;84:335-40.
12. Kumar PS, Satheesh Kumar KS, Savadi RC. Bilateral implant - retained auricular prosthesis for a patient with congenitally missing ears. A clinical report. *J Prosthodont*. 2012;21:322-27.
13. Rajyalakshmi R, Bheemalingeshwarrao, Suchita T, Kiran T. Auricular prosthesis-a case report. *Journal of Clinical and Diagnostic Research*. 2014;8(1):294-296.