

Full Mouth Rehabilitation: Conventional and the Contemporary

Pulkit Chandra^{1,*}, Nandeeshwar DB², Siddharth Mehta³, Sadhana Gupta⁴

¹Consultant Prosthodontist, Clone Dental, Jaipur, Rajasthan, ²HOD, ³Senior Lecturer, Dept. of Prosthodontics, Bapuji Dental College & Hospital, Davangere, Karnataka, ⁴Deputy Director, Dept. of Obstetrics & Gynecology, Zanana Hospital, Jaipur, Rajasthan

***Corresponding Author:**

Email: chandra.pulkit@gmail.com

Abstract

The concepts of traditional full mouth reconstruction have been used in the rehabilitation of a patient. A practical full mouth rehabilitation technique has been described combining the chairside advantages of the programmed reconstruction with the laboratory advantages associated with the complete mouth simultaneous rehabilitation. The particular case involved rehabilitation with fixed and removable prosthodontic therapy in accordance with the conventional and the contemporary prosthodontic treatment options and principles.

Keywords: Attachment, Cast partial denture, Fixed, Removable, Curve of spee.

Introduction

Satisfying patients' high expectations for dental esthetics is one of the challenges in contemporary dental therapy for both clinicians and dental technicians. As part of treatment planning, clinicians should be able to choose the appropriate restorative materials to achieve excellence in natural esthetics as well as proper biomechanics and durability.⁽¹⁾

The demand for treatment with different partial denture prostheses is increasing.⁽²⁾ Various treatment-planning modalities can be made for restorations in patients who have lost either upper or lower posterior teeth, unilaterally or bilaterally, and have no distal abutments. In modern dental practice many published paper suggested the application of implants in partially edentulous patients, serving as abutments for single crowns or fixed prostheses.^(3,4) Moreover, there is a paucity of studies concerning the combination of implants and removable partial dentures. However, in many partially edentulous situations the combination of implants and fixed restorations is difficult to implement.⁽⁵⁾ Contraindications can be based on medical, anatomical factors, such as the mandibular nerve or extension of the maxillary sinus, or costs involved with implant treatment. These Problems are mostly encountered in maxillary or mandibular posterior distal extension cases. The other problem occurs when the distal extension removable partial denture (RPD) is subjected to vertical, horizontal and torsional forces and that may become adverse during functional and para-functional activities. These forces, which can affect denture retention, stability and support, are often compensated for to some extent by framework and denture base design variations. However, both the methods initiate new complaint regarding the appearance of the dentition as element of the denture framework or acrylic resin becomes visible. Many patients are disappointed after placement of cast

removable partial dentures (RPDs) because the patient refuses or is unable to wear the denture and the treatment is, therefore, deemed unsuccessful. Rates of unsuccessful treatment for clasp retained cast RPDs range from 3% to 40% with mean being 26%.⁽⁶⁾ The compliance improves when the prosthesis meets the aesthetic requirements of the patient.⁽⁷⁾

Towards the end of the 19th century Parr, Peeso, Chayes, designed gadgets subsequently called precision attachments. These attachments allowed prostheses to combine the advantages of fixed and of removable restorations.⁽⁸⁾ An attachment is a precision connector made up of two parts one part is connected to a root, a tooth or an implant. The other part to an artificial prosthesis, and is used to provide mechanical connection between the two. For the most part attachments take the place of damaging clasp arm but can also be used to retain full or partial dentures on root anchors carrying studs and bars.⁽⁹⁾ Precision/Semiprecision RPD is the treatment modality that can facilitate both an aesthetic and a functional replacement of missing teeth and oral structures.

Acc. to Sherring and Martin indications of attachments are –

1. Fixed bridgework- Intracoronal attachment on non-parallel abutments
2. Partial Denture
3. Overdentures
4. Unilateral or bilateral free end denture.

Case Report

A 35 year old female, well built reported to the department of prosthodontics crown & bridge, Bapuji dental college and hospital, Davangere with a chief complain of difficulty in chewing food and an unpleasant smile due to multiple missing and attrited teeth. The patient was wearing treatment partial

dentures having complains of poor appearance, pain and looseness.

Clinical examinations

Extra-oral: The patient had no facial asymmetry, or muscle tenderness (Fig. 1 and Fig. 2). Mandibular range of motion was within normal limits. The temporomandibular joints, the muscles of mastication and facial expression were asymptomatic.

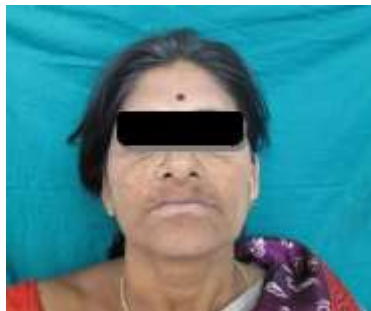

Fig. 1



Fig. 2

Intra-oral: The maxillary arch was partially dentate with 23,24,25 and 17 being present and the mandibular arch had 35,34,33,32,31,41,42,43,44 and 45 present. No gross abnormalities were detected in the overall soft tissue of the lips, cheeks, tongue, oral mucosa, and pharynx. Generalized attrition was noted. Amalgam restoration was noted on 23 and a GIC restoration on 17. (Fig. 3 and Fig. 4).

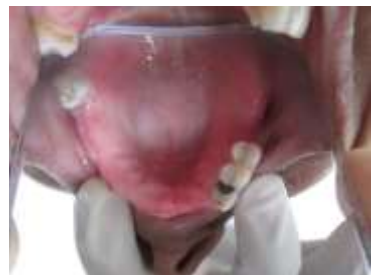

Fig. 3

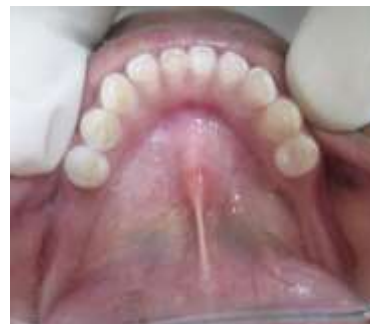

Fig. 4

Occlusal Findings: The patient did not have adequate centric stops except the occlusal contact between 24,25 and 34,35. The patient's vertical dimension was collapsed. The patient possessed a medium smile line. There was a discrepancy between the facial midline and mandibular midline of about 2mm to the right (Fig. 5).

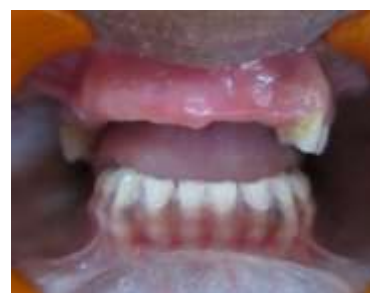

Fig. 5

Treatment goals

- To rehabilitate the entire severely worn out dentition in functional harmony with the stomatognathic system.
- Full coverage all ceramic crowns on mandibular incisors and canines.
- Full coverage metal ceramic crowns on mandibular premolars with Rhein 83 attachment.
- Attachment supported Cpd to restore the mandibular molar teeth.(due to medical reasons as the patient's hemoglobin level was below par 6gm/dl patient's fear of surgery, financial limitation and dissatisfaction from previous denture).
- Overdenture to rehabilitate the maxillary arch using 23, 24, 25 and 17 as abutments.
- Centric relation occlusion with maximum number of tooth contacts with a 2mm increase in the patient's vertical dimension.

Treatment procedure

1. The patient received oral prophylaxis, periodontal therapy, and oral hygiene instructions. Proper tooth brushing and flossing was re-emphasized, and the patient was called for reevaluation.
2. Root Canal therapy was carried out for 17, 23, 24, 25, 31, 32, 33, 41, 42 and 43.

3. Maxillary and mandibular impressions were made and diagnostic casts were obtained. Maxillary cast was mounted using a earpiece face bow (Hanau Springbow) onto a Hanau articulator and the mandibular cast was mounted using an inter-occlusal record, following which the bite was raised by 2 mm.
4. Anterior wax up was done to proper size, shape and contour. Mandibular posterior occlusal plane was analyzed after the anterior wax-up was approved esthetically and functionally (Fig. 6, Fig. 7 and Fig. 8). The maxillary posterior teeth were arranged into maximum inter-cuspalation. On analysis all the teeth followed the curve of spee.

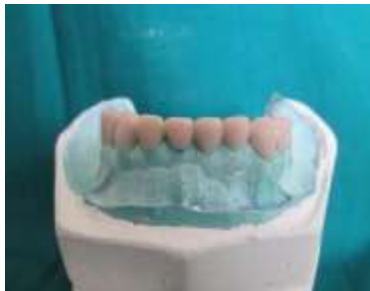

Fig. 6

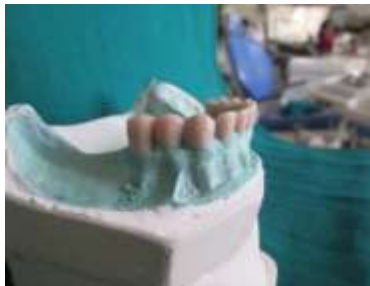

Fig. 7

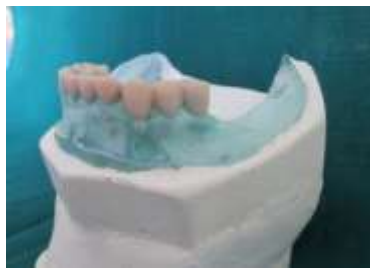

Fig. 8

5. A TPD was fabricated for the patient for confirmative diagnosis of loss of vertical and make the patient get used to the increased vertical dimension by the time the final prostheses are inserted to avoid any future TMJ problems (Fig. 9 and Fig. 10).

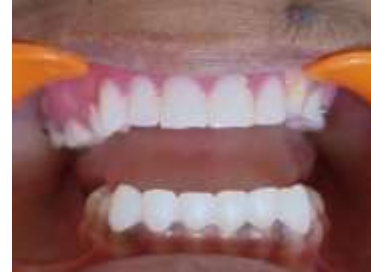

Fig. 9



Fig. 10

6. Clinical diagnostic tests were repeated to check the patient's comfort at the new vertical dimension. While the patient wore the provisional restorations for 3 months occlusal stability was checked.
7. Tooth preparation for full coverage metal ceramic and all ceramic crowns were completed for the mandibular dentition and the maxillary teeth were prepared to receive a metal coping to serve as overdenture abutments.
8. Final full arch impressions were made using polyvinyl siloxane (Aquasil Dentsply, Germany) with double mix impression technique (Fig 11 and Fig 12).

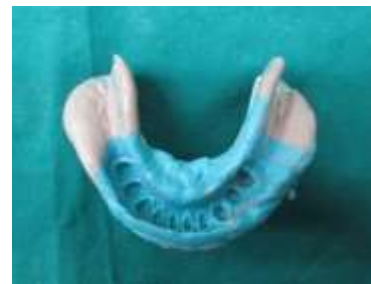

Fig. 11

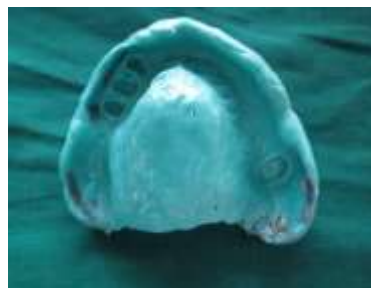


Fig. 12

9. The Casts were poured using die stone.
10. The upper and lower casts were mounted on a Hanau articulator using a facebow transfer and centric inter-occlusal record at the increased vertical dimension (Fig. 13).

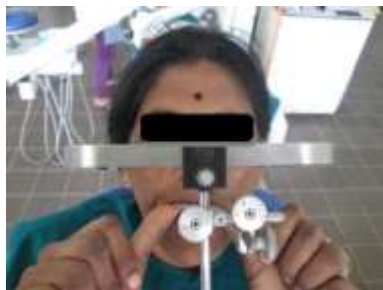

Fig. 13

11. When the patient was satisfied with the provisional restorations it was decided to reproduce the temporary vertical dimension and centric relation state on the final prosthesis.
12. The patterns were prepared for the PFM crowns and semi-precision attachments were attached to the two distal abutments on each side using a dental surveyor (Fig. 14).

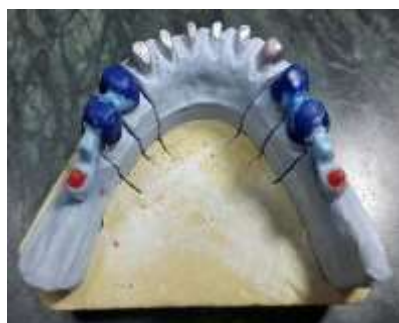

Fig. 14

13. For the fabrication of the metal copings for the maxillary abutment teeth direct patterns were made using pattern resin (Fig. 15).

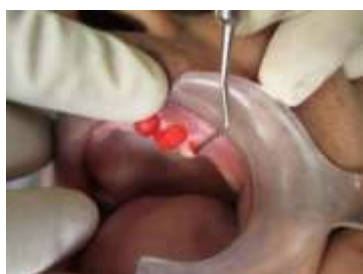

Fig. 15

14. Casting of all wax and pattern resin patterns were done followed by finishing, coping try-in and shade selection for ceramic (Fig. 16).

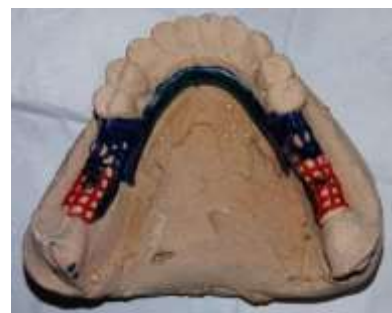

Fig. 16

15. Posterior teeth arrangement was also completed and evaluated (Fig. 17 and Fig. 18).

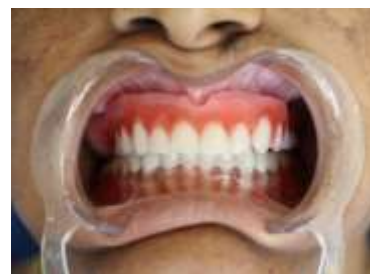

Fig. 17



Fig. 18

16. Finally, glazing of PFM and All-Ceramic Crowns and acrylization of attachment supported cpd and maxillary over-denture reinforced with a mesh were completed (Fig. 19).

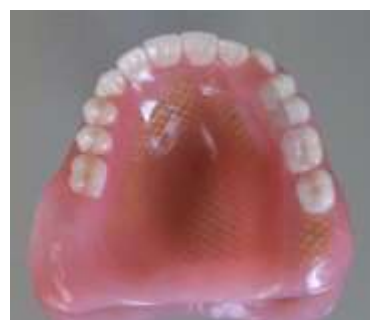

Fig. 19

17. Pink color rubber rings were placed (as manufacture's instruction) in the female counterpart slots present in the CPD using inserting

tool. These rubbers make the CPD retentive and stable and at the same time act as stress breakers (Fig. 20).

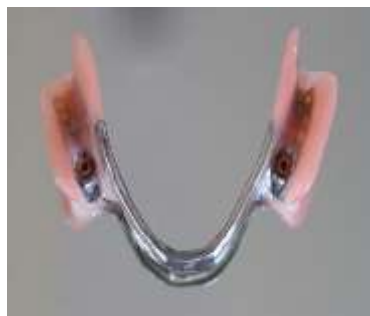

Fig. 20

18. All the crowns were cemented using appropriate cements and the Cpd along with the over-denture were inserted (Fig. 21).

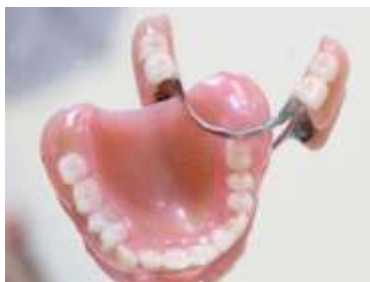

Fig. 21

19. After the treatment completion, routine check- ups were performed every 3 months.

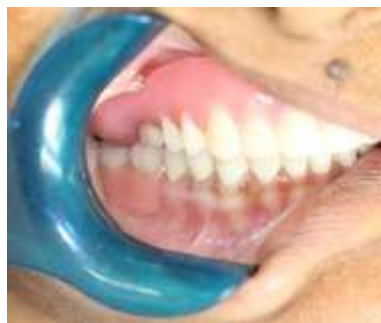

Fig. 22

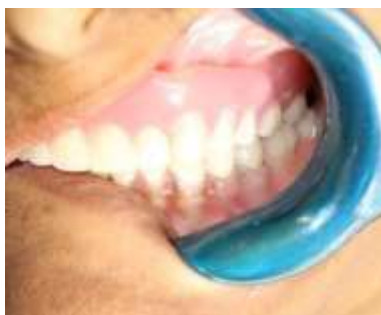

Fig. 23

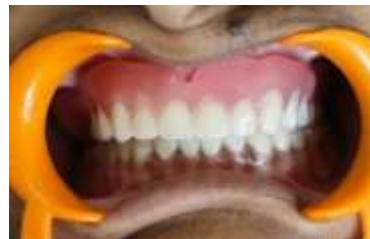

Fig. 24

20. The final treatment addressed the patient's chief complain with fixed crowns, cpd and an over-denture which produced a stable occlusion, improvement in function & aesthetics and a satisfied the patient(Fig. 25 and Fig. 26).



Fig. 25

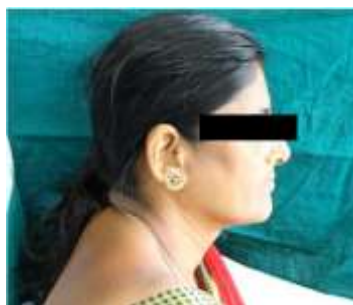

Fig. 26

Discussion

Removable partial dentures (RPD) have provided a viable treatment for partially edentulous patients. There are several treatment options for rehabilitation of partial edentulism including the use of conventional or implant-retained fixed prostheses. Depending on several given diagnostic factors and patient's perspective best treatment plan should be selected for the patient.

New technologies have dramatically improved the quality of removable partial denture and the quality of life of patients.

Precision attachments have been used in removable and fixed prosthetics for years and have contributed to the success of RPDs, overdentures, segmented fixed prosthetics, and implants. Removable partial dentures fabricated with precision/Semi precision attachments for retention and support are the best prosthesis

available to dentistry where fixed restorations are contraindicated.⁽¹⁰⁾

There are number of attachments available now. At the same time, attachments are being used in all manner of restorative procedures, from partial dentures to implant-based prostheses. No single attachment is perfect for every application, it is critical that the appropriate attachment be utilized for each individual case situation. By analyzing study models and x-rays, the clinician can make several important determinations, each of which will influence final attachment selection.

The survival rate of semi-precision attachment is quite satisfactory. Few retrospective studies available show a survival rate of 83.3% for 5 years, of 67.3% up to 15 years and of 50% when extrapolated to 20 years.^(11,12)

Use of all Silica/Glass based all ceramic crowns in combination with resin cements has the potential to provide a more aesthetic solution than conventional ceramo-metal crowns. In fact the concept of a silica/glass based dentin bonded crown has been discussed by Bruke et al as arguably an ideal restoration.⁽¹³⁾

However these material are extremely technique sensitive. They require additional marginal precision of the tooth preparation and they need to be bonded with resin cements, as such correct case selection, tooth preparation and bonding protocols are essential for long term success.

The concept of tooth supported complete denture permits the dentist to assume a significant role in preserving natural teeth and supporting structures including the ever so important alveolar bone.⁽¹⁴⁾

Conclusion

Appropriate case selection and careful treatment planning are critical to a successful outcome and patient satisfaction in multidisciplinary cases. The use of diagnostic elements and a preoperative treatment plan allows the clinician to identify areas of concern, allows the desired protocol for restoration. The restoration of normal healthy function of the masticating apparatus is the ultimate aim of full mouth rehabilitation.

References

1. Cortellini D, Canale A, Giordano A, et al. The combined use of all-ceramic and conventional metal-ceramic restorations in the rehabilitation of evere tooth wear. *Quintessence Dent Technol* 2005;28:205–14.
2. Douglass CW, Watson AJ. Future needs for fixed and removable partial dentures in the United States. *The Journal Prosthetic Dentistry*, 2002;87(1):9-14.
3. Ericsson I, Lekholm U, Branemark PI, Lindhe J, Glantz PO, Nyman S: A clinical evaluation of fixed-bridge restorations supported by combination of teeth and osseointegrated titanium implants. *Journal of Clinical Periodontology*, 1986;13(4):307-312.
4. Van Steenberghe D: A retrospective multicenter evaluation of the survival rate of osseointegrated fixtures

- supporting fixed partial prostheses in the treatment of partial edentulism. *The Journal Prosthetic Dentistry*,1989;61(2):217-223.
5. Battistuzzi PG, Van Slooten H, Kayser AF: Management of an anterior defect with a removable partial denture supported by implants. A case report. *The International Journal of Oral & Maxillofacial Implants*, 1992;7(1):112-115.
6. Frank RP, Milgrom P, Leroux BG, Hawkins NR: Treatment outcomes with mandibular removable partial dentures: A population-based study of patient satisfaction. *Journal of Prosthetic Dentistry*, 1998;80(1):36–45.
7. Mazurat NM, Mazurat RD: Discuss before fabricating: communicating the realities of partial denture therapy. Part I: Patient expectations. *Journal of Canadian Dental Association*, 2003;69(2):90–94.
8. Preiskel HW: Precision attachments for the partially dentate mouth. *Annals of the Royal College of Surgeons of England*, 1974;55(6):294-298.
9. Sherring LM, Martin P: Attachment for prosthetic dentistry introduction and application; In: *What is an Attachment*; Quintessence Publishing Co Ltd, London, 1994;pp.11-12.
10. Feinberg E, Feinberg EM: Attachment-retained partial dentures. *The New York State Dental Journal*, 1984;50(3):161-4.
11. Owl B: Precision attachment retained removable partial dentures: Part1. Technical long-term study. *The International Journal of Prosthodontics*, 1991;4(3):249-257.
12. Owl B: Precision attachment retained removable partial dentures: Part 2. long-term study of ball attachments. *International Journal of Prosthodontics*, 1995;8(1):21-28.
13. Burke FJ, Qualtrough AJ, Hale RW. The dentin bonded ceramic crown: an ideal restoration? *Br Dent J* 1995;179:58-63.
14. Robert M. Morrow, Earl E. Feldmann, Kenneth D. Rudd, Howard M. Trovillion. Tooth-supported complete dentures: An approach to preventive prosthodontics. *JPD vol 21 issue 5 may 1969 pg 513-522.*