

Interesting phenomenon of Concomitant Leiomyomas: Management issues in a two case miniseries

Gayathri KB^{1,*}, Sajana G², Sudha P³, Vimala Devi N⁴, Bhargav PRK⁵

¹Associate Professor, ²Professor & HOD, ³PG Student, Dept. of Obstetrics & Gynecology, ⁴Physician Assistant ⁵Consultant, Endocrine Surgery, Pinnamaneni Siddhartha Institute of Medical Sciences & Research Foundation, Vijayawada, Andhra Pradesh

***Corresponding Author:**

Email: endoanswers@gmail.com

Abstract

Vaginal fibroids with coincidental uterine fibroids are very occurrences in gynecological practice. They tend to pose management difficulties with regards to radiological, clinical and operative aspects. Here, we attempted to address those aspects in two case scenarios with mini review.

Keywords: Leiomyoma; Hysterectomy; MRI; Vaginal fibroid; Histopathology

Manuscript Received: 6th February, 2017

Manuscript Accept: 4th May, 2017

Introduction

Incidence of vaginal fibroid is 300 cases reported in literature.⁽¹⁾ Occurrence of vaginal fibroid is very rare. Most of vaginal fibroids occur in anterior vaginal wall, less common from posterior and lateral walls of vagina.^(2,3) Usually they are single, sometimes associated with leiomyomas elsewhere in the body. Ultrasonography is not very sensitive. MRI T1 & T2 weighted images show homogenous low signal intensity similar to myometrium, helps for preoperative characterization and to rule out urethral, bladder origin of tumour and to exclude secondary's. Surgical removal of tumour through vaginal approach after bladder catheterization with gentle dissection between fibroid and vaginal walls avoid bladder and urethral injuries.

Case Report

Case 1: A 40 year old female para 2 live 2 presented with complaint of swelling in the region of vagina which was gradually increasing in size which was more evident while walking and while performing her daily activities. She has regular menstrual cycles. On per vaginal examination, a firm mass of 4x4cm size is felt on the anterior wall of vagina, uterus was of normal size, retroverted with free fornices. On ultrasound, bulky uterus with subserosal fibroid and normal adnexae were visualised. MRI was done which showed large anterior fundal intramural or subserosal fibroid on left side and large T2W hypointense lesion seen protruding from lower vagina – can be pedunculated cervical fibroid/ vaginal leiomyoma/ fibrovascular polyp.

Consent was taken for the surgery and the tumour was surgically removed by vaginal route and non-descent vaginal hysterectomy was done. The tumour was enucleated by blunt dissection after catheterisation which was 4x4cm size and sent for histopathology. Surgery was uneventful. Postoperative recovery was

good and patient was discharged on 5th post operative day.

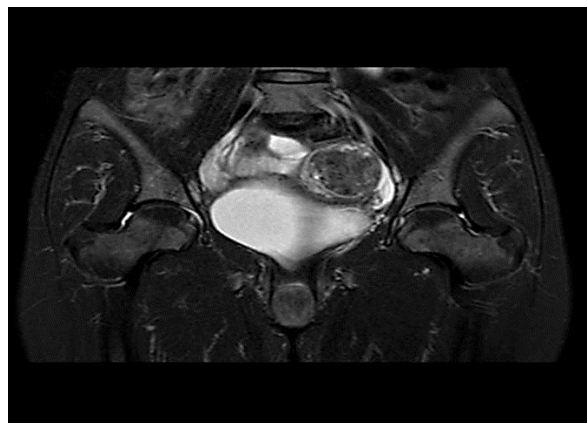

Fig. 1: MRI image showing the uterine leiomyoma with well preserved peri-tumoral planes

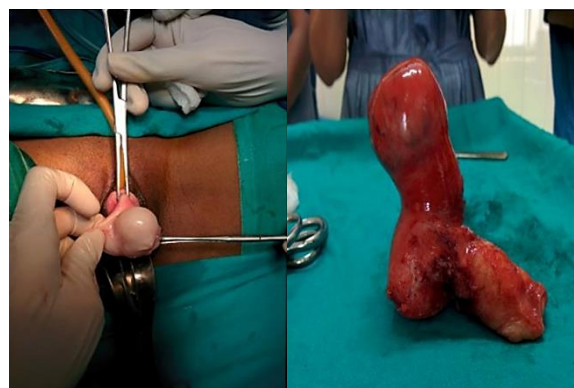


Fig. 2: Operative images – Left one shows in vivo vaginal fibroid; right one shows exvivo specimen with dual leiomyomas

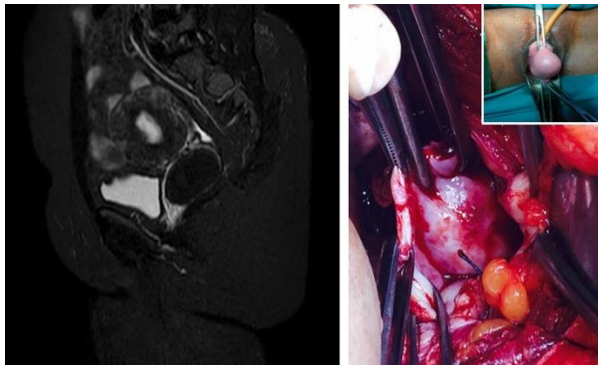


Fig. 3: Left image shows MRI images of second case; right panel shows operative image of uterine leiomyoma trans-abdominally (inset shows vaginal counterpart)

Case 2: A 42 year old para 2 live 2 presented with complaint of pain lower abdomen since 3 months with irregular menstrual cycles. She had no other significant history. On per vaginal examination, a 4x2 cm size firm mass was felt in the lateral wall of vagina totally separate from cervix. Uterus was bulky in size with hard indurated mass in left lateral fornix and right fornix free. On evaluation showed heterogenous benign left adnexal mass on ultrasound. MRI investigation showed a well defined mass in the left lateral aspect of cervix – possible vaginal or broad ligament fibroid. Preoperative evaluation were within normal limits. Consent was taken. Total abdominal hysterectomy was done. 3x4 cm mass was identified arising from posterior and left lateral vaginal wall. The mass was enucleated and sent for HPE.

Discussion

Vaginal fibroids are usually asymptomatic but can present with variable symptoms depends on site and size, varying from dyspareunia, urinary retention, lower abdomen pain, low back pain.⁽³⁾ Leiomyomas in female genital tract are common in the uterus and to some extent in the cervix followed by the round ligament, utero-sacral ligament, ovary, and inguinal canal. Occurrence in vagina is very rare. Vaginal leiomyomas are commonly seen in the age group of 35 to 50 years. They are more common among Caucasian women. There is no correlation existing between vaginal and uterine leiomyoma.⁽⁴⁾

Immunohistochemistry studies on the smooth muscle action were analysed in 26 patients by Zhao Yet al. showed increased expression of ER and EGFR. They concluded that estrogen hormone & EGF (Epidermal growth factor) play an important role in development & growth of leiomyoma of vagina.⁽⁵⁾

Histopathology is the gold standard and confirms diagnosis and to rule out any possible focus of malignancy. Surgery is the treatment of choice and the approach is usually vaginal. However in cases of large tumours, abdominoperineal approach can be done.

Caution has to be taken to prevent bladder injuries while dissection. Postoperatively, methylene blue dye test is done to know the intactness of the bladder. The patient needs to be followed up for chance of recurrence.

Competing interests

The author(s) declare that they have no competing interests

Author contributions

Authors Gayathri, Sajana, Sudha have made substantial contributions to conception and design, or acquisition of data, or analysis and interpretation of data

All authors have been involved in drafting the manuscript or revising it critically for important intellectual content

References

1. Young SB, Rose PG, Reuter KL. Vaginal fibromyomata. Two cases of preoperative assessment, resection, reconstruction obstet. Gynaecol (1991) 78, 972-974.
2. Bennett HG, Ehrlich MM. Myoma and vagina. *Amm J ObstGyn* (1941) 42, 314-20.
3. Sherer DM, Cheung W, Gorelick C, Lee Y, Serur E, Zinn HL, et al. Sonographic and Magnetic Resonance Imaging findings of an isolated Vaginal Leiomyoma. *J Ultrasound Med* (2007), 26 1453-6.
4. Lee SM, Shin HG, Kim HS, Kang V, Cho TI. A case of Uterine and vaginal fibroid. *Korean Journal Obs Gynaecol* (2001) 44, 830-832.
5. Zhao Y, Li Y, Xu Y. Clinico-pathologic analysis of 26 cases of leiomyoma of the vagina. *Beijing Da Xue Xue Bao* (2003) 35, 37-40.