

Estimation of neck shaft angle of dry radii for prosthetic replacement

Anjali Shastry^{1,*}, Yogitha Ravindranath², Roopa Ravindranath³

¹Tutor, ^{2,3}Professor, Dept. of Anatomy, St. John's Medical College, Bangalore

***Corresponding Author:**

Email: anju_shas@yahoo.com

Abstract

Introduction: Radial head prosthesis is a valuable option in patients with radial head and neck fractures who require radial head replacement. Neck shaft angle (NSA) is an important morphometric measurement for stem design of radial head prosthesis in head and neck fractures to enable adequate movements of forearm following post operative management.

Aims and Objectives: a) To estimate neck shaft angle of proximal end of right and left radii.

b) To compare neck shaft angle of proximal end of right and left radii.

Materials and Method: Digital photographs of posterior surface of all 142(71 left & 71 right) radii were taken. Lines were drawn using Microsoft power point software. Image was saved as a picture and opened with Image J analyser which measured neck shaft angle. Statistical analysis was done using SPSS.

Results: The mean neck shaft angle was $168.01 \pm 3.65^\circ$. Right side was $165.67 \pm 4.44^\circ$ and left side was $168.01 \pm 3.65^\circ$. There was significant difference between left and right side values of neck shaft angle.

Conclusion: Mean values of neck shaft angle were comparable with previous studies. Side difference should be considered while implanting prosthesis on affected side.

Keywords: Proximal radii, Radial head prosthesis, Neck shaft angle, Radial head fractures

Received: 27th April, 2017

Accepted: 24th June, 2017

Introduction

Radial head and neck fractures represent approximately 1.7% to 5.4% of all fractures.⁽¹⁾ Radial head fractures account for approximately one third of all elbow fractures and are involved in approximately 20% of elbow trauma cases.⁽²⁾ Surgical options include radial head resection with or without prosthetic replacement with less severe injuries to be treated by internal fixation.⁽³⁻⁵⁾ Neck shaft angle (NSA) is angle made by neck with shaft/diaphysis of radius bone. It indicates amount of bending of shaft with respect to proximal radius which in turn determines wrist biomechanics. It limits movements at proximal radioulnar joint during pronation and supination. Various authors have described neck shaft angle for radius but mostly in western population.⁽⁶⁻⁸⁾ To avail maximum angle of movements in radio capitular joint surface a clear idea of shaft to neck angle is necessary. Furthermore prosthesis that are available today are fixed stem to neck angle which warrants for proper alignment of radial head to its shaft through bending in neck.⁽⁶⁾ Proper fixation will also reduce postoperative complications along with adequate rehabilitation to routine activities of patients as well as to his occupation.

The purpose of the present study was to measure neck shaft angle with regard to stem replacement of radial head prosthesis. Paucity of Indian data was another reason for this particular study.

Materials and Method

142 adult dry cadaveric radii (71 right and 71 left) were selected from the collection of bones from department of Anatomy, St John's Medical College, Bangalore. Healthy radii with no obvious damage were chosen for study.

Sample size was calculated using N Master software. Mean and standard deviation values of neck shaft angle from previous literature was entered in N master software which gave appropriate sample size.

Digital photographs of posterior surface of all 142(71 left & 71 right) radii were taken. Angle was measured using Image J analyser. The radii were placed on osteometric board in such a way that its posterior surface was pointing upwards. A digital camera was fixed to stand of osteometric board for proper focus and centered along with bone on the board.



Fig. 1: Method of taking photo for neck shaft angle

Image Analysis:

Using Microsoft Power Point the following lines were drawn

- First line (AB) drawn along proximal neck of radius.
- Second line (CD) drawn along distal neck of radius.
- Third line (EF) drawn along shaft of radius 8cm from head of radius.
- Fourth line drawn from midpoint of AB to midpoint of CD.
- Fifth line drawn from midpoint of CD to midpoint of EF.
- This image was saved as a picture and opened with **Image J** analyser.
- The angle between the fourth and fifth line gave the neck shaft angle.

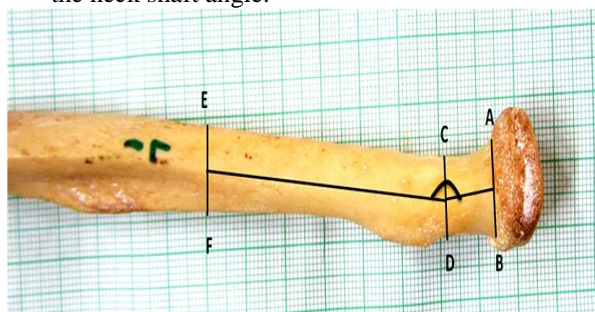


Fig. 2: Method of drawing lines using Microsoft Power Point

Statistics: Statistical analysis was done using SPSS.

Results

The mean neck shaft angle was $168.01 \pm 3.65^\circ$. Right side was $165.67 \pm 4.44^\circ$ and left side was $168.01 \pm 3.65^\circ$. Neck shaft angle was more on left side than right side. There was significant difference between left and right side values of neck shaft angle ($p < 0.05$). Test of significance used was independent sample T test.

Table 1: Mean values of Neck shaft angle

	Right side Mean \pm SD($^\circ$)	Left side Mean \pm SD($^\circ$)	p value
1.	165.67 ± 4.44	168.01 ± 3.65	0.001*

Table 2: Comparison of neck shaft angle with previous studies

Author	Methodology	Sample size	Neck shaft angle ($^\circ$)
Koslowsky (2007)	X Rays	40	167.8
Van riet (2004)	cadavers	27	163
Captier (2002)	Dry bone	96	168
Paul Puchwein (2013)	CT	30	160
Present study	Dry bone Computer assisted	142	166.84

Discussion

In study done by Koslowsky et al., on radii by studying X ray imprints mean neck shaft angle was 167.8° .⁽⁶⁾ This value is comparable with our study showing that neck shaft angle did not vary much between methodologies i.e., between manual method and digital images.

In the study done by Captier et al., the angle between the neck and the diaphysis varied with regard to the shape of the radial head. It was 166.75 ± 3 for the circular heads and 168.62 ± 3.2 for the elliptical heads ($P < 0.01$).⁽⁷⁾ They concluded that biomechanics of the circular shape and the elliptical shape are different, involving an adaptation of the angle between the neck and the radial diaphysis.

Paul Puchwein et al., did computed tomography scans of 30 cadaveric elbows and 3-dimensional reconstructions were used to analyze the morphometry of the proximal radius.⁽⁸⁾ The mean neck shaft angle was 160° (153° - 165°) which was comparable with our study. This shows that there is no significant difference between measurements done on dry bone and CT scans which in turn implies that measurements done on CT scan can be used for prosthetic reconstruction.

Most of the previous studies had values similar to the present study which showed that there was not much difference between values of neck shaft angle when ethnicity was concerned. There was significant side difference in values of neck shaft angle which can be attributed to handedness of individual which was not considered here. Due to probable excessive wear and tear during movements of elbow, right side had lesser angle when compared to left side. Further it would be appropriate to consider occupational factors while deciding implantation of prosthesis.

Limitation of this study is that the study was done on dry bones as values cannot be directly measured on live radii. Moreover it would be worthwhile measuring neck shaft angle in all possible movements of elbow for proper design of stem of radial prosthesis.

Conclusion

Mean values of neck shaft angle were comparable with previous studies. Side difference should be considered while implanting prosthesis on affected side.

Acknowledgements

We thank teaching and non teaching staffs of Department of Anatomy.

References

1. Morrey BF. Radial head fracture .The elbow and its disorders. 2nd ed. Philadelphia: WB Saunders, 1993:383-404.
2. Mason ML. Some observations on fractures of the head of the radius with a review of one hundred cases. Br J Surg. 1954;42:123-132.
3. Swanson AB, Jaeger SH, La Rochelle D. Comminuted fractures of the radial head: the role of silicone-implant

- replacement arthroplasty. *J Bone Joint Surg.* 1981;63A:1039-1049.
4. Cherry JC. Use of acrylic prosthesis in the treatment of fracture of the head of the radius. *J Bone Joint Surg.* 1953;35B:70-71.
 5. Knight DJ, Rymaszewski LA, Amis AA, Miller JH. Primary replacement of the fractured radial head with a metal prosthesis. *J Bone Joint Surg.* 1993;75B:572-576.
 6. Koslowsky TC, Beyer F, Germund I, Mader K, Jergas M, Koebk J. Morphometric parameters of the radial neck: an anatomical study. *Surg Radiol Anat.* 2007 Jun;29(4):279-84.
 7. Captier G, Canovas F, Mercier N, Thomas E, Bonnel F. Biometry of the radial head: biomechanical implications in pronation and supination. *Surg Radiol Anat.* 2002 Dec;24(5):295-301.
 8. Puchwein P, Heidari N, Dorr K, Struger L, Pichler W. Computer-aided analysis of radial head morphometry. *Orthopedics.* 2013 Jan;36(1):e51-7.