

## A study of the histological and morphometric changes in jejunum of albino rats after administration of Indomethacin

Vinay Kumar<sup>1,\*</sup>, Manisha Gupta<sup>2</sup>

<sup>1</sup>Associate Professor, Dept. of Anatomy, <sup>2</sup>Professor & HOD, Dept. of Physiology, Saraswathi Institute of Medical Sciences, Hapur, Uttar Pradesh

**\*Corresponding Author:**

Email: drsinghal2009@rediffmail.com

### Abstract

Indomethacin is developed as anti-inflammatory agent and introduced for the treatment of arthritis mainly rheumatoid arthritis in 1960s. The gastrointestinal tract is main target of NSAIDs toxicity. Indomethacin is the commonest of NSAIDs used by people. World over 35 million people consume this drugs daily. Indomethacin is a synthetic non-steroidal anti-inflammatory drug. The Indomethacin decreased the production of prostaglandins that sensitizes nociceptors to inflammatory mediators such as bradykinin and 5-hydroxytryptamin. This study was done in the Department of Anatomy, Himalayan Institute of Medical Sciences, Swami Ram Nagar, Dehradun over a period of 1 year. Albino rats of strain Charles Foster 16 (08males and 08 females) weighing 120gms (+10gms) obtained from the Central Animal House, HIMS, Dehradun (Uttarakhand) were used as experimental animals after obtaining the approval of IAEC. The rats were randomly divided into 4 groups, Group I, II and III and IV for the study. Each group was comprised of 04 rats out of which group I was taken as control and the remaining three groups were taken as the experimental groups. Each experimental group was subjected to oral administration of Indomethacin for 1 week, 2 weeks & 3 weeks respectively. The experimental and control groups were sacrificed at the end of 1st, 2nd and 3rd week intervals after giving ether anesthesia. They were immediately fixed on a wooden block with the help of paper pins. Dissection was done to open the abdomen for gross observations. Jejunum preserved in neutral buffered formalin. Staining was done with Harris' Hematoxylin and Eosin. 3-5 µm thick paraffin sections were studied under light microscope and the histological changes was studied. The histological changes seen as decrease in the height of villi, Increased in cells -goblets, columnar, mitotic number per crypt were observed.

**Keywords:** GIT, NSAIDS, ALBINORATS, Hematoxylin and Eosin Institutional Animal Ethical Committee (IAEC)

**Received:** 5<sup>th</sup> November, 2016 **Accepted:** 7<sup>th</sup> February, 2017

### Introduction

The gastrointestinal tract (GIT) is the main target of NSAIDs toxicity. It is the most common drug-induced toxicity that can be fatal. World over 35 million people consume these drugs on a daily basis. Conservative calculation estimates that approximately 1 lakh patients are hospitalized annually for non-steroidal anti-inflammatory (NSAIDs) related gastrointestinal complications, and about 16,500 deaths occur every year due to NSAIDs related complications. It has also been estimated that 1/3 of the cost, treating arthritis patients related to treatment are due to the side effects of Non steroidal anti-inflammatory drugs. According to prospective data from Arthritis Rheumatism, & Ageing Medical Information System (ARAMIS), 13 of every 1,000 patients with rheumatoid arthritis who take NSAIDs for one year have a serious problems related to gastrointestinal tract. Non steroidal anti-inflammatory drugs (NSAIDs) are among the most widely used of all therapeutic drug. They are frequently prescribed for 'rheumatic' musculoskeletal complaints and are often taken without prescription for minor aches and pains. There are now more than 50 different NSAIDs on the market and none of these is ideal in controlling or modifying the signs and symptoms of inflammation in

toto, particularly in the common inflammatory joint disease.<sup>(1)</sup>

Indomethacin is a synthetic non-steroidal anti-inflammatory drug with analgesic and antipyretic effect. Indomethacin is a potent inhibitor of prostaglandin synthesis. The analgesic action of Indomethacin is due to decrease in the production of prostaglandins that sensitizes nociceptors to inflammatory mediators such as bradykinin and 5-hydroxytryptamine. Indomethacin is readily absorbed from the gastrointestinal tract after oral ingestion. 90% of the drug is bound to tissue proteins and are also the mediators of inflammatory response. Indomethacin is used in musculoskeletal disorders such as rheumatoid lesions. Indomethacin is widely used in the treatment of (osteoarthritis and acute gouty arthritis) and ankylosing spondylitis. The oral dose of Indomethacin is 25–50 mg 2-3 times a day. The side effects of Indomethacin especially on the gastrointestinal tract are due to its systemic effects and not due to its local effect. Ingestion of Indomethacin has been shown, in man, to be associated with NSAID gastropathy. The side effects of drug are nausea, vomiting, anorexia, epigastric distress, diarrhoea, gastrointestinal ulcers and perforation. The Indomethacin is still widely used in the remote areas because of its low price.<sup>(2-4)</sup>

This study was carried out in the Department of Anatomy, Himalayan Institute of Medical Sciences,

Swami Ram Nagar, Dehradun over a period of twelve months.

In this study 16 adult Albino rats of Charles Foster strain (08males and 08 females) weighing 120gms ( $\pm 10$ gms) obtained from the Central Animal House, HIMS, Dehradun (Uttarakhand) were used as experimental animals after obtaining the approval of IAEC (Institutional Animal Ethical Committee). The rats were housed in cages with a 12hr light-dark cycle. The rats were randomly divided into 4 groups i.e. Group I, II and III and IV for the study. Each group was comprised of 04 rats out of which group I was taken as control and the remaining three groups were taken as the experimental groups. Each experimental group was subjected to oral administration of Indomethacin. They were fed with rat-feeding tube. The drugs were administered for 1, 2 and 3 weeks in experimental groups respectively.

Indomethacin (Cap 25mg) was dissolved in 10 ml of distilled water, to get the concentration of indomethacin 2.5 mg/ml. Indomethacin was given orally twice daily in a dose of 10 mg / kg body weight /day at the interval of 12 hours to the experimental groups. The controls were administered distilled water according to weight.

The rats of experimental groups were sacrificed at the end of 1<sup>st</sup>, 2<sup>nd</sup> and 3<sup>rd</sup> week intervals after giving ether anesthesia. They were immediately fixed on a wooden block with the help of paper pins. Dissection was done to open the abdomen for gross observations. The rats were infused with normal saline to wash out the blood. Jejunum preserved in neutral buffered formalin. Staining was done with Harris' Hematoxylin and Eosin. 3-5  $\mu$ m thick paraffin sections of jejunum were studied under light microscope and the histological and morphometric changes was studied.

### Observation and Results

Microscopic examination was done under 100X and 400X magnification of the control and experimental groups on the sections prepared from jejunum. 10 randomly selected areas were taken from each control and experimental groups to study any particular aspects, the mean and standard deviation were calculated. The measurements were done with the help of an eyepiece containing micrometer. Features such as epithelial erosion, ulceration, inflammatory cells and necrosis were noted. All numerical data were subjected to students T-test before deriving final result.

#### Mean height of villi, number of goblet cell, columnar cells, and mitotic figure per crypt per high power field in the jejunum after administration of indomethacin

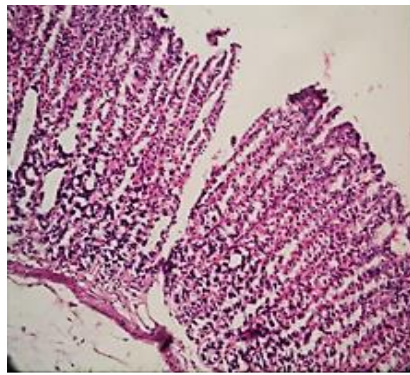
	Control Group (Mean $\pm$ SD)	Experimental Group (Mean $\pm$ SD)		
		1 <sup>st</sup> week	2 <sup>nd</sup> week	3 <sup>rd</sup> week
Height of villi ( $\mu$ ) p value	104 $\pm$ 17.6	84.2 $\pm$ 4.9 p< 0.01 (HS)	73.9 $\pm$ 12.1 p< 0.01(HS)	65.2 $\pm$ 17.6 p<0.01(HS)
No. of goblet cells/ crypt/ HPF p value	6.7 $\pm$ 0.9	11.3 $\pm$ 1.6 p<0.01(HS)	6.1 $\pm$ 1.1 p< 0.05(S)	4.6 $\pm$ 0.9 p<0.05(S)
Number of columnar cells/ crypt/ HPF p value	38.1 $\pm$ 3.3	41.6 $\pm$ 2.5 p< 0.01(HS)	38.6 $\pm$ 1.7 p< 0.01(HS)	44 $\pm$ 3.8 p<0.01(HS)
Number of mitotic figure/ Crypt/HPF p value	4.0 $\pm$ 0.9	5.8 $\pm$ 0.7 p> 0.05(NS)	4.8 $\pm$ 0.7 p< 0.05(S)	5.0 $\pm$ 0.6 p<0.05(S)

p< 0.01 – Highly Significant

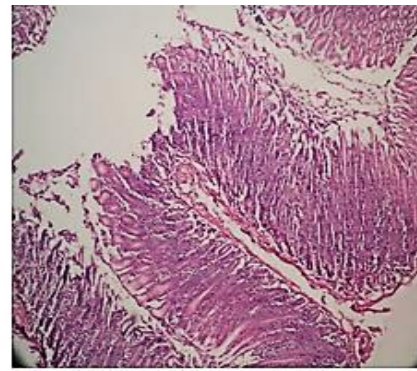
p< 0.05 – Significant

p> 0.05 – Not significant

Most of the villi in the jejunum were tongue-shaped, intact and upright but distorted. The mucosa was congested with hyperaemia. There was nuclear degeneration. The villi were oedematous and an increase in intervillous spaces was noted. Mononuclear cell infiltration in lamina propria was observed. A decrease in the height of villi was noted in all the experimental groups. The height of the villi which was 104  $\pm$  17.6  $\mu$  in control group, decreased to 84.2  $\pm$  4.9  $\mu$ , 73.9  $\pm$  12.1  $\mu$ , 65.2  $\pm$  17.6  $\mu$  at the end of the 1,2 and 3 weeks respectively. The p values were significant in all the experimental groups. The number of the goblet cells was 6.7  $\pm$  0.9 in the control group. It increased to 11.3  $\pm$  1.6 at the end of 1<sup>st</sup> week. However, it decreased to 6.1 $\pm$ 1.1 and 4.6 $\pm$ 0.9 at the end of the 2<sup>nd</sup> and 3<sup>rd</sup> weeks respectively. The p values were significant in all the treated groups. We observed that the number of columnar cells which were 8.1  $\pm$  3.3 in the control group, increased to 1.6  $\pm$  2.5, 38.6  $\pm$  1.7, 44  $\pm$  3.8 at the end of the 1, 2, and 3, weeks respectively. The p values were significant in all the treated groups. It was noted that the mean number of mitotic figures in the control group was 4.0  $\pm$  0.9. It increased to 5.8  $\pm$  0.7, 4.8  $\pm$  0.7, 5  $\pm$  0.6 at the end of the 1<sup>st</sup>, 2<sup>nd</sup> and 3<sup>rd</sup> weeks respectively. The p values were significant in all the treated groups.



Control



experimental

### Discussion

Demetre M studied the pathological changes of Indomethacin in adult mongrel dogs each weighing about 10-12 kg, after oral administration of the drug in a dosage of 5 mg/kg of body weight for 30 days. He observed melaena in the 1st week of administration. Antral ulcerations were noted in all cases. Superficial ulcers were observed in stomach {body and fundus}.<sup>(5)</sup> Ettarh RR et al observed the morphometric analysis of the small intestinal epithelium in mice after intraperitoneal injection of Indomethacin in a dose of 85 mg/kg of body weight. After 20 hours of administration there was an increase in the number of columnar cells. There was also an increase in the number of goblet cells but the number of columnar cells/villus showed a decline in all parts of jejunum. Mitotic figures, however, showed a very slight increase in the jejunum.<sup>(6)</sup> Satoh H et al studied the effects of subcutaneous injection of Indomethacin in male JcL: Sprague-Dawley rats weighing about 180-220 gm in doses of 30 mg/kg of body weight. The experimental animals were divided into three groups. The first group which was sacrificed 6 hours after administration of the drug showed antral lesions, in which the outer half of mucosa had sloughed with evidence of damage in the inner half of mucosa with pyknosis and cytoplasmic shrinkage of parietal and chief cells. Mononuclear cells infiltrations were seen in the base of the lesion and the adjacent mucosa. The second group which was sacrificed 24 hours after administration of the drug depicted necrotic lesions involving muscularis mucosae in the same area while the submucosa was oedematous and infiltrated with inflammatory cells. The third group (3 days post administration) showed disappearance of the mucosal layer with destruction of the muscularis mucosa.<sup>(7)</sup> Brodie DA et al studied the effects of Indomethacin in rats after oral administration of the Indomethacin in a dose of 16 mg/kg of the body weight. They divided the rats into two groups. The first group which was sacrificed 24 hours after a single dose administration showed small white nodules palpable from the serosal surface of the small intestine. Microscopically, the lesions showed perforating ulcers

surrounded by oedema with infiltration of polymorphonuclear cells extending up to the serosa and mesentery. Non-perforating ulcers were both of discrete and coalescing varieties found along the mesenteric border of the small intestine. The second group sacrificed after 3 days of oral administration of Indomethacin revealed perforated ulcers in the small intestine.<sup>(8)</sup> Kent TH et al studied small intestinal ulcers in rats after administration of Indomethacin in single doses of 5, 10, 20, 30, 40 mg/kg of body weight intragastrically dissolved in 2 ml. of saline. Only one of the 3 rats which received 5mg/kg of body weight dose had small ulcers in the small intestine but all the animals belonging to 10 mg/kg of the body weight groups had patchy small ulcers in the distal half of the small intestine. Severe forms of ulceration were found in those animals receiving 20 mg and 40 mg/kg of body weight of Indomethacin. The ulcers ranged from a few millimetres to many centimetres in length & averaged 4 mm in width; the ulcers were localized to the mesenteric border of small intestine with absence of mucosa, accompanied with partial to complete necrosis of muscularis mucosae.<sup>(9)</sup> Nygard G et al studied Indomethacin – induced jejunal injuries in rats. The rats were administered with a single dose Indomethacin 15 mg/kg of body weight and were sacrificed at 1, 2, 3, 6 and 48 hours after administration of the drug. They observed focal deposition of fibrinogen/fibrin at the tip of villi at the end of 2 hours, by 3 and 6 hours. The extent of both intravascular and extra vascular fibrin deposition were increased. In the 48 hours experimental group prominent intravascular thrombi and extracellular fibrin were seen in both ulcerated and non ulcerated areas of the mucosa. A statistically significant neutrophil infiltration of the intestine did not occur until 6 hours after dosing. Between 6 and 48 hours, the neutrophil infiltration increased and was associated later with frank ulceration. However, macrophage infiltration at areas of ulceration extending into the mucosa, submucosa and muscular layers occurred at a relatively advanced stage of inflammation (48 hours).<sup>(10)</sup> Ilahi M et al studied the histological changes in parts of foregut of albino rats of Charles Wistar

Strain weighing 250.8– 256.6 gm. The rats were administered with Indomethacin intraperitoneally in a dose of 1mg/kg of body weight/day in two divided doses. The experimental animals were sacrificed at the end of 1, 2 and 3 weeks respectively. The body of the stomach showed normal architecture at the end of the first week while the pylorus of the stomach showed superficial ulcers which were flat with irregular margins and extended upto the muscularis mucosae. Inflammatory cells were present in the deeper parts of the ulcer which extended up to the submucosa. Haemorrhage or perforations were not observed. At second week the pylorus showed flat or punched out ulcers. Granulation tissue was also observed indicating an ongoing healing process. At the end of 3 weeks the body of the stomach was normal while the pylorus depicted sites of superficial focal necrosis only. The duodenal mucosa showed a decrease in the height of the villi at the end of the first week. However, a rise in the number of columnar cells, goblets cells and mitotic figures in the crypts were also noted. At the end of 2nd and 3rd weeks the duodenum had a normal architecture and did not show any significant histological changes.<sup>(11)</sup>

### Conclusion

The histological changes seen as decreased in the height of villi, Increased in the numbers of goblets cells, Increased in the number of columnar cells, Increased in the number of mitotic figures are due to as NSAIDs are weak organic acids, therefore, they remain unionized in stomach and are absorbed appreciably from stomach. However, once they breach the membrane of stomach cell and reach within, they encounter a basic medium. This causes “trapping” of drugs inside the cell. This topical effect is considered an important mechanism of gastro intestinal injury. The injuries to gastrointestinal tract are believed to occur as a result of a complex interplay of aggravating and protective mechanism. Prostaglandins (PGs) have long been known to be mucoprotective & act as ulcer healing. PGs protect the gastrointestinal mucosa by forming a cytoprotective layer and by increasing the secretion of bicarbonate ions which neutralizes the acid produce by stomach. All non steroidal anti-inflammatory drugs act by inhibiting the synthesis of Prostaglandins. Cyclooxygenase has two isoforms, one constitutive (COX-1) and another inducible (COX-2). A third isoform (COX-3) has recently been described, Indomethacin is a potent non-selective COX inhibitor, which leads to reduction in bicarbonate secretion & reduces mucous production. It is coupled with vasoconstriction, which causes hypoxia and consequent injury to epithelium leading to ulcer formation.<sup>(12)</sup>

### References

1. SC. Monograph on drugs and ancillary substance. In: Martindale. 33<sup>rd</sup>. London Pharma 2002.

2. Robbin SL, Kumar V, Ramzi C. Acute and Chronic Inflammation. In: Basic Pathology. 7<sup>th</sup> ed. Philadelphia: WB Company; 2003.
3. Laurence DR, Bennett PN. Inflammation and Nonsteroidal anti-inflammatory drugs. In: Clinical Pharmacology. 6<sup>th</sup> ed. UK: Churchill Livingstone; 1988.
4. Dennis and McNamara. Non- opiate Analgesic and anti-inflammatory drugs. In: Principles of Pharmacology. 1<sup>st</sup> ed. USA: Chapman and Hall; 1995.
5. Demetre M. Nicoloff, MD, PhD, Minneapolis. Effect on gastric secretion, parietal cell population and ulcer provocation in the dog. Arch Surg 1968;97:809–815.
6. Ettarh R.R. and Carr K.E. Morphometric analysis of the small intestinal epithelium in the Indomethacin treated mouse. J. Anat 1996;189;51–56.
7. Satoh H, Inada I, Hirata T, Maki Y. Indomethacin produces gastric antral ulcers in the refed rat. Gastroenterology 1981;81:719-25.
8. Brodie DA, Cook PG, Bauer BG and Dagle GE. Indomethacin-induced intestinal lesions in the rat. Toxicology and applied pharmacology. 1970;17:615-624.
9. Kent TH, Cardelli RM, Stamler FW. Small intestinal ulcers and intestinal flora in rats given Indomethacin. Am J Pathol 1969;54(2):237–249.
10. Nygard G, Anthony A, Piasecki C, Trevethick MA, Hudson M, Dhillon AP et al. Acute Indomethacin induced jejunal injury in the rat: early morphological and biochemical changes. Gastroenterology 1994;106:567-75.
11. Ilahi M, Khan J, Inayat Q, Abidi T. Histological changes in parts of foregut of rat after Indomethacin administration. J Ayub Med Coll Abbottabad 2006;18(3):29–34.
12. Dhikav V, Singh S, Pande S, Chawla A. Non-steroidal drug-induced gastrointestinal toxicity: mechanisms and management. JIACM 2003;4(4):315-22.