

Bipolar arthroplasty in highly comminuted intertrochanteric fractures

Girish Sahni^{1,*}, Rahul Kunder², Avinash Chander Gupta³

¹Assistant Professor, ³Professor, Govt. Medical College, Patiala, Punjab, ²Assistant Professor, Dept. of Orthopaedics, SSMC, Rewa, Madhya Pradesh

***Corresponding Author:**

Email: sawhneygirish@gmail.com

Abstract

A hip fracture represents a disturbing and potentially ominous landmark in personal health history. For the health care system and to society in general, intertrochanteric fractures represent an epidemic disease. The present study is being carried out to assess the role of bipolar arthroplasty in case of highly comminuted intertrochanteric fracture of femur. After proper preoperative assessment bipolar arthroplasty was done and results were evaluated.

Materials and Method: Thirty cases of highly comminuted intertrochanteric fractures were treated with bipolar arthroplasty. Adult patients after closure of the epiphysis and all the cases of highly comminuted inter-trochanteric femur fractures were included in the study. Patients with active infection of hip joint or any other region, any unstable medical illness that would significantly increase the risk of morbidity and mortality and patients before closure of epiphysis were excluded from the study.

Follow up was done at stitch removal and then at 1 month interval for 6 months and then 6 months interval for 2 years.

Results: 18 cases (60%) were operated within one week of admission, 9 patients (30%) between 8-14 days and 3 patients (10%) were operated after 15 days. This delay was caused in those cases who required management of associated problems. Primary bipolar cemented arthroplasty was done in all cases. 16 patients (53.33%) were ambulated within 10-14 days and 12 patients (40%) were ambulated within 15-21 days and 2 patients (6.67%) were ambulated after 21 days, because one of the patients was having associated injury of supracondylar fracture femur for which DCS was applied before operation for ipsilateral intertrochanteric fracture femur and in 2nd patient ambulation was delayed as this patient developed DVT. 23 patients (76.67%) gave good results and 6 patients (20%) showed fair results and 1 patient (3.33%) showed poor result.

Conclusion: Primary cemented bipolar arthroplasty is a viable and a suitable option for the treatment of comminuted unstable intertrochanteric fractures of femur as it lessens the duration of recumbency, permits early walking with full weight bearing, reduces the incidence of various postoperative complications of prolonged immobilization and minimizes the duration of hospital stay.

Keywords: Fracture, Femur, Arthroplasty, Hip, Union, Intertrochanteric

Introduction

A hip fracture represents a disturbing and potentially ominous landmark in personal health history. For the health care system and to society in general, intertrochanteric fractures represent an epidemic disease.⁽¹⁾ This fracture is relatively rare in young, the cause is a high energy trauma like vehicular accident or falls from significant heights while in elderly, osteoporotic bones, a trivial fall is the cause of 90% of hip fractures.⁽²⁾ This is further aggravated by other age related impairments like cognitive impairment, decreasing depth perception, decreased mobility, dizziness, and a poor self-perceived state of health which are linked to increased likelihood of sustaining a fall and hence a possible fracture. Women are even more prone to this injury due to greater osteoporosis secondary to a lack of adequate ambulation or antigravity activities as well as decreased hormone levels in postmenopausal age.⁽³⁾

Before the introduction of suitable fixation devices in the 1960s' treatment for intertrochanteric fractures was of necessity non-operative consisting of prolonged bed rest in traction until fracture healing occurred (usually 10-12 weeks), followed by a lengthy program of ambulation training. In elderly patients, this approach was associated with high complication rates

like decubitus, UTI, joint contractures, pneumonia and thromboembolic complications resulting in high mortality rates (Koval and Zukerman, 2001).⁽⁴⁾

In an attempt to early rehabilitate the patient and lessen the duration of recumbency, Giliberty as well as Batemen (1974)^(5,6) came with concept of bipolar and development of tec acrylic bone cement by Charnley (1964) was a major break through in prosthetic replacement surgeries which reduced the complication of loosening and dislocation of the prosthesis.⁽⁷⁾

Over the years orthopaedic surgeons have come to recognize the value of primary arthroplasty rather than other methods of fixation in elderly patients.⁽⁸⁾ Arthroplasty is free from problems like fracture site non union and avascular necrosis. Salvage treatment with hip arthroplasty should and is being increasingly considered for selected older patients with already poor bone quality, bone loss, osteoarthritis or articular cartilage damage.⁽⁹⁾

Hip fractures are associated with notable morbidity and mortality in elderly patients. Internal fixation has drastically reduced the mortality associated with intertrochanteric fractures;⁽¹⁰⁾ however, early mobilization is still avoided in cases with comminution, osteoporosis, or poor screw fixation.⁽¹¹⁾ Primary hemiarthroplasty offers a modality of treatment that

provides adequate fixation and early mobilization in these patients thus preventing postoperative complications such as pressure sores, pneumonia, atelectasis, and pseudo arthrosis.⁽¹²⁾

The treatment of unstable intertrochanteric fractures in elderly patients with severe osteoporosis differs from the treatment of patients with other proximal femoral fractures. These fractures are better treated with cemented hemi-arthroplasty than with internal fixation. Besides an early ambulation and less hospital stay, cemented hemi-arthroplasty provides stable and mobile hips. Weight bearing can be started earlier than in other methods of treatment, which prevents any recumbency related complications.⁽¹³⁾

Materials and Method

Thirty cases of highly comminuted intertrochanteric fractures were treated with bipolar arthroplasty. Adult patients after closure of the epiphysis and all the cases of highly comminuted intertrochanteric femur fractures were included in the study. Patients with active infection of hip joint or any other region, any unstable medical illness that would significantly increase the risk of morbidity and mortality and patients before closure of epiphysis were excluded from the study. Skin traction or skeletal traction was applied to the affected limb on admission. Boyd and Griffin This classification, included fractures from the extracapsular part of the neck to a point 5 cm distal to the lesser trochanter.

Type 1: Fractures that extend along the intertrochanteric line.

Type 2: Comminuted fractures with the main fracture line along the intertrochanteric line but with multiple secondary fracture lines (may be in coronal plane).

Type 3: Fractures that extend to or are distal to the lesser trochanter.

Type 4: Fractures of the trochanteric region and proximal shaft with fractures in at least two planes

Any associated injuries besides extracapsular fractures of femur were managed and associated medical problems were treated and patients were made fit for anaesthesia and subsequently for operative intervention in consultation with the physician and anaesthetists.

To insert bipolar prosthesis, posterior moor's or southern approach was used in all 30 cases. For all prosthetic insertion posterior approach is preferred because bleeding is less and the anterior part of the joint capsule is preserved to keep the hip from dislocating after surgery. Lateral position was maintained by properly placed sand bags and kidney supports.

Post operatively antibiotics and anti-inflammatory analgesics were administered in appropriate doses. Suction was removed after 48 hours. Stitches were removed between 11th and 14th day. Physiotherapy was started 24 hours after operation.

After removal of stitches patient was allowed to walk with the help of crutches with partial weight bearing on the affected side. The patient was discharged from the hospital within two to three weeks of operation and allowed to walk with the help of crutches or walker. Patient was asked to report to the outpatient department for follow up first every month up to period of three months, then after every three months.

Results

This study was conducted on 30 patients with intertrochanteric fracture treated with bipolar arthroplasty in department of othopaedics at government medical college and Rajindra hospital, Patiala. 18 out of 30 patients were in the age group of 50-70 years while 9 patients belonged to age group >70 years and only 3 patients were <50 -years. There were 60% male patients and 40% were female patients in our series.

Table 1

Sex	No. of cases	Percentage
Male	18	60
Female	12	40
Total	30	100

General data of the patients

27 out of 30 cases (90%) of intertrochanteric fracture were caused by severe trauma in the form of vehicular motor accidents and rest of 3 out of 30 cases (10%) were caused by minor trauma in the form of stumbling or fall on uneven surface. 24 out of 30 patients (80%) reported immediately after injury. 3 out of 30 patients (10%) reported within one week of injury and rest 3 out of 30 patients (10%) reported within one to two weeks after injury.

20 out of 30 patients (66.6%) were put on skin traction and rest 10 out of 30 patients (33.4%) received skeletal traction before operation. 18 out of 30 patients (60%) were operated within seven days of admission, 9 out of 30 patients (30%) within 8 to 15 days of admission and rest 3 out of 30 patients (10%) were operated after 15 days of admission in the hospital. Greater trochanter was fixed with SS wire in 3 out of 30 patients (10%) and in 27 out of 30 patients (90%) it was fixed using Vicryl no 1 G and reinforced with cement. All cases were given skin traction after operation for 10 days.

28 out of 30 patients (93.33%) patients were allowed partial weight bearing within 10-14 days of operation.

Table 2

Time in days	No. of cases	Percentage
Within 10-14 days	28	93.33
Within 15-21 days	0	0
More than 21 days	2	6.67

Total	30	100
-------	----	-----

Showing period between operation and ambulation

4 out of 30 patients (13.33%) had superficial infection. 1 out of 30 patient (3.33%) had preoperative cement reaction. 1 (3.33%) patient had chest infection and 1 (3.33%) patient had DVT.

27 out of 30 patients (90%) were allowed full weight bearing within 4-6 weeks of operation.

At the last follow up at 9 months, out of total 30 cases, 23 patients (76.67%) had no pain and 6 (20%) patients had moderate pain and 1 patient (3.33%) had pain restricting movements. 23 patients (76.67%) showed good range of flexion and abduction movements, 6 patients (20%) showed fair range of movements and 1 patient (3.33%) showed poor range of movements. 23 cases (76.67%) did not require any aid while walking and 6 patients (20%) require stick and 1 (3.33%) patient require walker. 23 cases (76.67%) did not limp while walking and only 7 cases (23.33%) had

limp while walking. 23 cases (76.67%) were able to squat and / or sit cross legged, while 6 cases (20%) were having difficulty in squatting or sitting cross legged and 1 patient (3.33%) was not able to sit cross legged.

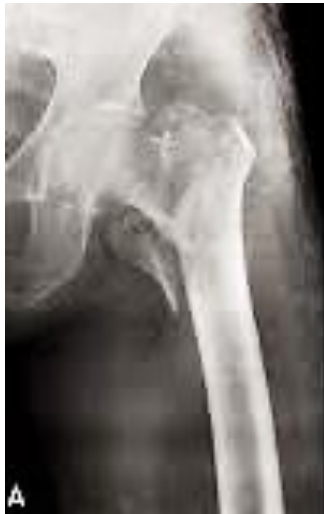Table 3

Criteria	No. of cases	Percentage
Good	23	76.67
Fair	6	20
Poor	1	3.33
Total	30	100

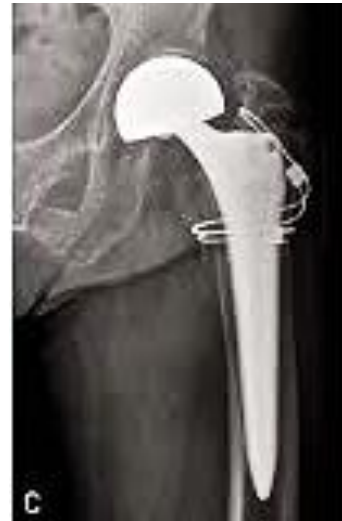Results

23 cases (76.67%) showed good results after evaluating the results from the laid down criteria, 6 cases (20%) showed fair results and 1 case (3.33%) showed poor result.

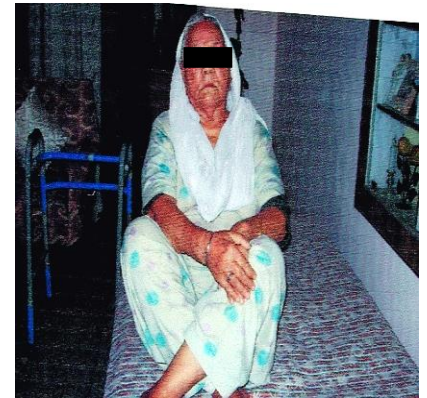
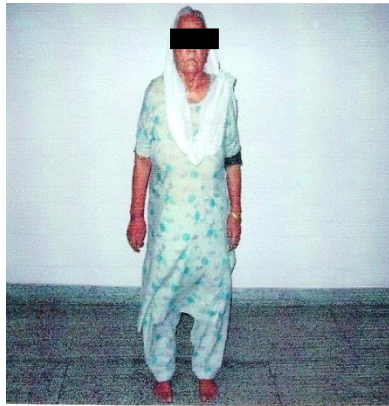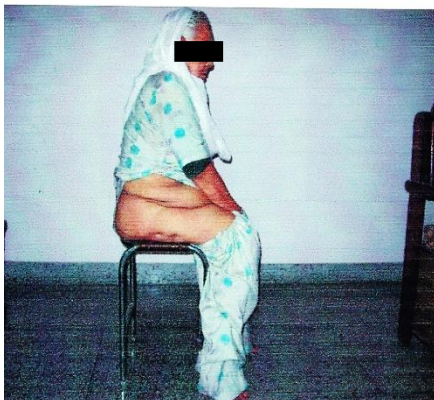
Case 1



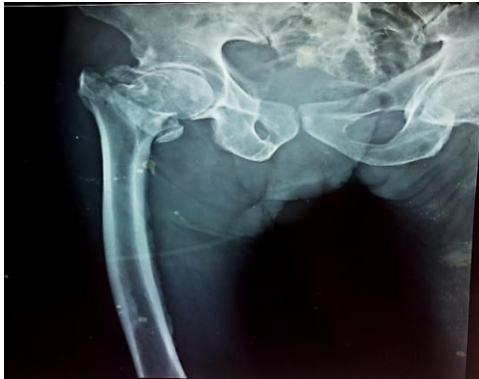A: Pre Operative X-ray showing comminuted intertrochanteric fracture



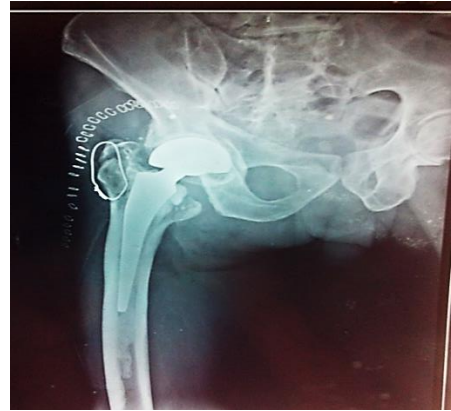B: Post Operative X-ray after bipolar hemiarthroplasty



Patient showing flexion –Patient showing full weight bearing Patient showing sitting and adduction



Pre-Op X-ray



Post-Op X-ray



Patient showing flexion – abduction and scar mark



Patient showing full weight bearing

Discussion

Primary bipolar arthroplasty has been advocated in patients with a view to make the rehabilitation early and to lessen the incidence of complications of prolonged immobilization. The major advantage of treatment with cemented bipolar endoprosthesis the early weight bearing and the rehabilitation of these patients to their prefractures level more quickly than is achieved with various fixation devices.

In the present study of 30 cases, Modular and talwalkar type of bipolar cemented endoprosthesis were used for treatment of comminuted intertrochanteric fractures of femur in all age groups in the department of orthopaedics, Rajindra hospital, Govt. Medical College, Patiala.

Table 4: Showing age distribution

Age in years	No of cases	Percentage
<50	3	10
50-70	18	60
>70	9	30
Total	30	100

Thus most of the patients in our series were of 50-70 yrs of age.

There were 13 cases (43.34%) with fracture on right side and 17 cases (56.67%) with fracture on the left side and in 27 out of 30 patients (90%) fracture were caused by severe trauma in the form of motor vehicular accidents and in rest 3 out of 30 patients(10%) fracture was caused by minor trauma in the form of stumbling or fall on uneven surface.

Kessmenli (2001) studied that intertrochanteric fractures are seen in elderly people and occur mostly by minor trauma. Mortality and morbidity rates are high. Internal and external fixation is used for treatment. Treatment with endo prosthesis thought to be helpful in decreasing these complications and early mobilizations of the patients.⁽¹⁴⁾

Bipolar hemiarthroplasty offers a durable and versatile solution for trochanteric fractures in the elderly. It can be done as a primary procedure or secondary to failure of conservative or operative treatment, offering an advantage of rapid return of function with a pain free stable hip with 4-5% need for revision surgery as compare to 30-40% with traditional internal fixation.⁽¹⁵⁾

We grouped patients as per Boyed and Griffin classification and A.O. classification but for operative purposes we followed Boyd and Griffins classification.

24 out of 30 patients (80%) in our series reported immediately after injury for admission, and 3 out of 30 patients (10%) reported within one week and rest 3 out of 30 patients (10%) reported within two weeks. Delayed was caused because of treatment given by local practitioners or quacks. Delayed recognition of hip fracture can result in increased morbidity and mortality, as well as a rapid decline in quality of life. One-year mortality rates after this injury range from 15 to 20 percent.⁽¹⁶⁾

Depending upon the comminution of the fracture and duration of injury, patients were put on skin traction or skeleton traction preoperatively. 20 out of 30 patients (66.6%) received skin traction and 10 out of 30 patients (33.4%) were put on skeleton traction. Gong MQ et al concluded that one-year mortality was 8.8% (9/102), According to the incidence, the complications include bed sore (30/102, 29.4), pulmonary infection (6/102, 5.9%), DVT (2/102), PE (1/102), Urine infection (1/102). The rate of healing in femoral neck fractures was 51.7% (15/29); in intertrochanteric fractures was 97.6% (40/41). The decrease of Harris score between pre-injury and post-injury was 23.1 in femoral neck fractures and 15.6 in intertrochanteric fractures.⁽¹⁷⁾

In our series, 4 patients (13.4%) had anemia, 4 patients (13.4%) had diabetes mellitus and 4 patients (13.4%) of patients had hypertension which were dealt preoperatively by building up the patients for surgery. One patient (3.4%) was asthmatic and was put on bronchodilator drugs. One patient (3.4%) presented with associated injury in form of supracondylar fracture femur for which DCS was applied before operating for intertrochanteric fracture.

18 out of 30 patients (60%) were operated within one week of admission, 9 out of 30 patients (30%) between 8-14 days and rest 3 out of 30 patients (10%) were operated after 15 days. This delay was caused in those cases who required management of associated problems like DM, HT, anaemia, chest infection and even skeleton traction who presented late, while JC Hyuk et al concluded that Among the 874 patients, 162 (18.5%) received surgery within 3 days and their 1-year mortality rate was 9.9%, patients who received surgery in 3-7 days (Hazard ratio = 1.0; 95% confidence interval [CI]: 0.7-1.6) and over 7 days (hazard ratio = 1.3; 95% CI: 0.9-1.8) were not significantly different. In addition, the time to surgery did not have a significant effect on 30-day mortality, 60-day mortality or complications arising during hospitalization.⁽¹⁸⁾

Primary bipolar cemented arthroplasty was done in all cases. We used posterolateral approach (modified Gibsons) for surgery. In posterolateral approach bleeding was less and the chances of dislocation of the prosthesis decreases. In this approach hip is dislocated by internal rotation and the anterior part of joint capsule is preserved to keep the hip from dislocating after surgery. A. Zahar et al concluded The posterior

approach seems to be at higher risk for dislocation and possible early reoperation, despite all of its advantages.⁽¹⁹⁾

Pho (1981) reported a prospective study of eight cases of unstable, comminuted intertrochanteric fractures in elderly patients with associated osteoporosis, operated on between June 1978 and May 1979 using a short-stem Thompson's prosthesis with cement. The posterior approach was employed. The amount of blood loss encountered with this technique was not more than that with nail reduction methods. The results have been encouraging in enabling the patients to walk early.⁽²⁰⁾

Grimsrud (2005) in his study reviewed 39 consecutive patients with unstable three or four part intertrochanteric hip fractures treated with cemented bipolar hip arthroplasty. A standard length primary femoral component was used with a novel technique of circlage fixation of the trochanteric bone fragments allowing retention of femoral calcar. At one year minimum follow up, there was no loosening or subsidence of the femoral components. All trochanters healed. One dislocation and one deep infection occurred. Unstable three or four part hip fractures can be treated with a standard femoral stem prosthesis and circlage wiring of the trochanters. This technique allows safe early weight bearing on the injured hip and had a relatively low rate of complications.⁽²¹⁾

Kim and co-workers 15 reviewed 178 intertrochanteric fractures which were treated by DHS fixation. They used Singh's index for evaluating degree of osteoporosis and Evans' classification for assessing stability of fractures. They found failure of fixation in the form of a varus angulation of $>100^\circ$, perforation of femoral head, more than 20 mm of extrusion of a lag screw or metal failure, in 49 (27%) cases. Among these, 2 fractures were stable, and 47 were unstable. Thus, the conclusion was unstable fractures with osteoporosis had failure rate was of $>50\%$ and that in such cases, dynamic hip screws should not be the first choice of treatment.⁽²²⁾

Stern and Angerman reported that all the hips were stable after hemiarthroplasty regardless of whether the greater trochanter was anatomically reduced or just sutured near the prosthesis.⁽²³⁾

One retrospective study by Kesmazar et al⁽²⁴⁾ demonstrated a higher rate of morbidity & mortality among the hemiarthroplasty group. This may be explained by the longer operative time and hospital stay along with a delay in the mobilization of the patient.

In 27 out of 30 patients (90%) Modular type of bipolar prosthesis was used, in rest 3 out of 30 patients (10%) Talwalkars type prosthesis was used. No definite criteria was used as all given equally good results but was according to financial constraints of the patients. Modular type has definitive advantage as it can be converted to total hip replacement in future course of time without disturbing the femoral component.

All cases (100%) were given skin traction for 10 days to reduce postoperative soft tissue edema.

In our series, 16 out of 30 patients (53.33%) were ambulated within 10-14 days, 12 out of 30 patients (40%) were ambulated within 15-21 days and rest 2 out of 30 patients (6.67%) were ambulated after 21 days, because one of the patients was having associated injury of supracondylar fracture femur for which DCS was applied before operation for ipsilateral intertrochanteric fracture femur and in 2nd patient ambulation was delayed as this patient developed DVT for which treatment was started in form of LMWH, antibiotics and anti-inflammatory drugs. S.L. Albert et al concluded that in patients with hip fracture, delay in getting the patient out of bed is associated with poor function at 2 months and worsened 6-month survival.⁽²⁵⁾

Table 5: Showing period between operation and ambulation

Time in days	No. of cases	Percentage
Within 10-14 days	28	93.33
Within 15-21 days	0	0
More than 21 days	2	6.67
Total	30	100

In our study group, 4 out of 30 patients (13.3%) developed superficial infection. Out of these 4 patients, 2 patients were diabetic. One patient (3.3%) had mild cement reaction preoperatively. One patient (3.3%) developed severe DVT postoperatively. One patient 3.3% developed postoperative chest infection. Reported infection rates in the literature are currently 1% to 2% for primary THR and are higher after total hip revision.⁽²⁶⁾

Table 6: Showing complications

Complications	No. of cases/30	Percentage
Cement Reaction	1	3.3
Superficial Infection	4	13.33
Deep Infection	-	-
Dislocation	-	-
DVT	1	3.3
Pulmonary Complications	1	3.3
Bed Sores	-	-
Fracture Shaft of Femur	-	-
Loosening of Stem	-	-
Mortality	-	-

There was no loosening of stem and proximal migration of prosthesis. Loosening and migration of prosthesis either proximally or distally manifested radiographically by protrusion or absorption of calcar femorale.

In our series all patients (100%) came for follow up for 9 months: 27 out of 30 patients (90%) were allowed full weight bearing within 4-6 weeks and rest 3 patients (10%) took more than six weeks for full weight bearing. Of these 3 patients, one patient had associated injury, one patient developed DVT and one patient had pain resulting in limitation of motion and had difficulty in full weight bearing.

In our series, 23 out of 30 patients (76.7%) had no pains in doing day to day activities and had 90° flexion movement and abduction movement more than 35°. 6 out of 30 patients (20%) had moderate pain but needed no analgesics for his daily routine, these patients had flexion movements between 15°-35°. 1 patient (3.33%) had pain restricting movements, had flexion and abduction less than 15°. In our study group 23 out of 30 patients (76.67%) walked without any aid, 6 out of 30 patients (20%) required stick for walking and one patient (3.33%) had difficulty in walking even with walker. 23 out of 30 patients (76.67%) walked without any limp and rest 7 out of 30 patients (23.3%) walked with limp. Of these seven patients 6 had Hip fractures are associated with notable morbidity and mortality in elderly patients. Internal fixation has drastically reduced the mortality associated with intertrochanteric fractures; 41 however, early mobilization is still avoided in cases with comminution, osteoporosis, or poor screw fixation.^{42,43} Primary hemiarthroplasty offers a modality of treatment that provides adequate fixation and early mobilization in these patients thus preventing postoperative complications such as pressure sores, pneumonia, atelectasis, and pseudo arthrosis. ^{44,25} moderate pain and limitation of flexion and abduction and one patient had pain and marked limitation of flexion and abduction movements.

Of these 30 patients in our series, 23 out of 30 patients (76.67%) were able to sit cross legged and 6 out of 30 patients (20%) were able to sit cross legged with difficulty and one patient (3.33%) was not able to sit cross legged.

So with all above discussion we conclude that 23 out of 30 patients (76.67%) gave good results, 6 out of 30 patients (20%) showed fair results and 1 patient (3.33%) showed poor result. The outcome and results of the present study was as good and matches with the previous studies.

Conclusion

Although extracapsular fractures of femur are associated with high rate of morbidity and mortality but early walking with full weight bearing after primary cemented Bipolar arthroplasty significantly reduces the incidences of various postoperative complications

associated with prolonged immobilization i.e. venous thrombosis, pressure sores and pulmonary complication.

Therefore, primary cemented bipolar arthroplasty is a viable and a suitable option for the treatment of comminuted unstable intertrochanteric fractures of femur as it lessens the duration of recumbency, permits early walking with full weight bearing, reduces the incidence of various postoperative complications of prolonged immobilization and minimizes the duration of hospital stay.

Consent

Proper consent of all patients were taken.

Ethical Approval

Study was done as per ethical committee approval.

References

- Melton LJ, 3rd. Hip Fractures: A worldwide problem today and tomorrow. *Bone* 1993;14 Suppl 1:s1-8.
- Alffram PA. An epidemiologic study of cervical & trochanteric fractures of the femur in an urban population with special reference to etiologic factors. *Acta Orthopscand* 1964;65:9-109.
- Aitken JM. Relevance of Osteoporosis in women with fractures of femoral neck. *Br. Med. J* 1984;288:697-601.
- Koval KJ, Zuckerman JD, Robert W Bucholz, James D Heckman, eds. Intertrochanteric fractures. In: Rockwood and Green's fractures in adults. 5th edn. Philadelphia; Lippincott Williams and Wilkins: 2001. p. 1635, 42-44.
- Giliberty RP. A new concept of the bipolar endoprosthesis. *Orthop Rev* 1974;3:40.
- Bateman JE. Single assembly total hip prosthesis preliminary report. *Orthop Dig* 1974;2:15.
- Charnley J. the bonding of the prosthesis to bone cement. *J Bone & Joint Surgery* 1964;46-B:518-29.
- PHO RW, Nather A, Tong GO, Korkenctendoprosthesis replacement of unstable comminuted 17 fractures of femur in the elderly osteoporotic patient. *Trauma* 1981;21:792-7.
- Haidukenychgj and Berry DJ, Hip Arthroplasty for salvage of failed treatment of intertrochanteric Hip fractures. *J Bone Joint Surg* 2003; May 85A:899-904.
- White BL, Fisher WD, Laurin CA. Rate of mortality for elderly patients after fracture of the hip in the 1980's. *J Bone Joint Surg Am.* 1987;69:1335-40. [PubMed]
- Wolfgang GL, Bryant MH, O'Neill JP. Treatment of intertrochanteric fracture of the femur using sliding screw plate fixation. *Clin Orthop Relat Res.* 1982;163:148-58. [PubMed]
- Haentjens P, Casteleyn PP, Opdecam P. The Vidal-Goalardmegaprosthesis: An alternative to conventional techniques in selected cases? *Acta Orthop Belg.* 1985;51:221-34. [PubMed]
- Kiran Kumar GN, Sanjay Meena, Vijaya Kumar N, Manjunath S, and Vinaya Raj MK, Bipolar Hemiarthroplasty in Unstable Intertrochanteric Fractures in Elderly: A Prospective Study, *J Clin Diagn Res.* 2013 Aug;7(8):1669-1671.
- Kessmenli C, Subasi M, Arslan H, Kirkgoz T, Necmioglu S. Treatment of intertrochanteric fracture Keses in elderly patients with Leinbach type endoprostheses. *Ulus Travma Derg* 2001;7(4):254-7.
- PHO RW, Nather A, Tong GO, Korken CT endoprosthesis replacement of unstable comminuted 17 fractures of femur in the elderly osteoporotic patient. *Trauma* 1981;21:792-7.
- Keating JF, Grant A, Masson M, Scott NW, Forbes JF. Randomized comparison of reduction & fixation, Bipolar Hemiarthroplasty, & Total Hip Arthroplasty. *J Bone & Joint Surg (Am)* 2003 feb 88 (2) 249-60.
- Ohnell O. The socioeconomic burden of fractures: today and in the 21st century. *Am J Med.* 1997;103(2A):20S-5S.
- Gong MQ [Outcome of hip fractures after traction treatment in elderly], *Zhonghua Yi XueZaZhi.* 2005 Dec 7;85(46):3263-5.
- JC HYUK, The timing of surgery and mortality in elderly hip fractures, *Indian J Orthop.* 2014 Nov-Dec; 48(6): 599-604.
- Sikes CV, Lai LP, Schreiber M, Mont MA, Jinnah RH, Seyler TM. Instability after total hip arthroplasty: treatment with large femoral heads vs constrained liners. *J Arthroplasty.* 2008;23(7 Suppl):59-63. doi: 10.1016/j.arth.2008.06.032. [PubMed] [Cross Ref]
- Pho RW, Endoprosthesis replacement of unstable, comminuted intertrochanteric fracture of the femur in the elderly, osteoporotic patient, *J Trauma.* 1981 Sep;21(9):792-7.
- Grimsrud C, Monzon RJ, Richman J, Ries MD. Cemented hip arthroplasty with a novel cerclage cable technique for unstable intertrochanteric hip fractures. *J Arthroplasty* 2005 Apr;20(3):337-43.
- Kim WY, Han CH, Kim JY. Failure of intertrochanteric fracture fixation with dynamic hip screw in relation to pre-operative fracture stability and osteoporosis. *Int Orthop.* 2001;25:360-62.
- Stern MB, Angerman ALEX. Comminuted Intertrochanteric Fractures Treated with Leinbach Prosthesis. *Clin Orthop.* 1987;218:75-80.
- Kesmezacar H, Ogut T, Bilgili MG, Gokay S, Tenekecioglu Y. Treatment of intertrochanteric femur fractures in elderly patients: internal fixation or hemiarthroplasty. *Acta Orthop Traumatol Turc.* 2005;39(4):287-294.
- L.S. Albert. Early Ambulation After Hip Fracture *Arch Intern Med.* 2006 Apr 10;166(7):766-771.
- S. Angela. Treatment of an infected total hip replacement with the PROSTALAC system *Can J Surg.* 2007 Feb;50(1):24-28.