

## Evaluation of results of fracture Proximal Humerus treated with Kirschner Wire and mini external fixation

Jayant Sharma<sup>1,\*</sup>, Prashant Upadhyaya<sup>2</sup>

<sup>1</sup>Professor, Index Medical College, Indore, Madhya Pradesh, <sup>2</sup>Resident, Dept. of Orthopaedics, Unique Superspeciality Hospital, Indore, Madhya Pradesh

**\*Corresponding Author:**

Email: jayantjaikishansharma@gmail.com

### Abstract

Fracture of Proximal humerus are most common humerus fracture (45%). These are more common than hip fracture. As the patient has a direct fall on the limb these fractures are mostly undisplaced (85%). These are more common in osteoporotic patients in elderly age group. Aim of the management is early mobilization. JESS is a mini external fixator invented by Dr. B. B. Joshi and it is, A simple light mini fixator with Ease of application and has Fixed angle stability.

We have used this fixator in 25 cases of proximal humerus received by us, and treated with this method as, it Avoids dissection of Deltoid, Rotator Cuff and biceps due to use of small pin diameter has a Lower incidence of AVN, with Minimal blood loss. It also eliminates another Surgery for Hardware removal and is based on the principle of faster rehabilitation.

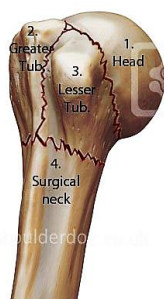We found this technique to be effective in Effective in polytrauma.

### Introduction

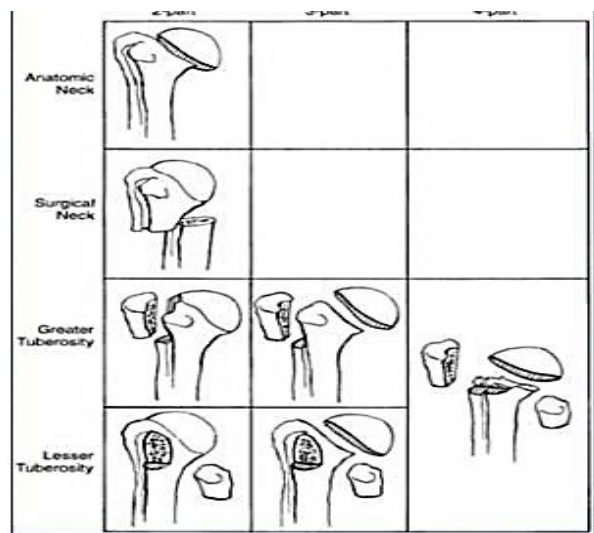
Fracture of Proximal humerus are most common humerus fracture (45%). These are more common than hip fracture. As the patient has a direct fall on the limb these fractures are mostly undisplaced (85%). These are more common in osteoporotic patients in elderly age group.

Divided into 4 osseous segment:

1. Anatomical neck/ Humerus head
2. Surgical neck/ Humerus shaft
3. Greater tuberosity (GT)
4. Lesser tuberosity (LT).



The fracture is classified as per Neer classification into



**Fig. 1: Neer classification for proximal humerus fractures**

In all these cases the aim of the management is early mobilization. This could be achieved by non operative or open methods using Plate and screws, like PHILOS and modified buttress plating, or use of external fixation and K wires fixation alone, of all the spectrum of fractures available, in co morbid patients, or osteoporotic elderly patients and polytraumatized head injury patients an external fixator serves its role to efficacy.

There are drawbacks of each and every method, like in non operative treatment there is Failure to obtain early mobilization which results in: Higher rate of Shoulder Stiffness, Pain and Malunion.

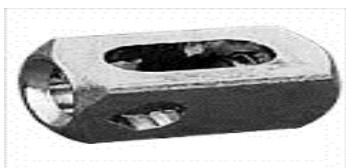
With open reduction and fixation, Difficulty in achieving rigid fixation in cancellous bone as cortical bone is very thin shell and weak purchase of screw results in pull out, Intra op bleeding, Increased Risk of

AVN, Adhesions post operatively, reduce ROM due to excessive dissection.

With arthroplasty the disadvantages are, Stiffness, Scarring, Hardware problems, Tuberosity malposition and the functional score are same as External Fixator.

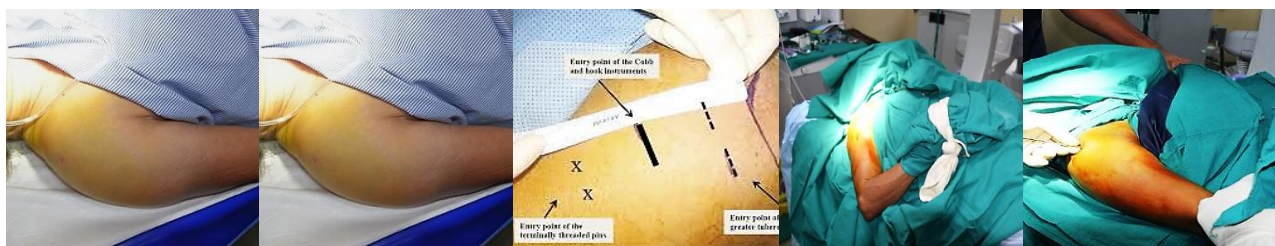

External fixation avoids dissection of Deltoid, Rotator Cuff and biceps due to use of small pin diameter. Lower incidence of AVN as the Ascending branch of Anterior circumflex Humeral artery is not disturbed. Hence there is minimal blood loss and less scarring of scapulo humeral interface. Eliminates another Surgery for Hardware removal provides faster rehabilitation, and effective in polytrauma, as can be done in Supine position. Some authors have reported good to excellent results in Osteoporotic fractures Hence we used JESS fixator, as JESS is a mini external fixator invented by Dr. B. B. Joshi and it is, A simple light mini fixator with ease of application and has fixed angle stability.

a. Link joints



Basic clamping unit of JESS, Cross holes at different levels. One is oval other is round and perpendicular to oval hole.

b. Connecting rods



2.5mm Schanz pin/ K wire at humeral head from GT to subchondral head in true lateral, 1<sup>st</sup>: In true lateral/ coronal plane

2<sup>nd</sup>: just lateral to bicipital groove

3<sup>rd</sup>: 30° posterior to 1<sup>st</sup> one.

Diameter vary from 2-4mm and are available in various lengths.

We have used this fixator in 20 cases of proximal humerus, from July 2015 to April 2017 received by us, and treated with this method as, it Avoids dissection of Deltoid, Rotator Cuff and biceps due to use of small pin diameter has a Lower incidence of AVN, with Minimal blood loss. It also eliminates another Surgery for Hardware removal and is based on the principle of faster rehabilitation.

We found this technique to be effective in Effective in polytrauma.

### Materials and Method

We operated 20 such patients in the age group of 55 to 75 years received in our OPD.

The X-rays were taken in Perpendicular to plane of scapula to show gleno humeral joint and Parallel to plane of scapula to show A-P displacement. Axillary view: To see A-P relationship

#### Inclusion criteria:

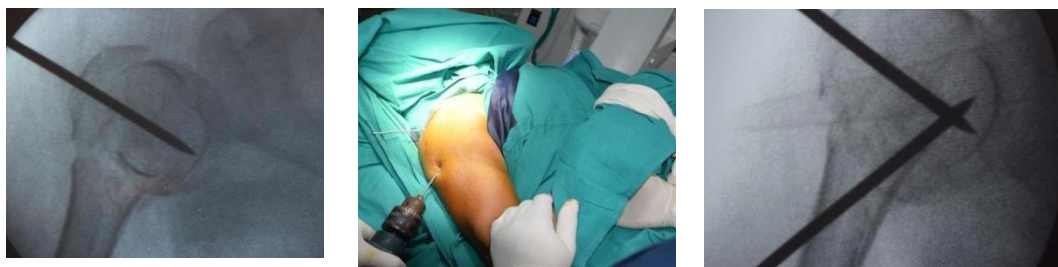- Osteoporotic fractures
- Head injury/polytraumatized patients
- Not accepting major procedure.

#### Exclusion criteria:

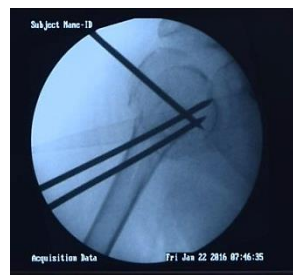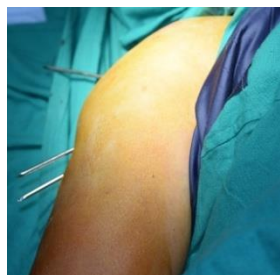
- Young atheletic adult.

After preoperative investigations and fitness these were subjected to surgery, under, GA/ Brachial block and Supine position with a sand bag to elevate shoulder. These structures at risk:

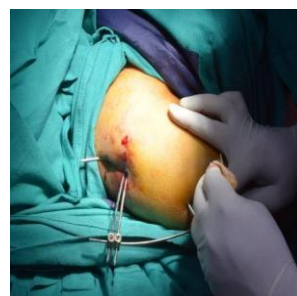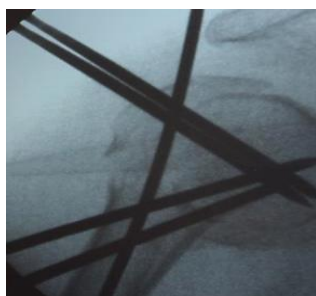
- a. Axillary nerve
- b. Posterior humeral circumflex artery
- c. Anterior branch of Axillary Artery.
- d. Cephalic vein.
- e. Biceps tendon
- f. Musculocutaneous nerve



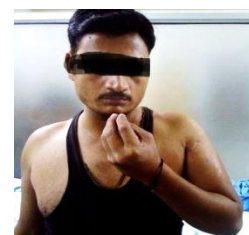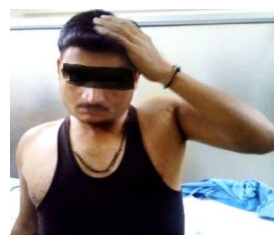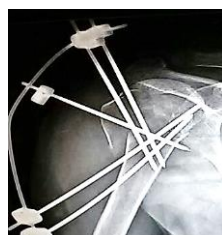
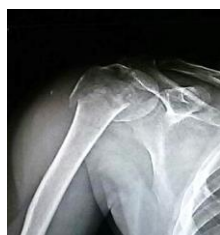Next pin inserted in line with 1<sup>st</sup> pin, approximately 4cm below it in upper third of Humerus. 3<sup>rd</sup> pin placed 2cm below the above pin

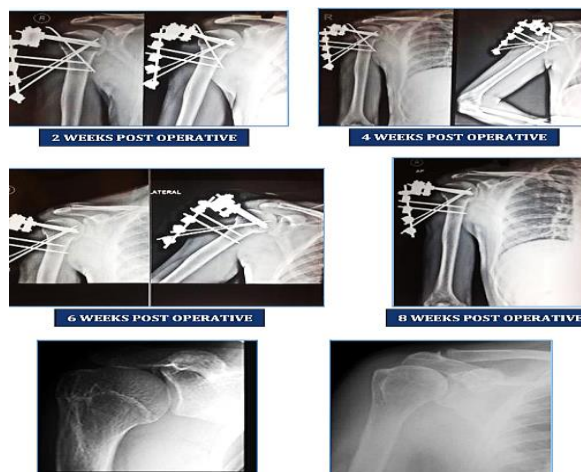


A wire can be placed from the head to bring down the head as near to the shaft. Now the wires are joined through Link joints of JESS and a curved rod

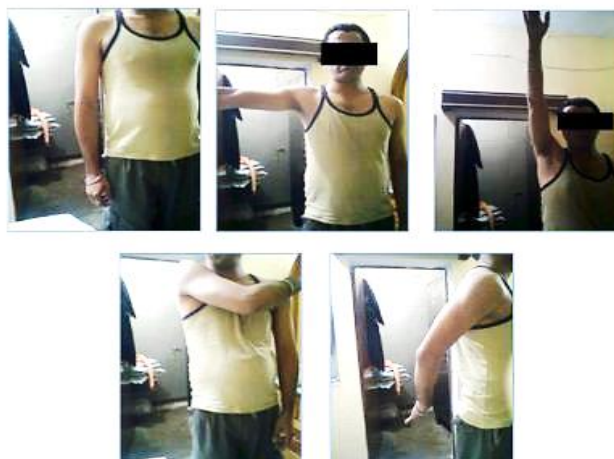

Postoperatively, the limb is kept in Pouch arm sling is applied. From the second day onwards Pain free ROM is started as soon as patient becomes pain free. Pins cleaned with Povidone iodine. Patient follow up for 2, 4, 6 and 8 weeks.





External fixator was removed at 6 or 8 week. Then followed up for bimonthly till 1 year.



The results were evaluated as per constant scoring system, which comprises of, four variables that are used to assess the function of the shoulder.

- The subjective variables were
- Pain
- Activities of daily living (ADL) (sleep, work, recreation/ sport), which give a total of 35 points (pain: 15, ADL: 20).
- The objective variables were
- Range of motion
- Strength, which give a total of 65 points (range of motion: 40, strength: 25).

Altogether there are 100 points. Constant Score divides the outcome of patients into four categories, i.e.

- Excellent having a score >85,
- Good having a score between 71 and 85,
- Fair having a score between 61 and 70,
- Poor outcome with a score of 60 or less.

### Observations and Results

The study comprised of 20 patients of which 14 were females. These patients had right sided dominance(16) and due to fall at home mainly in these patients who were elderly(14), the polytraumatized patients were (6).

These were operated within 48hrs of injury and the patients were discharged after 48hrs in non polytraumatized patient.

The X-rays were repeated after 2, 4, 6, and 8 weeks. To assess union rate.

- The Fixator was removed, after 8 weeks in most of the patient, only 3 patients had pin tract infection, which was superficial in all and did not warrant for early removal of fixator. The other complication observed were, Non union(3), Bicipital tendinitis(2 patients) and Reflex sympathetic dystrophy (2patients) there was Loss of reduction in 3 patients who had non-union eventually.
- Poor outcome with a score of 60 or less.

### Discussion and Conclusion

JESS Assembly consists of: A simple light modular mini fixator which was invented by Dr. B. B. Joshi and it has high safety profile. Has an advantage of: Fixed angle stability, Provides stability even in osteoporotic fractures, Early results are encouraging, No comparison with plating and hemiarthroplasty available. Still reviewing few of the available literatures and comparing our results with these was done and we found out that, Early mobilization and ease of fixation

is an advantage with External fixation devices. Elderly Patients and osteoporotic fractures are well managed with Ex. Fix. Avoids need of redo surgery. Less expertise needed, Surgeon and Patient friendly procedure.

In a study of Resch H et. al, JBJS (Br) 1997, they reported that in 3 or 4 part fracture 90% good to excellent results with AVN incidence was 1%. Our study results were also similar to the study of Resch.

In another study of Chen CY, Journal of Trauma 1998, 2 or 3 part fracture showed 85% good results. Our results were also in similar range with majority of patients happy.

Calvo et. al Journal of Shoulder and Elbow 2007, reported that Excellent to good results in 2 and 4 part fractures was 85% with percutaneous pinning and external fixation, with early mobilization and the rate of AVN incidence was 2%. In our series we didn't have any AVN, and 85% patients had good to excellent results.

We conclude by our study that JESS is a superior method for fixation of proximal humerus in elderly, osteoporotic, polytraumatized patients, because, Avoids dissection of Deltoid, Rotator Cuff and biceps due to use of small pin diameter, Lower incidence of AVN, Minimal blood loss. Eliminates another Surgery for Hardware removal. Faster rehabilitation and is Effective in polytrauma.

## References

1. Koukakis A et.al. Proximal humerus fracture fixation: CORR 2006;442:115-120.
2. Egol KA Ong CC. Early complications of proximal humerus fractures: Journal of Orthopaedic trauma: 2008;22:159-164.
3. Lee C.W Shin Sj. Prognostic factors of unstable proximal fractures Journal of Shoulder and Elbow surgery: 2009;18:83-88.
4. Resch H et.al, JBJS (Br) 1997, Chen CY, Journal of Trauma 1998.
5. Calvo et.al Journal of Shoulder and Elbow 2007.