

3D CT Imaging for assessment of toothbrush induced peritonsillar perforation in an epileptic patient: A case report of a rare complication

N. Kannan^{1,*}, Teja Srinivas Kavuri², Suneetha Pentyala³, Rakesh Kumar Manne⁴, Prathi Venkata Sarath⁵

¹Professor & HOD, ²PG Student, ^{3,4}Professor, ⁵Reader, Dept. of Oral Medicine & Radiology, Narayana Dental College & Hospital, Nellore, Andhra Pradesh

***Corresponding Author:**

Email: dentkan1@gmail.com

Abstract

A 50yr. Old female patient was brought in by her relatives with a chief complaint of toothbrush getting stuck in throat while brushing. She had difficulty in opening mouth and was unable to speak. Medical History revealed history of epilepsy with discontinuation of medications for the past two years. Axial, Sagittal and 3-dimensional reconstructed CT images were taken in the site of the injury for evaluation of the injury and to rule out damage to vital structures & proximity to the vital structures. The images clearly delineated the presence of the toothbrush causing perforation of the peritonsillar region. The Toothbrush was sectioned and removed carefully under sedation.

Keywords: Peritonsillar perforation, Axial CT, Sagittal CT, 3-D Reconstructed CT, Epileptic Injury

Introduction

Tooth brushing is an essential habit for maintaining oral hygiene and the toothbrush is usually considered as a harmless device incapable of causing injury. Rarely, injuries may occur during tooth brushing when excess force is used pushing the toothbrush into the soft tissues. Such injuries are usually small & can be treated easily. On Rare occasions, there may be injuries like deep laceration or impaling of the toothbrush into the soft tissues.⁽²⁾ Trauma inflicted on the soft palate, faucial pillars or the oropharynx, may become life-threatening if they produce edema or swelling of the glottis resulting in blockage of the oropharyngeal airway.

Epileptic seizures occur as a result of abnormally excessive neuronal discharges in the brain and are generally characterized by uncontrolled movements of limbs or head. They may be associated with after effects like disorientation, euphoria or loss of consciousness. The uncontrolled or unconscious movements of head or hands during tooth brushing may result in trauma to the maxillofacial region which may result in injuries to the hard and soft tissues in this region.

Case Report

A 55 years old female patient, reported to the department of oral medicine with a complaint of toothbrush stuck in the throat region. Her medical history revealed that she was having epileptic seizures since three years for which she had taken carbamazepine 100mg three times daily for 2 years. She had stopped taking the medicines by herself since she did not have any epileptic seizures during these 2 years.

Her husband gave a history of a sudden epileptic attack the previous day which lasted for five minutes associated with loss of consciousness which lasted for

10 minutes. Her husband then noticed a swelling in back portion of the right side of her face near the ear. There was no history of any associated vomiting, head injury or other bodily injuries sustained during the epileptic attack. On extra oral examination, a swelling was observed behind the ear near the mastoid region. On intra oral examination, there was limited mouth opening of about 3.5cms and it was apparent that the toothbrush had got stuck into the oropharynx, penetrating the tonsillar fossa. Upper left central incisor showed mobility (Miller's grade II). Blood clots and an ulcerated area were observed in the right tonsillar fossa region measuring about 2×3cms in size. On palpation the ulcer was soft and tender. The length of the tooth brush was firmly lodged into the tissues.

Coronal, sagittal and 3-D reconstructed CT scans were taken using The CT Scans revealed a well defined radiopaque outline of the toothbrush embedded in the oropharyngeal faucial pillars. The location of the head of the tooth brush was observed as present in the right side posterior cervical space. The proximal portion of the toothbrush was located postero-medially and below the right side mastoid region. Considerable space was present between the common carotid artery and the location of the toothbrush. The patient was prepared for surgery under sedation with midazolam. The toothbrush was cut into two pieces using an aerotor. The pieces of the toothbrush were removed carefully by blunt dissection followed by wound closure with vicryl 2.0 sutures. The patient was put on Augmentin 625mg b.i.d., metronidazole 400 mg t.i.d. along with diclofenac sodium 100mg b.i.d. and serratiopeptidase 10mg t.i.d. for 5 days post-operatively. Regular dressings were carried out and the patient was discharged after seven days. At the time of discharge the wound was healing nicely and the mouth opening was significantly improved up to 4.2cms. Chlorhexidine mouthwash after

meals and topical benzocaine gel application before meals were prescribed for 20 days.

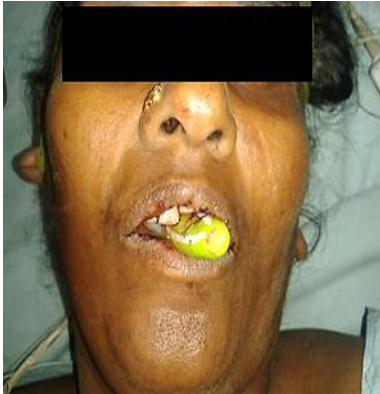

Fig. 1: Tooth perforation 1

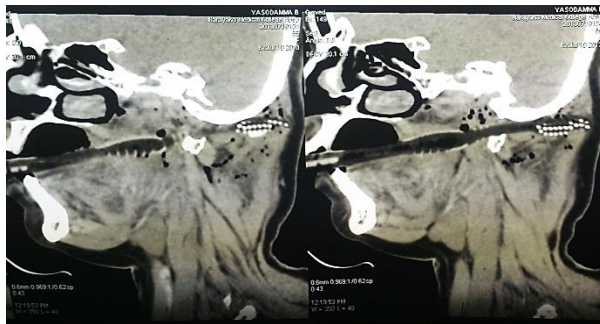


Fig. 2: Tooth perforation 4

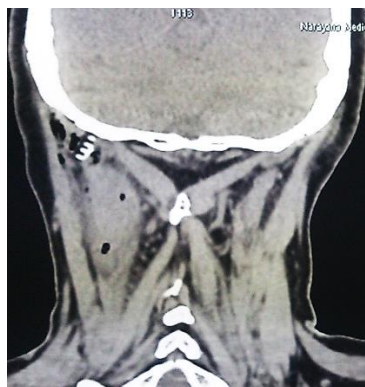

Fig. 3: Tooth perforation 5

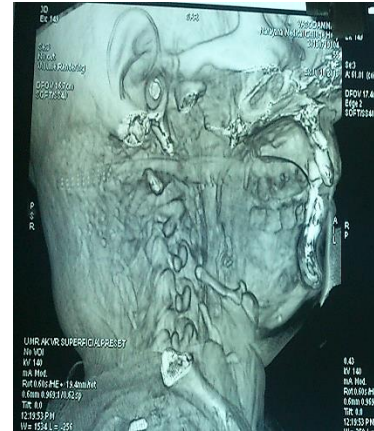

Fig. 4: Tooth perforation 6

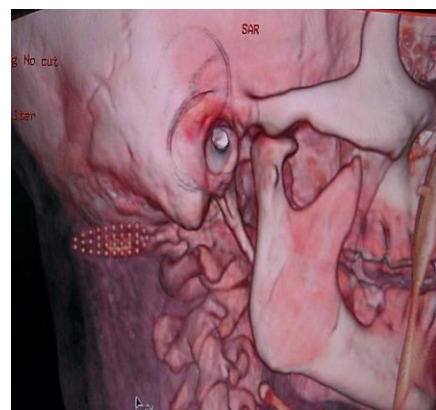


Fig. 5: Tooth perforation 7

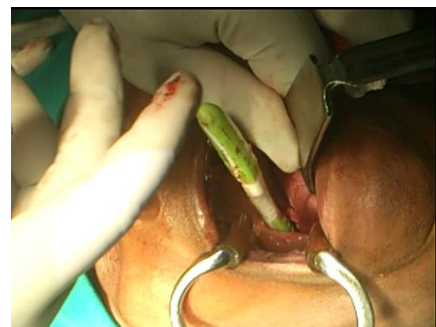

Fig. 6: Tooth perforation 8

Discussion

Generalized tonic-clonic seizures often cause minor oral injuries, such as tongue biting, but may occasionally result in maxillofacial trauma. Patients with epilepsy are at increased risk of maxillofacial injuries because of the jerky uncontrolled movements of the head and the post epileptic features like disorientation or stupor. Antiepileptic drugs like phenytoin, Phenobarbital or carbamazepine may also cause disorientation as one of their side effects. These anti epileptic drugs are known to affect the vitamin D and calcium metabolism with resultant weak bones and increased susceptibility to fractures.

D'Souza et al. have suggested that tooth brushing can induce epileptic attacks in patients with lesions in the primary somatosensory area.⁽⁵⁾ Tooth brushing produces a rhythmic oral sensory stimulus which may evoke the neuronal discharges to induce seizures. Vagal stimulation by tooth brushing may occasionally result in vaso vagal syncope in some susceptible individuals.⁽⁶⁾

Apparently harmless injuries to the oro-pharynx have been reported to cause internal carotid artery dissection and thrombosis which may on rare occasions result in cerebral infarction and sometimes even grave neurological complications like hemiparesis or hemiplegia. If the toothbrush or other foreign body which is reported to have caused the injury is not visible, it would be preferable to advise a CT examination, preferably with a 3D reconstruction to check proximity of the tooth brush or other foreign body to the vital structures like the carotid artery as careless or casual removal of the toothbrush or other foreign body in such cases, may result in fatal bleeding. If vascular injury is suspected, CT angiography would be preferable before attempting to remove the foreign body. Careful dissection & removal of the toothbrush or other foreign body under general anaesthesia or sedation will be required along with ligation of the carotid artery to avoid bleeding during retrieval of the toothbrush or the foreign body. Casual removal of any intraoral foreign body especially when soft tissue penetration is suspected must never be done before completely investigating the case.

Conclusion

Careful supervision of small children, mentally retarded patients and epileptics should be done during brushing of their teeth. Caretakers must be sensitized to the possibility of danger of trauma to the oropharynx especially with devices such as powered toothbrushes often used in such facilities. Powered toothbrush manufacturers must ideally place a warning on toothbrush packaging of the need for careful usage of the devices.⁽⁷⁾

References

1. Hefflin B J, Gross T P, Schroeder T J. Estimates of medical device-associated adverse events from emergency departments. *Am J Prev Med* 2004;27:246-253.
2. Younessi O J, Alcaino E A. Impalement injuries of the oral cavity in children: a case report and survey of literature. *Int J Paediatr Dent* 2007;17:66-71.
3. S. Kumar et al. Severe oropharyngeal trauma caused by toothbrush –case report and review of 13 cases. *British Dental Journal* 2008;205:443-447
4. Sidhu M K, Shaw D W W, Roberts T S. Carotid artery injury and delayed cerebral infarction after minor pharyngeal trauma. *AJR Am J Roentgenol* 1996;167:1056.
5. D'Souza W J, O'Brien T J, Murphy M et al. Tooth brushing- induced epilepsy with structural lesions in the primary somatosensory area. *Neurology* 2007;68:769-771.
6. Sasaki T, Toriumi S, Asakage T et al. The toothbrush: a rare but potentially life-threatening cause of penetrating oropharyngeal trauma in children.
7. Law R C, Fouque C A, Waddell A, Cusick E. Lesson of the week. Penetrating intra-oral trauma in children. *Br Med J* 1997;314:50-51.