

Intraventricular Hemorrhage induced hydrocephalus: Does EVD Help

Shashivadhanan^{1,*}, Chinmay Srivastav², Manish Garg³

^{1,2,3}Dept. of Neurosurgery, Army Hospital Research & Referral,

***Corresponding Author:**
Email: chinmayas4@gmail.com

Abstract

Keywords: Intraventricular Haemorrhage, Hydrocephalus, External Ventricular Drainage

Introduction

The incidence of Intra Cerebral Hemorrhage (ICH) is increasing nationwide, correlating with an aging and vasculopathic population coupled with widespread use of anticoagulant and antiplatelet medications.⁽¹⁾ ICH accounts for 10-15% of all strokes out of these 40% develop Intraventricular Hemorrhage. Presence of IVH worsens the short and long term outcomes.⁽²⁾ Current data indicate that hydrocephalus, communicating or non-communicating, develops in up to 67% of patients with intraventricular extension of ICH.^(3,4)

Hydrocephalus itself may contribute to increased mortality following IVH.⁽⁵⁾ Hydrocephalus can be used as an independent predictor of higher mortality^(4,5) and worse prognosis.⁽⁶⁾ Both immediate and delayed hydrocephalus are possible following IVH.⁽⁷⁾ In the recent years various interventional techniques have been used to treat IVH with Hydrocephalus. In spite of better monitoring and interventional methods, the long term outcomes remain poor and often leads to death. While it is well recognized that placement of an EVD may be a lifesaving intervention, the benefits can be offset by procedural and catheter-related complications, such as hemorrhage along the catheter tract, catheter malposition, and CSF infection. Despite their widespread use, there are a lack of high-quality data regarding the best methods for placement and management of EVDs to minimize these risks.⁽⁸⁾ In most centers, EVD use remains at the discretion of the treating neurosurgeon while further decisions on medical and surgical treatment are guided by clinical-decision making tools such as the ICH score.^(9,10,11)

The pathophysiology of IVH induced damage and inflammatory cascade are not clearly understood. A better understanding of the how and why of IVH can guide clinician to identify targets for intervention, and also provide clues to monitoring IVH associated hydrocephalus and neuronal damage.

In this review we have analyzed the outcomes of patients with IVH induced hydrocephalus in a single institute over a period of three years. A comparison of our findings has been made with that of the existing world literature. We have also attempted to reconcile the present research findings and come up with a unified theory of pathophysiology of IVH induced hydrocephalus. It is hoped that with a better

understanding of pathophysiology, we can bring about better intervention and monitoring strategies which can ultimately help not only in improving the short and long term outcomes but also improve the overall prognosis of this dreaded subset of Intra cerebral Hemorrhage.

Intraventricular hemorrhage (IVH) is characterized by an influx of blood into the ventricles of the brain. It has a highly morbid prognosis. Post Traumatic Hydrocephalus following Decompressive Craniectomy (DC) for Severe Head Injury is one of the most frequent complication during the first month following DC with incidence ranging from 4 to 30%. The cause is attributed to CSF circulatory dysfunction.⁽¹²⁾

Materials and Method

Indication for the insertion of an EVD was determined by a constellation of 1 or more of the following signs or symptoms: occlusive hydrocephalus, presence of IVH, severe mass effect, Glasgow coma scale (GCS) 8, need for continuous ICP monitoring for an unreliable neurologic exam, or, for administration of intraventricular thrombolytics. The decision to place an EVD was based on the presumed benefit to the patient if survival was likely (typically in patients with ICH scores of 3). Placement of an EVD in patients with "poor prognosis" ICH scores (4 or 5) was up to the discretion of the treating neurosurgeon after discussion of risks, benefits, and possible complications of the procedure with the family. All EVDs were inserted at the Kocher point into the frontal horn of the right lateral ventricle, unless it was obliterated by the hematoma, in which case a left frontal EVD was placed.

CSF was monitored every other day for infection by removing 2 -3 mL of fluid from the patient and sending for culture. Weaning of the EVD took place after the following patient conditions were met: improved neurologic exam without the need for ICP monitoring or, normal ICP after at least 48 hours of monitoring without concomitant IVH, serial non contrasted CT scans showing clearance of intraventricular blood, or resolution of ICH with relief of mass effect on the obstruction of CSF at the level of the foramen of Monro, cerebral aqueduct, or fourth ventricle. EVD height was raised progressively to a maximum height of 20 cm above the external acoustic

meatus and then clamped for 24 hours. If patients tolerated the clamping without progressive headache, decline in neurologic exam, and sustained ICPs 20 for 24 hours, a confirmatory CT scan was obtained to prove ventricular stability and then removed. For patients in whom EVD weaning and removal was not possible, a ventriculoperitoneal shunt (VPS) was placed.

Observation

A total of 37 cases were included in this study. The cases were placed into four groups based on the etiology of bleed. They were grouped as Hypertensive,⁽¹⁴⁾ Aneurysmal,⁽¹⁰⁾ Traumatic⁽⁶⁾ and Indeterminate,⁽⁷⁾ (Bleed where etiology could not be

determined based on imaging findings). This distribution is given in Chart 1. Majority of cases required Neurosurgical intervention within 48 hours of presentation. They were further categorized based on the severity of IVH as mild, moderate or severe (Table 1, Chart 2). The Hypertensive group had maximum cases in the severe IVH Score Group. The outcomes were analyzed on the basis of Glasgow Outcome score (GOS) from I to V. Here majority fell in the last two categories (Chart 3). Outcomes were further analyzed on basis of etiological categories (Chart 4).

The imaging findings were analyzed and abnormalities in addition to IVH were noted and put into 6 categories (Table 2).

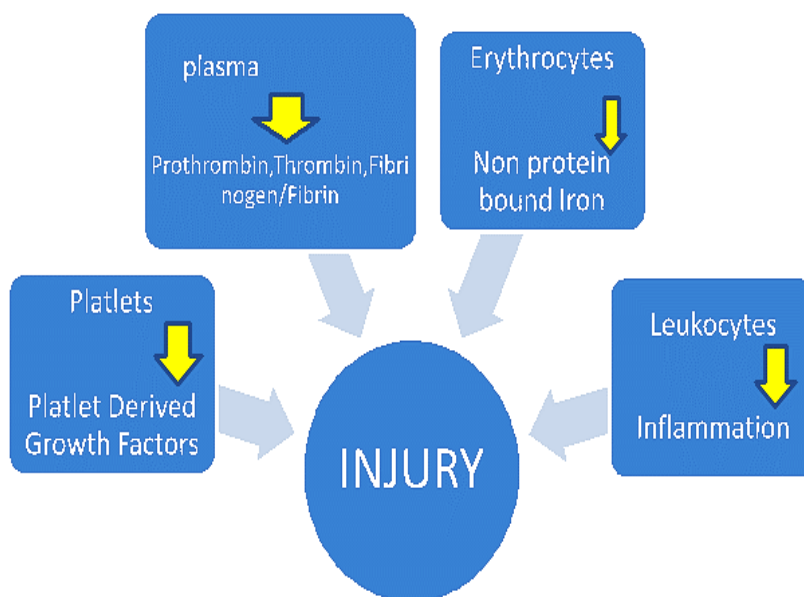


Fig. 1: Schematic Diagram showing the various mechanisms by which Blood and its components cause injury to the neural structures which serve as a trigger to Inflammation and subsequent Hydrocephalus

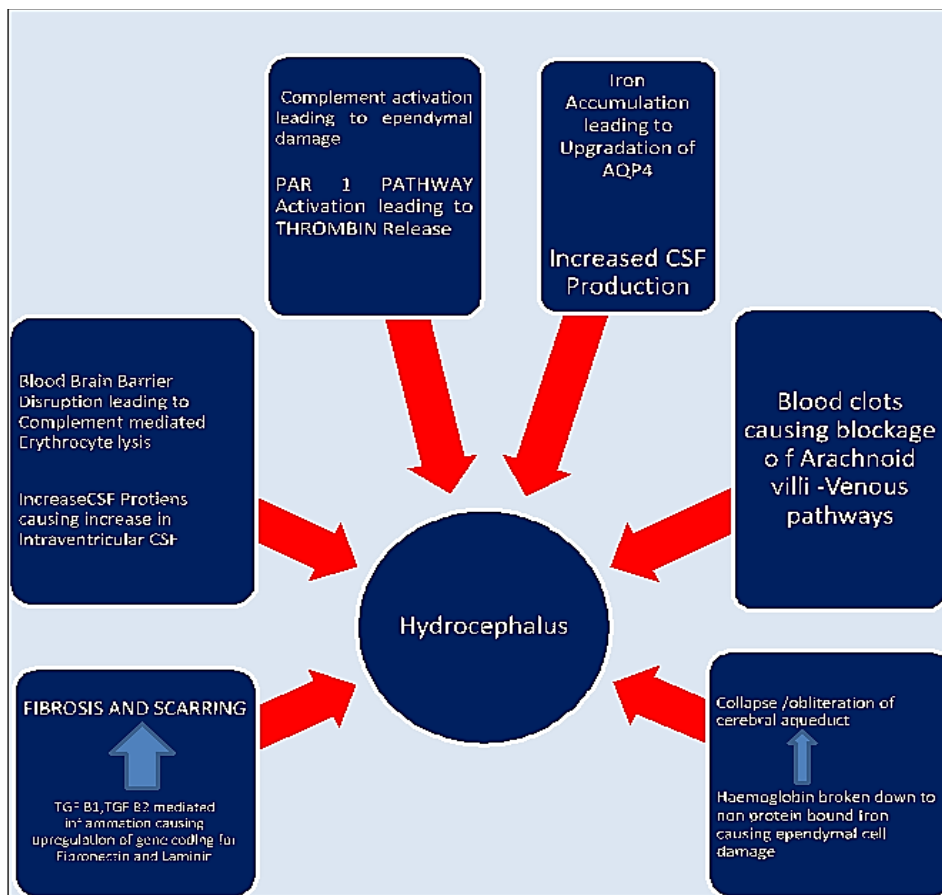
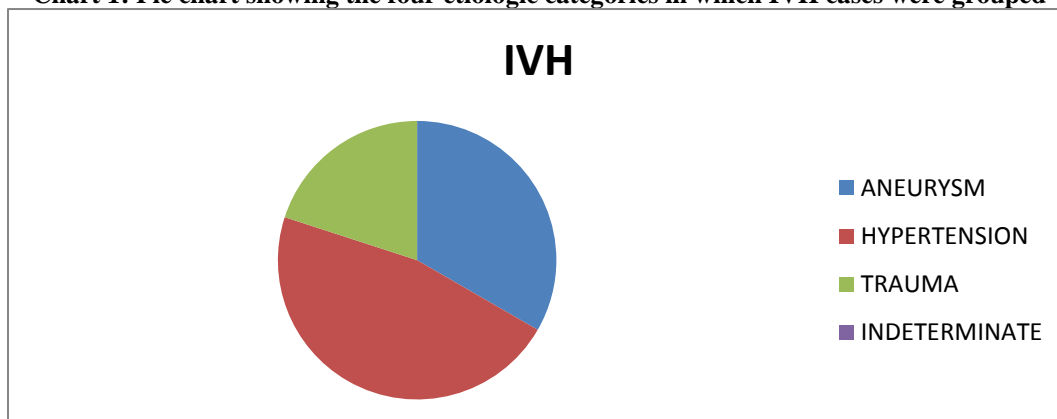


Fig. 2: Schematic diagram showing various pathophysiological mechanisms following Intra Ventricular hemorrhage leading to development of Hydrocephalus

Table 1: Additional imaging abnormalities in IVH

Abnormality	No of Cases	Percentage in %
Parenchymal Hemorrhage	26	70
Subdural Hemorrhage	04	10
Ischemic Infarct	03	8
Sub Arachnoid Hemorrhage	34	92
Midline Shift	34	92
None	02	5

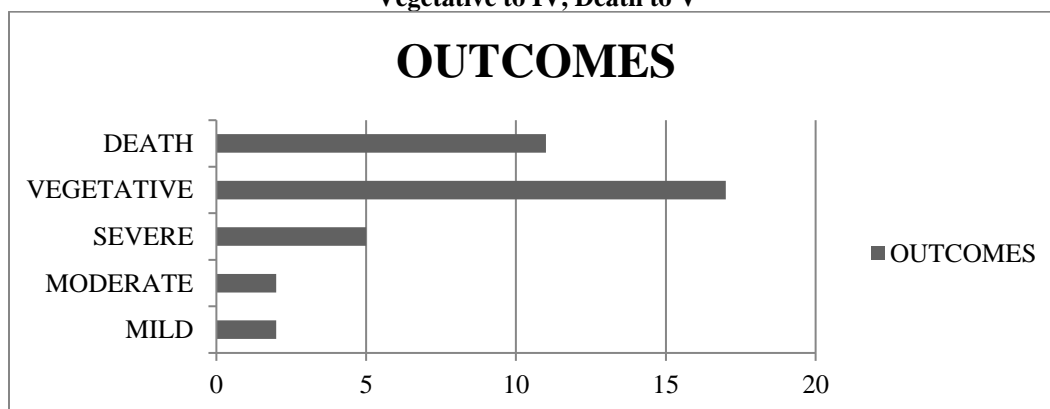
Chart 1: Pie chart showing the four etiologic categories in which IVH cases were grouped



System for grading severity of IVH

Lateral Ventricles Score:	
1	= trace of blood or mild bleeding
2	= less than half of the ventricle filled with blood
3	= more than half of the ventricle filled with blood
4	= ventricle filled with blood and expanded (Each lateral ventricle is scored separately)
Third and Fourth Ventricles Score:	
1	= blood present, ventricle size normal
2	= ventricle filled with blood and expanded
Total Score (maximum 12)	
1-4 is called mild, 5-8 moderate, and 9-12 severe.	

Chart 3: Glasgow outcome following EVD. Mild disability corresponds to I, Moderate to II, Severe to III, Vegetative to IV, Death to V



Result

Our results showed that most of the patients who were considered for EVD were in poor neurological grade and intervention did not improve the outcomes very significantly. Patients who were deteriorating benefited with EVD in the short term but outcomes remained poor. Of the 37 cases operated with EVD 12 (32%) developed hemorrhage along EVD tract and 10 (27%) developed features of CSF infection requiring intraventricular antibiotic administration. 4 (10%) developed blockage of EVD requiring reinsertion of fresh EVD.

Discussion

EVD is an effective interventional modality in the armamentarium of the Neurosurgeon to rapidly reduce life threatening mass effect. It may translate to reduction in morbidity but the outcomes continue to remain poor. The reason lies in the fact that the pathophysiology of IVH induced hydrocephalus and neural damage remains to be poorly understood. We reviewed the current body of literature and have come up with the following mechanisms of secondary injury.

Pathophysiology of IVH induced Secondary Injury:

Hydrocephalus occurs because of increased production, inappropriate flow or decreased reabsorption of CSF. Barrier-impairment mechanisms leading to hydrocephalus, including dysfunctional ependymal cells, blood-brain barrier (BBB) and the relevant molecular structures. The Volume of bleed and various blood components initiate an inflammatory response which is implicated in ependymal and BBB Dysfunction

Mechanical mechanism: Both immediate and delayed hydrocephalus are possible following IVH⁽¹⁾ Blood-clot frequently block cerebral aqueduct or fourth ventricular outlet. In case cortical subarachnoid space is blocked then tetra ventricular hydrocephalus ensues.⁽⁷⁾ In the acute onset hydrocephalus, multiple small blood clots form throughout the ventricular system, and obstruct the pathway through the arachnoid villi into the venous sinuses and small blood vessels leading to and from the ependymal cells.⁽¹³⁾ The quantity of blood clot, duration of bleed are contributory factor to the acuteness and intensity of hydrocephalus.⁽¹⁴⁾ Acute hydrocephalus occurs in one-quarter of Non Aneurysmal –Sub Arachnoid Hemorrhage patients. The greater risk in

diffuse bleeding appears to be mediated by greater cisternal blood volume but not by greater ventriculomegaly. Imaging characteristics may aid in anticipatory management of hydrocephalus in NA-SAH.⁽¹⁵⁾

Stretching of ventricular ependymal lining causes damage to ependymal cell by triggering the cellular cascade. Disruption of the ependymal surface (cells and their cilia) results in collapse of the cerebral aqueduct walls or in aqueductal stenosis and CSF flow occlusion.⁽⁷⁾

Blood components unleash a secondary response following release of injury mediators.

After hemorrhage and hemolysis, hemoglobin is released into the extracellular space and subsequently exhibits cytotoxic effects, depleting nitric oxide levels and increasing the inflammatory response.⁽¹⁶⁾ Gram et al. showed that intraventricular hemoglobin induces a pro-inflammatory response characterized by increased cerebrospinal fluid (CSF) levels of the pro-inflammatory cytokine tumor necrosis factor- α (TNF- α), as well as by periventricular brain damage.^(17,18) There is considerable evidence that hemoglobin and hemoglobin degradation products play an important role in the pathogenesis of hydrocephalus and brain injury following IVH. While much of the effort to target this process therapeutically has focused on iron chelation, Gram et al. suggested injecting the scavenger protein haptoglobin as a way to reduce the effects of free hemoglobin.⁽¹⁹⁾

Patients with ICH are affected by concomitant tissue infarction and increased intracranial pressure (ICP) from hemorrhagic mass effect, which negatively impacts neurologic outcomes. Intraventricular hemorrhage (IVH) is present in approximately 40% of patients with ICH and is associated with worse short- and long-term outcomes.^(19,20) Lovasik and colleagues found that EVD use was significantly associated with a lower mortality rate in patients with higher ICH volume, lower GCS, and ICH score of 4, as well as trends towards lower mortality with IVH and/or greater modified Graeb score.⁽²¹⁾ EVD utilization can be of benefit in a carefully selected sub-group of patients.

Patients who would otherwise expire without EVD placement are instead surviving, but with greater modified Rankin Score, in both, short and long-term.

Within the IVH literature, indications for EVD use is compelling: Nieuwkamp et al. demonstrate a 26% decrease in IVH mortality associated with EVD utilization (78% vs. 58%) through a meta-analysis, but no difference in functional outcomes (poor outcomes 90% vs. 89%).⁽²²⁾

Nieuwkamp et al.'s findings are consistent with the results of the analysis done by, Brendan P. Lovasik and colleagues who also demonstrated trends toward positive mortality benefit without overall positive functional outcomes benefit.⁽²³⁾

Herrick et al. described a mortality benefit towards EVD use for primary IVH patients with GCS greater than 3 and hydrocephalus.⁽²⁴⁾ Hwang et al. demonstrated an association between EVD use and more dismal clinical prognosis, but EVD placement had no significant influence on patient outcomes; the authors attributed the trends in greater mortality and lower functional status to worse prognosis at presentation rather than treatment effect.⁽²⁵⁾

Prasad et al. 37 demonstrated through a large meta-analysis that there may be benefit to surgery in ICH, with a 26% risk reduction for mortality and 29% risk reduction for poor outcome (functional dependence or death).⁽²⁶⁾ However, no individual trial has shown this benefit and study heterogeneity limits further extrapolation of these meta-analytic results.^(27,28,29,30)

The breakdown of blood into protein free iron is considered to one of the main instigating mechanism triggering the cascade.⁽³¹⁾

Ependymal cells lining the ventricles may get damaged due to inflammation,⁽³²⁾ or raised intracranial pressure.⁽³³⁾

IVH leads to failure regulating the transfer of fluid, ions and small molecules between the cerebral parenchyma and the ventricular fluid, due to injury causing dysfunction of the ependymal cells.

BBB also is important for maintaining the CSF protein content and the osmotic pressure in the brain.

AQP4 Takeuchi and colleagues hypothesized that Aquaporin, AQP4, is up regulated in response to iron accumulation in the periventricular area to mediate hydrocephalus after IVH because AQP4 expression was shown to correlate with iron concentration in that model, and AQP4 up regulation was inhibited by the iron chelator, deferoxamine.⁽³⁴⁾

Fibrosis & Scarring After acute obstructive hydrocephalus, inflammation and subsequent scarring of the arachnoid granulations are major contributors to the secondary reaction, in which the flow of CSF through the cerebral aqueduct, fourth ventricular outlets, basal cisterns and/or arachnoid granulations, is prevented, resulting in communicating hydrocephalus.⁽³⁵⁾

Complement activation may also play a role in hydrocephalus. However, only when the BBB is disrupted or blood extension into the ventricular system occurs, are components of the complement system (beneficial or detrimental) allowed to pass into the ventricular system and possibly induce immune reaction in the brain parenchyma, including cell lysis and inflammation, leading to hydrocephalus.^(36,37)

Inflammation following IVH is mediated also by the transforming growth factor (TGF) family members, TGF β 1 and TGF β 2, which are among the most abundant and functionally versatile cytokines in the mammalian central nervous system (CNS).⁽³⁸⁾ TGF β 1 induces upregulation of the cognate genes encoding extracellular matrix proteins, such as fibronectin and

laminin, which are important mediators of wound healing and scar formation.⁽³⁹⁾

The major roles of TGFβ2 are scarring and fibrosis.^(40,41)

Heme is degraded in the brain by hemoxygenase (HO) into iron, carbon monoxide and biliverdin, the latter of which is subsequently converted to bilirubin by biliverdin reductase. Normal ependymal cells take up iron from the CSF and prevent iron diffusion to the rest of the brain.⁽⁶⁾ Thus, destruction of ependymal cells following IVH may be one of the causes for increased non-protein-bound iron—which is cytotoxic—in the CSF, and in turn may increase ependymal cell damage and exacerbate patients' conditions.

The role of free iron in IVH-induced hydrocephalus may be tightly linked to the inflammatory response. Complement-mediated erythrocyte lysis may expose the CSF and brain to the damaging effects of free iron ions.^(6,42,43)

Mediation of thrombin's effect through the PAR-1 pathway is an important contributor to hydrocephalus development after IVH. Thrombin-induced hydrocephalus was reduced by co-injection of the protease-activated receptor 1 (PAR-1) antagonist SCH79797. Based on these results, we concluded that mediation of thrombin's effect through the PAR-1 pathway is an important contributor to hydrocephalus development after IVH.⁽⁴⁴⁾

Conclusion

Our study demonstrates that EVD placement in HCP reduces mortality in patients with higher ICH Volumes, lower GCS and ICH Score of 4. There is no improvement in morbidity. World literature supports our results. The current body of evidence suggests that early evacuation of IVH will help in reducing the secondary effects of injury thereby reducing the morbidity. Larger multi institutional studies incorporating evidence based protocols may help in improving patient outcomes.

Conflict of Interest

None to Disclose

References

1. Van Asch CJ, Luitse MJ, Rinkel GJ, van der Tweel I, Algra A, Klijn CJ. Incidence, case fatality, and functional outcome of intracerebral haemorrhage over time, according to age, sex, and ethnic origin: a systematic review and meta-analysis. *Lancet Neurol*. 2010;9:167-176.
2. Ruiz-Sandoval JL, Chiquete E, Romero-Vargas S, Padilla-Martinez JJ, Gonzalez-Cornejo S. Grading scale for prediction of outcome in primary intracerebral hemorrhages. *Stroke*. 2007;38:1641-1644.
3. Hemphill JC, Bonovich DC, Besmertis L, et al. The ICH score: a simple, reliable grading scale for intracerebral hemorrhage. *Stroke* 2001;32:891-7.
4. Diringer MN, Edwards DF, Zazulia AR. Hydrocephalus: a previously unrecognized predictor of poor outcome from supratentorial intracerebral hemorrhage. *Stroke* 1998;29:1352-7.
5. Bhattathiri PS, Gregson B, Prasad KS, et al. Intraventricular hemorrhage and hydrocephalus after spontaneous intracerebral hemorrhage: results from the STICH trial. *Acta Neurochir Suppl* 2006;96:65-8.
6. Stein M, Luecke M, Preuss M, et al. Spontaneous intracerebral hemorrhage with ventricular extension and the grading of obstructive hydrocephalus: the prediction of outcome of a special life-threatening entity. *Neurosurgery* 2010;67:1243-51; discussion 52
7. Strahle J, Garton HJ, Maher CO, et al. Mechanisms of hydrocephalus after neonatal and adult intraventricular hemorrhage. *Transl Stroke Res* 2012;3(Suppl 1):25-38.
8. Fried HI, Nathan BR, Rowe AS, Zabramski JM et al. The Insertion and Management of External Ventricular Drains: An Evidence-Based Consensus Statement: A Statement for Healthcare Professionals from the Neurocritical Care Society. *Neurocrit Care*. 2016 Feb;24(1):61-81. doi: 10.1007/s12028-015-0224-8.
9. Cheung RT, Zou LY. Use of the original, modified, or new intracerebral hemorrhage score to predict mortality and morbidity after intracerebral hemorrhage. *Stroke*. 2003;34:1717-1722.
10. Clarke JL, Johnston SC, Farrant M, Bernstein R, Tong D, Hemphill JC 3rd. External validation of the ICH score. *Neurocritical Care*. 2004;1:53-60.
11. Hemphill JC 3rd, Bonovich DC, Besmertis L, Manley GT, Johnston SC. The ICH score: a simple, reliable grading scale for intracerebral hemorrhage. *Stroke*. 2001;32:891-897.
12. Xiaofeng Yang, Liang Wen. Surgical complications secondary to decompressive craniectomy for patients with severe head trauma. *Translational Neuroscience and Clinics*. Vol. 2, No. 1, March 2016, pp 59-64.
13. Whitelaw A, Intraventricular haemorrhage and posthaemorrhagic hydrocephalus: pathogenesis, prevention and future interventions. *Semin Neonatol* 2001;6:135-46.
14. Hanley D, Naff N, Harris D.. Intraventricular hemorrhage: presentation and management options. *Semin Cerebrovasc Dis Stroke* 2005;5:209-16.
15. Peter Kang, Amanda Raya, Gregory J. Zipfel, Rajat Dhar, Factors Associated with Acute and Chronic Hydrocephalus in Nonaneurysmal Subarachnoid Hemorrhage. *Neurocritical Care* (2016)24, 1 104-109.
16. Xiong XY, Wang J, Qian ZM, Yang QW. Iron and intracerebral hemorrhage: from mechanism to translation. *Transl Stroke Res*. 2014;5(4):429-41.
17. Gram M, Sveinsdottir S, Cinthio M, Sveinsdottir K, Hansson SR, Morgelin M, et al. Extracellular hemoglobin—mediator of inflammation and cell death in the choroid plexus following preterm intraventricular hemorrhage. *J Neuroinflammation*. 2014;11:200.
18. Gram M, Sveinsdottir S, Ruscher K, Hansson SR, Cinthio M, Akerstrom B, et al. Hemoglobin induces inflammation after preterm intraventricular hemorrhage by methemoglobin formation. *J Neuroinflammation*. 2013;10:100..
19. Morgan TC, Dawson J, Spengler D, Lees KR, Aldrich C, Mishra NK, et al. The Modified Graeb Score: an enhanced tool for intraventricular hemorrhage measurement and prediction of functional outcome. *Stroke*. 2013;44:635-641.
20. Tuhim S, Dambrosia JM, Price TR, Mohr JP, Wolf PA, Hier DB, et al. Intracerebral hemorrhage: external validation and extension of a model for prediction of 30-day survival. *Ann Neurol*. 1991;29:658-663.

21. Brendan P. Lovasik, D. Jay McCracken, Courtney E, McCracken. et al. The Effect of External Ventricular Drain Use in Intracerebral Hemorrhage. *World Neurosurgery*, Oct 2016, 94: 309-318.
22. Nieuwkamp DJ, de Gans K, Rinkel GJ, Algra A. Treatment and outcome of severe intraventricular extension in patients with subarachnoid or intracerebral hemorrhage: a systematic review of the literature. *J Neurol*. 2000;247:117-121.
23. Brendan P. Lovasik, D. Jay McCracken , Courtney E, McCracken. et al. The Effect of External Ventricular Drain Use in Intracerebral Hemorrhage. *World Neurosurgery*, Oct 2016, 94: 309-318.
24. Herrick DB, Ullman N, Nekoovaght-Tak S, Hanley DF, Awad I, LeDroux S, et al. Determinants of external ventricular drain placement and associated outcomes in patients with spontaneous intraventricular hemorrhage. *Neurocritical Care*. 2014;21:426-434
25. Hwang BY, Bruce SS, Appelboom G, Piazza MA, Carpenter AM, Gigante PR, et al. Evaluation of intraventricular hemorrhage assessment methods for predicting outcome following intracerebral hemorrhage. *J Neurosurg*. 2012;116: 185-192.
26. Prasad K, Mendelow AD, Gregson B. Surgery for primary supratentorial intracerebral haemorrhage. *Cochrane Database Syst Rev.*. 2008;(4):CD000200.
27. Mendelow AD, Gregson BA, Fernandes HM, Murray GD, Teasdale GM, Hope DT, et al. Early surgery versus initial conservative treatment in patients with spontaneous supratentorial intracerebral haematomas in the International Surgical Trial in Intracerebral Haemorrhage (STICH): a randomised trial. *Lancet*. 2005;365:387-397.
28. Gregson BA, Broderick JP, Auer LM, Batjer H, Chen XC, Juvela S, et al. Individual patient data subgroup meta-analysis of surgery for spontaneous supratentorial intracerebral hemorrhage. *Stroke*. 2012;43:1496-1504.
29. Mendelow AD, Gregson BA, Rowan EN, Murray GD, Gholkar A, Mitchell PM. STICH II Investigators. Early surgery versus initial conservative treatment in patients with spontaneous supratentorial lobar intracerebral haematomas (STICH II): a randomised trial. *Lancet*. 2013;382: 397-408.
30. Morgenstern LB, Hemphill JC 3rd, Anderson C, Becker K, Broderick JP, Connolly ES Jr, et al. Guidelines for the management of spontaneous intracerebral hemorrhage: a guideline for health care professionals from the American Heart Association/American Stroke Association. *Stroke*. 2010;41:2108-2129.
31. Thomas Garton, Richard F Keep. Andrew Wilkinson et al. Intraventricular Hemorrhage: the Role of Blood Components in Secondary Injury and Hydrocephalus. *Transl. Stroke Res, Commentary, Article June 2006*.
32. Pang D, Sclabassi RJ, Horton JA.. Lysis of intraventricular blood clot with urokinase in a canine model: part 3. Effects of intraventricular urokinase on clot lysis and posthemorrhagic hydrocephalus. *Neurosurgery* 1986;19:553-72.
33. Simard PF, Tosun C, Melnichenko L, et al. Inflammation of the choroid plexus and ependymal layer of the ventricle following intraventricular hemorrhage. *Transl Stroke Res* 2011;2:227-31.
34. Takeuchi S, Nawashiro H. Letter by Takeuchi and Nawashiro regarding article, "Role of iron in brain injury after intraventricular hemorrhage". *Stroke* 2011;42:e378.
35. Hill A, Shackelford GD, Volpe JJ,. A potential mechanism of pathogenesis for early posthemorrhagic hydrocephalus in the premature newborn. *Pediatrics* 1984;73:19-21.
36. Mukherjee P, Pasinetti GM. The role of complement anaphylatoxin C5a in neurodegeneration: implications in Alzheimer's disease. *J Neuroimmunol* 2000;105:124-30.
37. Xi G, Keep RF, Hoff JT. Mechanisms of brain injury after intracerebral haemorrhage. *Lancet Neurol* 2006;5:53-63.
38. Kaestner S, Dimitriou I. TGF beta1 and TGF beta2 and their role in posthemorrhagic hydrocephalus following SAH and IVH. *J Neurol Surg A Cent Eur Neurosurg* 2013;74:279-84.
39. Whitelaw A, Thoresen M, Pople I. Posthaemorrhagic ventricular dilatation. *Arch Dis Child Fetal Neonatal Ed* 2002;86:F72-4.
40. Logan A, Frautschy SA, Gonzalez AM, et al.. Enhanced expression of transforming growth factor beta 1 in the rat brain after a localized cerebral injury. *Brain Res* 1992;587:216-25.
41. Logan A, Green J, Hunter A, et al.. Inhibition of glial scarring in the injured rat brain by a recombinant human monoclonal antibody to transforming growth factor-beta2. *Eur J Neurosci* 1999;11:2367-74.
42. Hua Y, Xi G, Keep RF, et al.. Complement activation in the brain after experimental intracerebral hemorrhage. *J Neurosurg* 2000;92:1016-22.
43. Xi G, Hua Y, Keep RF, et al. Systemic complement depletion diminishes perihematomal brain edema in rats. *Stroke* 2001;32:162-7.
44. Gao F, Liu F, Chen Z, et al. Hydrocephalus after intraventricular hemorrhage: the role of thrombin. *J Cereb Blood Flow Metab* 2014;34:489-94.