

Short clinical communications

Uday N. Soni^{1,*}, S. Dash², Ashwini Jethliya³, Shashank Mishra⁴, N.G. Toshniwal⁵

^{1,2}PG Student, ⁵Professor & HOD, Dept. of Orthodontics & Dentofacial Orthopedics, Rural Dental College, Pravara Institute of Medical Sciences, Loni, Maharashtra, ³Private Practitioner, Kaij, Beed, ⁴Private Practitioner, Bilaspur

***Corresponding Author:**

Email: udaysoni88@rediffmail.com

Abstract

Orthodontic management of a lingually blocked-out lower premolar requires a substantial amount of bodily movement which is difficult to perform because of its position of crown and root. Uprighting of premolar using lingual arches as source of anchorage unit and piggy back wire create discomfort to patient and increased work load of orthodontist as well as the cost of the treatment. So it was necessary to design a new mechanics to solve all the problems and make treatment easy, efficient as well as quick.

Keywords: Lingual premolar, Uprighting, Cost effective

Introduction

Orthodontic management of a lingually blocked-out lower premolar requires a substantial amount of bodily movement which is difficult to perform because of its position of crown and root. Even when orthodontic forces are applied in a desired direction, large hyalinised areas are created which impede the root movement. In order to produce efficient premolar movement, very light orthodontic forces are required. This can be achieved by either sectional wire with frictionless mechanics or frictional mechanics by differential bonding of the teeth during alignment stage.

Uprighting of premolar using lingual arches as source of anchorage unit and piggy back wire create discomfort to patient and increased work load of orthodontist as well as the cost of the treatment. So it was necessary to design a new mechanics to solve all the problems and make treatment easy, efficient as well as quick.

Case Report

A 22 years old female patient reported in Dept. of Orthodontics and Dentofacial Orthopedics, Rural Dental College, Loni, presenting with severe crowding and bilaterally lingually blocked out second premolar. (Fig. 1)

The treatment plan decided was extraction of 14, 24, 35, 44, crowding unravelling and space closure. 35 was extracted because there was a good contact between 34 and 36 while 44 was extracted because there was no good contact between 44 and 46 and the second thing was the size of 45 was proper to get accommodated in the space after extraction of 44 after extraction uprighting of 45 was planned.

clinical pearl:- Uprighting was not done with conventional mechanics using lingual arch and piggy back wire as the premolar was present very much deep in the lingual vestibule so it is difficult to place lingual

arch. Uprighting was planned with E-chain (from molar to lingual of premolar to canine) and open coil niti coil spring (between the canine and molar on 0.019x0.025 SS wire) to counter balance the forces of E-chain i.e. mesial force on molar and distal force on canine. lingual button was bonded on premolar to have good engagement of E-chain (Fig. 2) premolar was uprighted within 3 appointments and then finishing and detailing was done. The post treatment results are shown in Fig. 3.

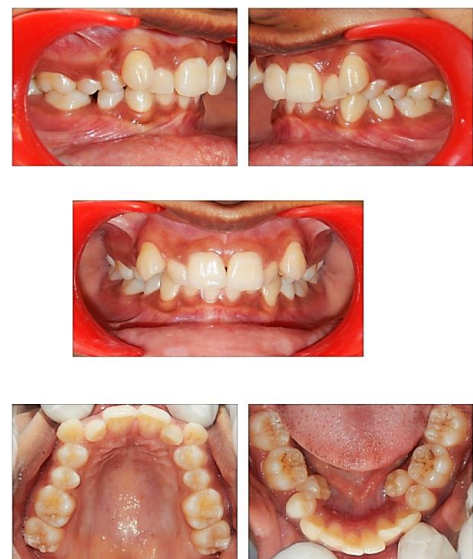

Fig. 1: Pre-treatment intraoral photographs

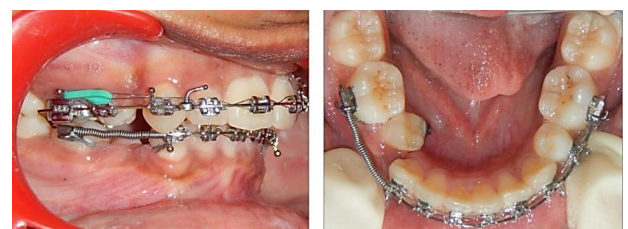


Fig. 2: Premolar uprighting

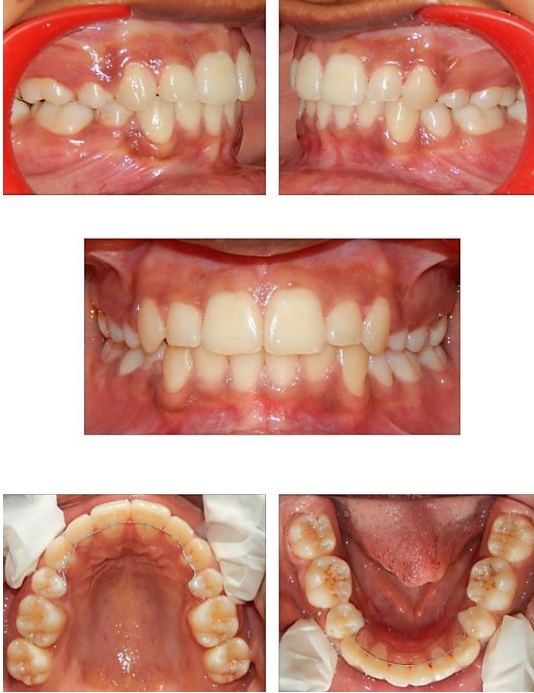

Fig. 3: Post treatment intraoral photographs

Financial support and sponsorship: Nil.

Conflicts of interest: There are no conflicts of interest.