

Unilateral pulmonary hypoplasia with bullous lung disease a rare case report

Nanda Kishore K.S.¹, Yuvarajan S², Gangi Reddy T.K.³, Suresh S.⁴

^{1,2,3}Dept. of Pulmonary Medicine, Sri Manakula Vinayagar Medical College & Hospital, Puducherry

***Corresponding Author:**

Email: nsivagnanane@yahoo.com

Abstract

In many patients with hypoplasia of lung etiology is not known. Conditions that decrease intrathoracic space like congenital diaphragmatic hernia may cause unilateral lung hypoplasia and may also be associated with ipsilateral congenital vascular anomalies. Here we are presenting a rare case of left lung hypoplasia with rudimentary bronchus with bulla in an adult which was not associated with any other developmental anomaly.

Keywords: Hypoplasia; Rudimentary bronchus; Pulmonary hypoplasia

Introduction

The term hypoplastic lung indicates underdevelopment of lung which contains rudimentary bronchial system attached to a reduced amount of alveolar tissue. True prevalence is not known. Unilateral agenesis is much less rare and left lung is affected more. In most common form of unilateral agenesis there is a rudimentary bronchus but complete absence of lung tissue. Bilateral pulmonary hypoplasia is associated with the presence of oligohydramnios, an important cause is premature rupture of membranes [1].

Case Report

A 47 years old male chronic smoker, presented with complaints of breathlessness of Grade 2, and left sided

dull aching chest pain from 2 months, no H/O fever, loss of appetite and weight loss with no past H/O pulmonary TB. General physical examination was non contributory, respiratory examination revealed smaller left hemithorax, examination showed diminished movements, reduced breath sounds in left hemithorax, Other systemic examination were normal.

Routine hematological investigations (Blood counts, Liver function tests, renal function tests) were within normal limits. Sputum for AFB was negative, 2D echo was normal. Spirometry showed restriction with very severe obstruction, bronchoscopy showed sabersheath trachea, left main bronchus of 1.5cm length having blind end. Since the patient was asymptomatic advised for bronchodilators and pneumococcal vaccination.

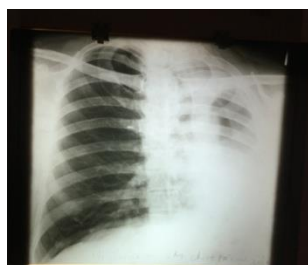

Fig. 1a: Chest x ray showed homogenous opacity left hemithorax with silhouetting of left heart border and left hemidiaphragm with herniation of lung to the left side

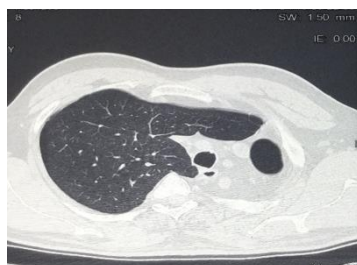

Fig. 1b

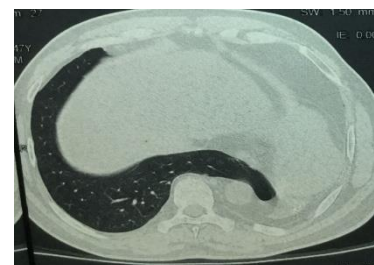


Fig. 1c

Fig. 1b, c: CT showed complete collapse of left lung with compensatory emphysema of right lung with transmediastinal herniation and bulla

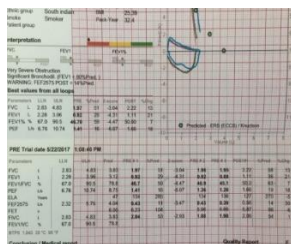


Fig. 2a: Spirometry showed restriction with very severe obstruction

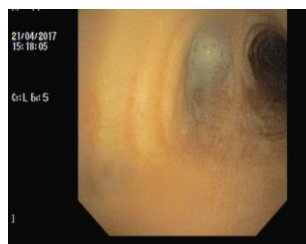


Fig. 2b

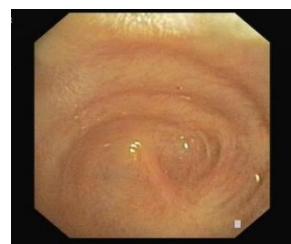

Fig. 2c

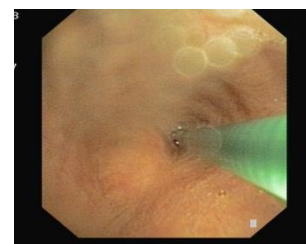

Fig. 2d

Fig. 2b, c, d: Bronchoscopy showed sabersheath trachea, left main bronchus of 1.5cm length having blind end

Discussion

Hypoplasia of lung is a rare congenital anomaly in which there is decrease in number or size of the airways, vessels and alveoli. Underdevelopment of alveolar tissue results in small fibrotic and nonfunctioning lung. Development of bronchial tree takes place at about 26th to 31st day of intrauterine life. Monaldi divided maldevelopment of lung into 4 groups:-

Group 1: No bifurcation of trachea

Group 2: Only rudimentary main bronchus

Group 3: Incomplete development after division of main bronchus

Group 4: Incomplete development of subsegmental bronchi and small segment of corresponding lobe. Hypoplasia of the lung may be regarded as primary or secondary.

The incidence of primary hypoplasia has been estimated to be 1 to 2 per 12000 births. Boyden classified mal-development in to 3 degrees: (i) agenesis, in which there is complete absence of lung tissue, (ii) aplasia, in which rudimentary bronchus is present but no lung tissue is present, and (iii) hypoplasia, in which all the normal pulmonary tissues are present but are under-developed.

This condition is frequently associated with other congenital anomalies [2] like urinary system, diaphragm, tetralogy of fallot [3], anencephaly, hydrocephaly, musculoskeletal anomalies of thoracic cage, Klippel Feil syndrome and Down syndrome. Hypoplastic lungs are typically smaller and weigh less than normally expected for their age, most consistent finding is decrease in number of airway generation ranging from about 50-75% of normal. Treatment is in the form of medical and surgical care both before and after delivery. Treatment of hypoplasia is in the form of medical as well as surgical care, both before and after delivery, before delivery patient is treated medically when repeated amniotomies with or without the use of tocolytics, antibiotics and steroids. After delivery includes oxygen therapy often ventilator support is required [4]. Individuals with aplasia and hypoplasia may present with recurrent infection, dyspnea and reduced exercise capacity, and there may be pooling of bronchial secretions, with secondary infection [5].

Treatment in adults consists of control of recurrent infections, symptomatic treatment in the form of expectorants, bronchodilators and management of

complications. Prophylaxis for RSV, pneumococcal, influenza infections are recommended.

Conclusions

Hypoplasia of lung is a rare congenital anomaly, Hypoplasia presenting in adulthood is a rare entity. The appearance resembles atelectasis. Bronchoscopy, CT scan and occasionally pulmonary angiography may be required for confirmation of diagnosis.

Conflicts of interest: None declared

Acknowledgements: None

References

1. Suzuki K. Respiratory characteristics of infants with pulmonary hypoplasia syndrome following preterm rupture of membranes: a preliminary study for establishing clinical diagnostic criteria. *Early Human Development*. 2004;79:31-40.
2. Page DV, Stocker JT. Anomalies associated with pulmonary hypoplasia. *Am Rev Resp Dis*. 1982;125:216.
3. Johnson RJ, Howorth SG. Pulmonary vascular and alveolar development in Tetralogy of Fallot: A recommendation for early correction. *Thorax*. 1982;37:893-901.
4. Natrajan G, Abdulhamid I. Pulmonary hypoplasia. Available from URL: http://www.emedicine.com/ped/topic_2627.htm. Last accessed 2017 on July 23.
5. Collin P. Development of the thorax. In: Standring S, editor., eds. *Gray's anatomy*. 40th edn Philadelphia, PA: Elsevier Publisher, 2008:1013-36.