

Study of tumours of uterus and cervix with special emphasis on endometrial stromal sarcoma

Neerja Shah¹, Nisha Raval^{2,*}, Jayesh Joshi³, Ashok Agnihotri⁴

¹Tutor, GMERS Medical College, Ahmedabad, Gujarat, ²Associate Professor, ³Senior Professor, ⁴Professor & HOD, Dept. of Pathology, CU Shah Medical College, Surendranagar, Gujarat

***Corresponding Author:**

Email: ttanu29@gmail.com

Abstract

Introduction: Tumours of uterus and cervix are extremely common lesions encountered in our routine histopathology practice. However, a few entities like endometrial stromal tumours pose diagnostic challenges. With this study, an attempt has been made to broadly categorize the tumours of uterus and cervix and at the same time look into occurrence of rare lesion like endometrial stromal sarcoma.

Materials and Method: Total 2400 hysterectomy specimens received at histopathology section of department of pathology, C U Shah medical college, Surendranagar were studied in a 3 year period from August 2013 to July 2016. A brief clinical history of patient was taken into account. All histopathological details like size, shape, presence of masses, etc were noted and extensive sampling of specimen was done.

Result: Total 2400 cases were studied, of which 648 (27%) specimens were neoplastic. Of them, 635 (98%) cases were benign & constituted exclusively of leiomyomas. Amongst 13 malignant lesions, 03 (23%) cases were of endometrial stromal sarcoma, 06 cases were of endometrial carcinoma and 04 cases of cervical carcinoma.

Conclusion: As expected, leiomyomas turn out to be most common neoplasms of uterus and cervix. Though rare, certain lesions like endometrial stromal sarcoma do come across in histopathology and such lesions being known for poor prognosis and recurrences are important to be correctly and timely diagnosed.

Keywords: Tumours of uterus & cervix, Endometrial stromal sarcoma

Introduction

Tumours of uterus and cervix constitute a major portion of tumours of female genital tract. Most common invasive carcinoma of female genital tract is endometrial carcinoma which accounts for 7% of all invasive cancers in women, excluding skin cancer.⁽¹⁾ The most common age group for malignancy of uterus and cervix is perimenopausal. Majority cases of endometrial malignancies present with postmenopausal bleeding making it easy to diagnose timely and cure promptly. On the other hand, cervical carcinomas tend to occur in a reproductive age group as well as in postmenopausal women. However, with advent of Pap smear, the trend of cervical malignancies is reducing gradually. Uterine sarcomas, rarer than carcinoma, constitute 1% of malignancies of female genital tract and about 5% of total uterine malignancies.^(2,3) They are aggressive in nature and are classified broadly into leiomyosarcoma, endometrial stromal sarcomas and undifferentiated sarcomas.⁽⁴⁾ Carcinosarcoma though originally classified under sarcomas of uterus, is now reclassified as dedifferentiated or metaplastic form of endometrial carcinoma.⁽⁵⁾

A rare variant of endometrial tumours, endometrial stromal sarcomas, also called formerly as endolymphatic stromal myosis,⁽⁶⁾ constitutes about 10% of total sarcomas of uterus and around 0.2% of all malignant lesions of uterus.^(7,8) Because of significant difference in disease outcome, a few years back endometrial stromal sarcomas were further divided into

low grade and high grade based on mitotic count (low grade: <10 mitoses/10 hpf; high grade =>10 mitoses/10 hpf).^(9,10) However, now these tumours are classified as endometrial stromal nodule, low grade endometrial stromal sarcoma and undifferentiated endometrial sarcoma.⁽²⁾ The natural history of endometrial stromal sarcoma is characterized by slow clinical progression, repeated local recurrences (in the pelvis, ovary, intestinal wall, other intra-abdominal sites, and anterior abdominal wall), and occasional metastases.⁽¹¹⁾ The five year survival rate of endometrial stromal sarcomas is about 50%.⁽¹²⁾ It is characterized by a recurrent chromosomal translocation, t(7;17)(p15;q21) which causes fusion of two genes, *JAZF1* and *JJAZ1*, thus producing a fusion transcript which has anti-apoptotic properties.⁽¹³⁾

The most common neoplasms of uterus are leiomyomas. Their overall incidence is around 4% to 11% but rises to more than 40% in women over 50 years of age.⁽¹⁴⁾

The most common histological subtype of cervical carcinoma is squamous cell carcinoma accounting for 80% of cases. Other variants include adenocarcinoma (15%), adenosquamous carcinoma & neuroendocrine carcinoma; all of them being caused by highly oncogenic HPV viruses.⁽¹⁵⁾

Materials and Method

Total 2400 cases were included in present study which was carried out at department of pathology, C U

Shah medical college, Surendranagar, Gujarat spanning a period of 3 years. All hysterectomy specimens received during the same period were included in the study. Demographic data of patients were also noted and brief notes of clinical history were taken. The samples were fixed in 10% formalin and were examined grossly taking note of size, colour, consistency, presence of masses, and other relevant details. After routine histopathology processing, sections were prepared, stained with haematoxyline and eosin and examined under microscope. After final reporting, the data were compiled and sorted using Microsoft excel.

Result

Out of total 2400 cases include in study, 648 cases (27%) were neoplastic.

Of 648 neoplastic cases, 635 cases were benign (98%) and 13 cases were malignant (2%). The benign cases constituted exclusively of leiomyomas.

Amongst 13 malignant lesions, 03 cases (23%) cases were of endometrial stromal sarcoma and rest 10 cases (76%) included 06 cases of endometrial carcinoma and 04 cases of cervical carcinoma.

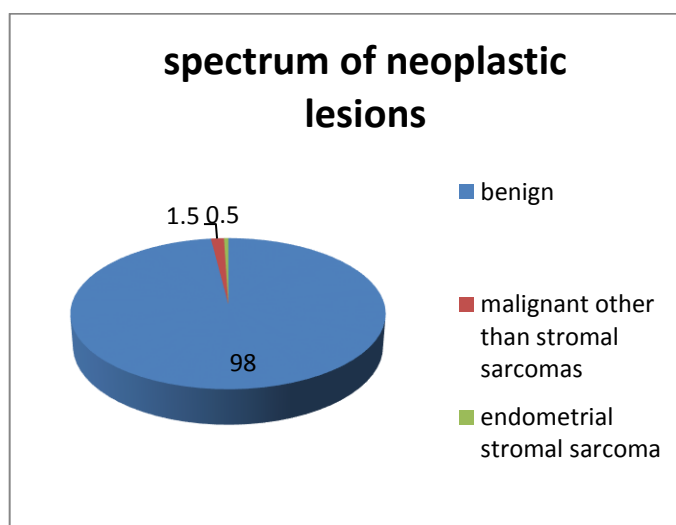


Fig. 1: Distribution of neoplastic lesions

Fig. 1 shows overall spectrum of neoplastic lesions which comprises of 98% cases of leiomyoma, 0.5% cases of endometrial stromal sarcoma and 1.5% cases of malignant lesions other than stromal sarcoma.

The age group most commonly involved by leiomyoma was 36-55 yrs (56.5% cases of all cases of leiomyoma); that for endometrial carcinoma was 46-55 yrs (50% cases of all cases of endometrial carcinoma); that for cervical carcinoma was 36-45 yrs (50% cases of all cases of cervical carcinoma); and that for endometrial stromal sarcoma was 46-55 yrs (66.7% cases of all cases of endometrial stromal sarcoma). Thus, it is evident that all lesions are mostly common around perimenopausal age group.

Endometrial stromal sarcomas present grossly as yellowish, soft, nodules in the body of uterus as seen in Fig. 2. Microscopically, they consist of bland small oval to spindle endometrial stromal cells that are arranged around arterioles as seen in Fig. 3.

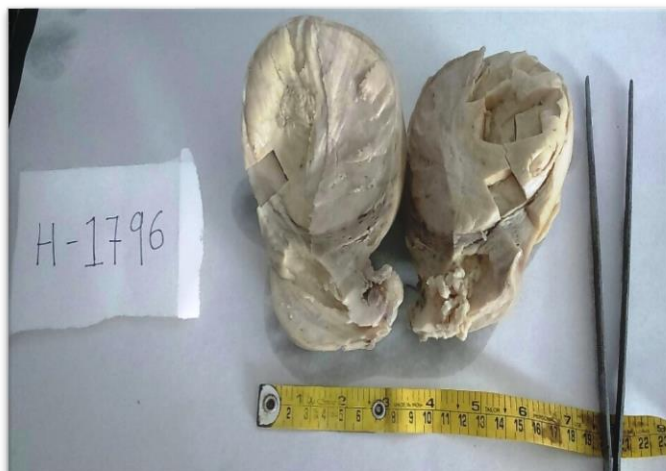


Fig. 2: Gross appearance of endometrial stromal sarcoma

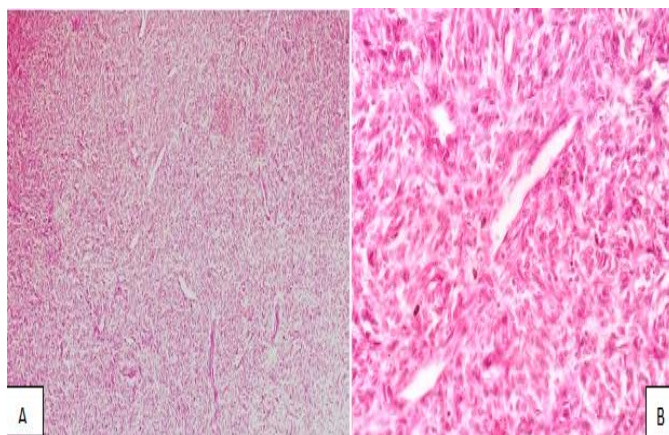


Fig. 3: Microscopic appearance of endometrial stromal SARCOMA (H&E, A:100X; B:600X)

Discussion

Present study is compared with other study done by Gupta et al in which total 400 hysterectomy specimens were studied of which 246 cases (61.25%) were neoplastic.⁽¹⁶⁾ Of 246 neoplastic cases, 226 cases were benign and 20 cases were malignant. Specific distribution is as in Table 1.

Table 1: Comparison of spectrum of neoplastic lesions

No. Cases of Lesion (%)	Ankur Gupta et al ⁽¹⁶⁾	Present Study
Benign	226 (91.8)	635 (98)
Endometrial Stromal Sarcoma	01 (0.4)	03 (0.5)
Malignant other than Stromal Sarcoma	19 (7.8)	10 (1.5)

Thus, it is evident that incidence of endometrial stromal sarcoma remains to be around 0.4-0.5% of total uterine tumours in various studies.

In present study, of all uterine lesions, incidence of leiomyoma was highest (26.5%). This is comparable

with study by Henry Annan et al⁽¹⁷⁾ in which incidence of leiomyoma ranged from 5.4-77% and also with Gravin F Jacobson et al⁽¹⁸⁾ in which incidence of the same was reported to be in range of 5-80%. It also correlated with study by Vijay Domblae et al⁽¹⁹⁾ who reported incidence of leiomyoma to be 21.8% in their study.

The age range of endometrial stromal sarcoma was compared with study by Tahereh Ashraf-Ganjoei et al.⁽⁷⁾ They reported average age of 44.35 ± 6 years, which correlates well with present study.

Conclusion

Tumours of uterus-cervix have varied hues ranging from benign leiomyomas, often discovered incidentally, to carcinosarcomas & undifferentiated sarcomas that are notorious for recurrence, metastases and poor prognosis. With this study attempt has been made to emphasize importance of diagnosing rare lesions like endometrial stromal sarcomas correctly to offer best possible treatment to patients. The study attempts to point that these lesions though rare are at times encountered in routine histopathology practice.

Hysterectomies, though extremely common surgeries in our country, lead to significant physical and mental burden to the patient. Missing such lesions on histopathology analysis simply adds to agony of patients.

References

1. Robbin's & Cotran: Pathological basis of disease: 8e; Elsevier,2009. pg:1031.
2. D'angelo e, Prat J; uterine sarcomas: A review; Gynecol Oncol(2009), doi:10.1016/j.ygyno.2009.09.023.
3. Major fj, blessing ja, silverberg sg, et al. Prognostic factors in early stage uterine Sarcoma: a gynecologic oncology group study. Cancer 1993;71:1702-9.
4. Giuntoli ii RL, Metzinger DS, Dimarco CS, Cha SS, Sloan JA, Keeney GL, et al. Retrospective review of 208 patients with leiomyosarcoma of the uterus: Prognostic indicators, surgical management, and adjuvant therapy. Gynecol Oncol 2003;89:460-9.
5. World health organization classification of tumours. In: tavassoli fa, Devilee p, Editors. Pathology and genetics of tumours of the breast and female genital organs. Lyon: IARC press; 2003.
6. Rosai and Ackerman's surgical pathology: 10e, Italy, Elsevier, 2011, vol2, ch19, pg1501.
7. Tahereh Ashraf-Ganjoei, Nadereh Behtash, Mamak Shariat, Asamosadat Mosavi. Low grade endometrial stromal sarcoma of uterine corpus, a clinicopathological and survey study in 14 cases. World J Surg Oncol. 2006; 4: 50.
8. Boardman CH, Webb MJ, Jefferies JA. Low-grade endometrial stromal sarcoma of the ectocervix after therapy for breast cancer. Gynecologic oncology. 2000;79:120-123.
9. Rosai and Ackerman's surgical pathology: 10e, Italy, Elsevier, 2011, vol2, ch19, pg1502.
10. Norris HJ, Taylor HB: Mesenchymal tumors of the uterus. A clinical and pathological study of 53 endometrial stromal tumors. Cancer 1966; 19:755-766.
11. Abrams J, Talcott J, Corson JM: Pulmonary metastases in patients with low-grade endometrial stromal sarcoma. Clinicopathologic findings with immunohistochemical characterization. Am J Surg Pathol 1989; 13:133-140.
12. Robbin's & Cotran: Pathological basis of disease: 8e; Elsevier,2009. pg:1036.
13. Li H, et al: Gene fusion and RNA trans-splicing in normal and neoplastic cells. Cell Cycle 2009; 8:218.
14. Rosai and Ackerman's surgical pathology: 10e, Italy, Elsevier,2011, vol2, ch19, pg1508.
15. Robbin's & Cotran: Pathological basis of disease: 8e; Elsevier,2009.pg:1021.
16. Ankur Gupta, Sangita Sehgal, Ajay Yadav, Vinod Kumar. Histopathological spectrum of uterus and cervix in hysterectomy specimens. Int J Med Res Prof.2016; 2(3); 136-39.
17. Henry Annan et al. Myomectomy: uterus saving surgery for fibroids. Obstet Gynaec Today 2005; 10(8): p456-58.
18. Jacobson GF, Shaber RE, Armstrong MA, et al. Changes in rates of hysterectomy and uterine conserving procedures for treatment of uterine leiomyoma. Am J Obstet Gynaecol 2007; 196(6): p601.e1601.e6.
19. Vijay Domblae MD, Shivanand Gundalli MD, Sonali. Histopathological Analysis of Uterine Lesions in Hysterectomy Specimens. International Journal of Science and Research (IJSR); vol4, iss5. May2015.