

## Rhinosporidiosis- A retrospection

Shubha P Bhat<sup>1,\*</sup>, Sajitha K<sup>2</sup>, Jayaprakash Shetty K<sup>3</sup>

<sup>1</sup>Associate Professor, <sup>2</sup>Assistant Professor, <sup>3</sup>Professor and Vice Dean, Dept. of Pathology, K.S Hegde Medical Academy (Nitte-Deemed to be University), Mangalore, Karnataka, India

\*Corresponding Author: Shubha P Bhat

Email: bhatshubha\_257@rediffmail.com

Received: 29<sup>th</sup> March, 2018

Accepted: 28<sup>th</sup> June, 2018

### Abstract

Rhinosporidiosis is a chronic granulomatous disease caused by *Rhinosporidium seeberi*. It is endemic in the coastal region of India where agriculture is the most common occupation. It grows in stagnant water and transepithelial spread is the common mode of infection especially in the nose and nasopharynx. Patients present with reddish granular, polypoidal mass in the nose. Surgical excision with cauterization of the base is the treatment of choice. Recurrence is common even after meticulous clearance of the disease. This is a retrospective study done in a tertiary care hospital in Mangalore, India. The case records of histopathologically confirmed cases of rhinosporidiosis, during 10 years period between January 2007 and December 2016, were studied. Demographic profile, symptoms, site of involvement, treatment done, follow up and recurrence during follow up were noted and analysed. Out of the 34 patients, 31 (91.17%) were males and 3 (8.82%) were females. All were agriculturists. Commonest age group is 3<sup>rd</sup> and 6<sup>th</sup> decade. Bathing in pond water was the common source of infection. Nasal obstruction was the most common symptom. The most frequent site of occurrence is nasal cavity, with inferior turbinate being preferred site. Out of the 34 cases, 22 (64.70%) were recurrent cases with past history of surgery. Out of the 34 patients treated in our centre, no recurrence was seen in newly diagnosed cases during the study period, whereas 2 of the recurrent cases came with recurrence.

**Keywords:** Rhinosporidiosis, Surgical treatment, Recurrence.

### Introduction

Rhinosporidiosis is a chronic granulomatous disease caused by *Rhinosporidium seeberi*, well known for over hundred years. Earlier, it was proposed to be a fungus by Guillermo Seeber from Argentina in 1900. Later it was isolated by Ashworth in 1923, who described the lifecycle of the organism and established the nomenclature.<sup>1</sup> Molecular studies have supported its phylogenetic relationship with protozoa, and is now classified as an aquatic protistan parasite of Mesomycetozoa.<sup>2</sup>

Although sporadic cases have been reported from all over the world, more than 90% of cases are reported from India, Sri Lanka and Pakistan. In India, it is endemic in coastal areas of Orissa, Tamilnadu, Kerala, Karnataka and Pondicherry states.<sup>3</sup> Mode of infection from the natural aquatic habitat of *R.seeberi* is through the traumatized epithelium most commonly in nasal sites. Mode of local spread in the upper respiratory sites is by auto-inoculation while hematogenous spread occurs to distant sites.<sup>4,6</sup> Males are commonly affected although there is no racial predilection.<sup>7,8</sup> Four common varieties have been described: nasal, ocular, cutaneous and disseminated. Nasal lesions are more common and is usually seen on the inferior turbinates, septum and floor of nasal cavity.<sup>8</sup> Other mucosal sites include nasopharynx, larynx, soft palate, uvula, trachea, bronchi, ear, external urethral meatus, rectum and vagina.<sup>5,9</sup> Cutaneous lesions are very rare, and generally associated with simultaneous or with past history of mucosal lesions.<sup>2</sup> About 15% of cases are ocular involving bulbar and palpebral conjunctiva and lacrimal

apparatus. Dissemination (also known as malignant rhinosporidiosis) to the limbs, trunk and viscera has been described with a rare fatality when the brain was involved.<sup>6,10</sup>

In the nasal rhinosporidiosis, patients usually present with nasal obstruction and epistaxis. On examination, typical lesions are polypoidal, granular and red in colour due to the vascularity. The surface contains yellowish pin head sized spots representing underlying mature sporangia. Nasopharyngeal lesions are often multilobed with variegated and strawberry like appearance while occasionally they have smooth surface with minimum vascularity. Skin lesions appear as sessile or pedunculated masses resembling verrucous wart, while ulcerated growths mimic sarcoma and carcinoma.<sup>11-13</sup> Treatment is surgical resection and cauterization of the base. Dapsone is given as an adjuvant to surgical treatment to prevent recurrence.<sup>11,14</sup> Definitive diagnosis is by histopathology which show many round, thick walled sporangia in the submucosa containing sporangiospores.<sup>4</sup>

### Objectives of the Study

1. To study the cases of rhinosporidiosis with respect to age, sex, symptoms and site of involvement.
2. To study the recurrent cases of rhinosporidiosis and modes of management in recurrent cases.

### Materials and Methods

This is a retrospective study done in a tertiary care hospital in Mangalore, India. The case records of histopathologically confirmed cases of rhinosporidiosis,

during 10 years period between January 2007 and December 2016 were retrieved. Details about the demographic profile, presenting complaints, personal habits, site of the lesion, investigations done, treatment done were recorded and analysed. Follow up details and recurrent cases were also noted.

## Results

We studied the case records of 34 cases of histopathologically proven rhinosporidiosis. Of these 34 patients, 31 (91.17%) were males and 3(8.82%) were females, with a male to female ratio of 10.3:1. Majority of patients were adults, common age group being between 21-30 years and 51-60 years (23.52%) followed by 41-50 years (20.58%) and 31-40 years (14.7%). There were 2 cases each (5.88%) in the age group of 11-20 years, 61-70 years and 71-80 years. Youngest patient was an 11 year old male and oldest was 75 year old male. Of the 3 females in this study, one each were in the 3<sup>rd</sup>, 4<sup>th</sup> and 5<sup>th</sup> decade of life. All patients in this study were from the coastal districts of Kerala state. All the patients were agriculturists, and all had history of bathing in ponds, rivers or reservoirs.

Nasal obstruction was the most common presenting complaint (34.42%), followed by visible nasal mass, mass in the throat (9.8% each) and bleeding from nose (8.19%). Other symptoms included headache and multiple skin nodules (6.55% each), difficulty in swallowing, change of voice and swelling in the inner aspect of eye (4.91% each), nasal discharge (3.27%), snoring and disturbed sleep, foreign body sensation in the throat, loss of smell and mass in the eye (1.63% each). Out of the 34 patients, 22 (64.70%) were recurrent cases with past history of surgery.

Most common site of rhinosporidiosis was nose (Table 1). Only nasal lesions were seen in 19 patients (55.9%) (Fig. 1). Nasal & nasopharyngeal lesions were seen in 5 patients (14.7%). Nasal and lacrimal sac lesions (Fig. 2) were seen in 2 patients (5.88%). One patient had Nasal, Nasopharyngeal and oropharyngeal lesions. Two patients had only nasopharyngeal lesions (5.88%). Overall, out of 34 patients, 27 had nasal lesions, and 9 had nasopharyngeal lesions. One of the patients had isolated conjunctival lesions (Fig. 3). Disseminated lesions involving the skin were seen in 4 patients (11.76%).

In the nasal cavity, majority were located in inferior turbinate (41.17%), followed by floor of the nose (27.45%) and septum (13.72%). Bilateral nasal cavity involvement was seen in 4 cases. Out of the 4 disseminated cases having cutaneous lesions (Fig. 4) over face, arm and the legs, 3 patients had nose as primary involvement and 1 case in nasopharynx. All these 4 patients were recurrent cases with past history of surgery for rhinosporidiosis with time duration ranging from 6 years to 18 years.

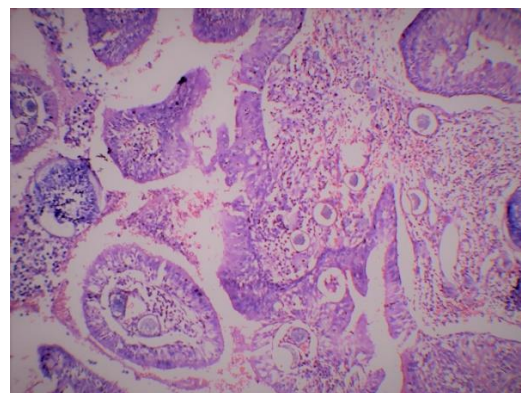
All the patients in the study were treated surgically with the aid of nasal endoscopes. After excision of the

lesion, base was cauterized with bipolar diathermy. Cutaneous lesions excised locally.

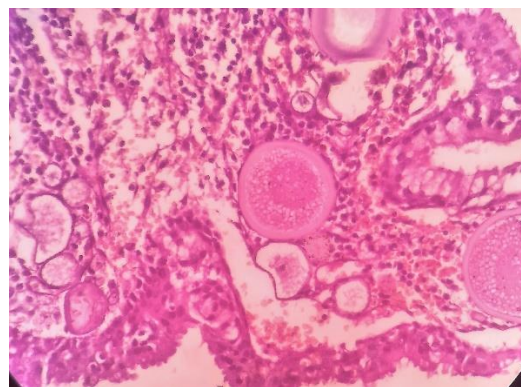
Histopathological examination of the excised specimen was done in all patients. Histopathology showed thick walled sporangia in the submucosa varying from 10-200mm in size containing sporangiospores with varying stages of development. Stroma showed lymphoplasmacytic infiltrate and congested capillaries. Foreign body giant cell reaction to ruptured sporangia and neutrophils were also noted in few cases (Fig. 5). Recurrent cases showed more dense acute and chronic inflammatory cells in a highly vascularised stroma compared to new cases.

All disseminated cases were treated with tab Dapsone 100 mg daily for the periods ranging from 3 months to 6 months following surgery.

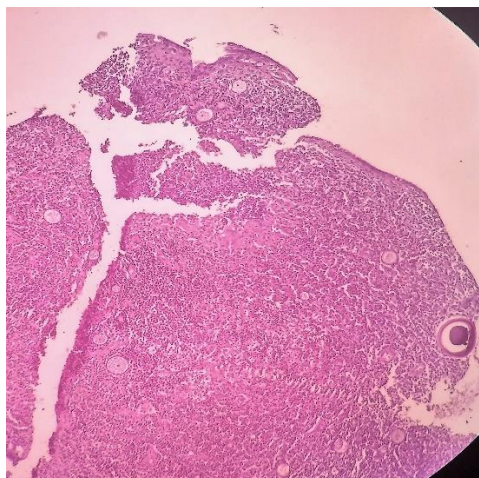
Mean follow up period was 7.5 months, with average 4 visits. Nasal endoscopic examination was performed during the follow up period. All new cases (12) did not show any signs of recurrence during the follow up period. Out of the 22 recurrent cases, 2 cases came with recurrence in the nasal cavity, one after 7 months and other after 11 months post-surgery, which were managed endoscope assisted surgery.



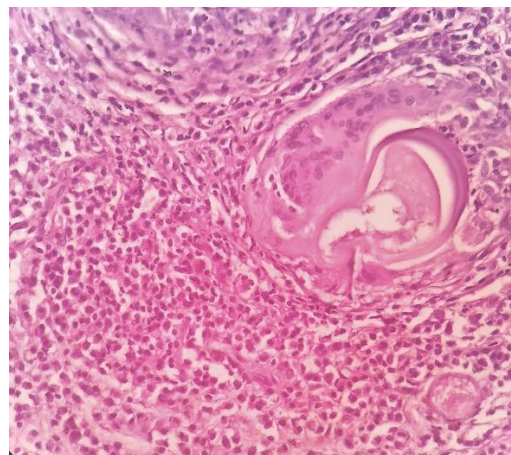
**Fig. 1: Nasal rhinosporidiosis showing polypoidal tissue lined by pseudo stratified ciliated columnar epithelium with squamous metaplasia, H&E, 10x**



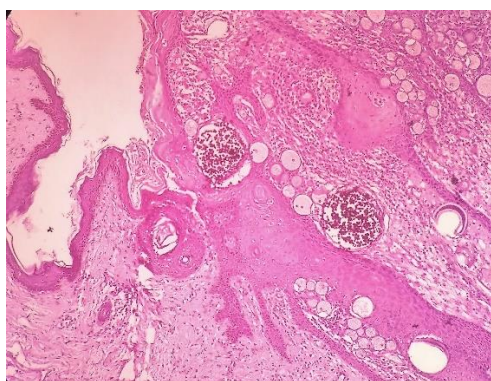
**Fig. 2: Rhinosporidiosis of lacrimal sac showing stratified columnar epithelium containing goblet cells, H&E, 40x**



**Fig. 3:** Conjunctival rhinosporidiosis showing non keratinised stratified squamous epithelium, H&E, 4x



**Fig. 5:** Sporangia surrounded by foreign body giant cells and dense lymphoplasmacytic infiltrate. H&E, 40x



**Fig. 4:** Cutaneous rhinosporidiosis showing keratinised stratified squamous epithelium and subepithelial tissue with sporangia, H&E, 10x

**Table 1:** Anatomic site involved in rhinosporidiosis

Anatomical Sites	No. of patients (N=34)	Percentage (%)
Nasal	19	55.9
Nasal + Nasopharyngeal	5	14.7
Nasopharynx	2	5.88
Disseminated	4	11.76
Nasal +Nasopharngel+ Oropharyngeal	1	2.94
Nasal+ lacrimal	2	5.88
Conjunctiva	1	2.94

## Discussion

Rhinosporidiosis is an uncommon chronic granulomatous disease caused by *Rhinosporidium seeberi*. The taxonomy has been debated in the last decades since the microorganism is intractable to isolation and microbial culture. Most microbiologists initially considered it as a fungus owing to the property to be stained by fungal stains such as Gomori Methenamine Silver (GMS) and Periodic Acid Schiff (PAS).<sup>4</sup> A portion of the *R.seeberi* 18S rRNA gene was amplified using PCR which suggested that it belonged to a group of fish parasites referred to as DRIP

(Dermocystidium, rosette agent, Ichthyophonus, Psorospermium) clade.<sup>2,4</sup> In addition to human infection, rhinosporidiosis has also been documented in farm, domestic and wild animals. The disease is prevalent in rural settings, particularly in people working or in contact with contaminated soil, stagnant water like ponds and lakes. A curious feature in the incidence of the disease is that while several hundreds of them bathe in stagnant water, only a few develop the disease. This suggests the pre-existing obscure host factors like nonspecific immune response, blood group and HLA types.<sup>4,6</sup>

It usually grows in hot tropical climates and hence been hyperendemic in Srilanka and Southern India. This disease has been reported from about 70 countries including Europe, North and South America, Brazil, Argentina, Mexico and scattered reports from Columbia, Venezuela, Uganda, Madagascar, Ghana, Iran, Russia, and South-East Asia.<sup>1,6</sup> In our study, all 34 patients were from coastal districts of Kerala state.

In our study, 31 patients (91.17%) were males and 3 (8.82%) were females. The male to female ratio was 10.3:1. Mahmud S et al from Bangladesh found that males were predominantly affected than females with a male to female ratio of 3.08: 1.<sup>8</sup> Bhandary S et al from Nepal found that rhinosporidiosis commonly affected males (63%).<sup>11</sup> In a study done by Karthikeyan P et al, from Pondicherry and Chakraborty D et al from west Bengal, male to female ratio was 1.3:1 and 1.24:1 respectively, suggesting an equal incidence in males and females.<sup>1,3</sup> The male preponderance in the present and most of the studies is probably related to more outdoor activity in agriculture in males, while females having lesser chance of animal contact and less frequent pond baths. Some authors are also of the opinion that estrogen in females may provide some protection from the disease.<sup>1,4</sup>

In the present study, the disease was more prevalent in patients between 21-30 years and 51-60 years of age (23.52% each) followed by 41-50 years (20.58%) and 31-40 years (14.7%) respectively. Of the 8 patients between 51-60 years in our study, 6 of them were recurrent cases with history going back to 10 -15 years making them fall into occupationally active age group. Karthikeyan P et al and Majumdar AB et al found that the majority of the patients were in their 3<sup>rd</sup> and 4<sup>th</sup> decade.<sup>1,14</sup> Mahmud S et al and Bhandary S et al found most of the patients in their 2<sup>nd</sup> and 3<sup>rd</sup> decade of life.<sup>8,11</sup> There was a low incidence of Rhinosporidiosis in children and older age group in our study which was similar to most of the studies.<sup>8,3</sup>

Natural habitat of *R.seeberi* is stagnant water like ponds, back waters and reservoirs and hence the river sand workers and people indulged in agricultural work who bathed in ponds where animals also bathed combined with digital microtrauma are at risk of developing rhinosporidiosis especially of upper respiratory tract and eye.<sup>9-11</sup> All of patients in our study were agriculturists and all had history of bathing in ponds, rivers or reservoirs. Similar findings were observed in Karthikeyan P, Bhandary S and Chakraborty D in their studies.<sup>1,3,11</sup>

Nasal cavity was the most common location of rhinosporidiosis in our study. Only nasal cavity lesions were seen in 19 cases (55.9%), nasal & nasopharyngeal lesions in 5 patients (14.7%) and disseminated (Nasal or nasopharyngeal with cutaneous lesions) in 4 patients (11.76%). Other sites involved are oropharynx, lacrimal apparatus and conjunctiva. Out of 34 patients 27 (79.5%) had nasal lesions, and 9 (26.5%) had

nasopharyngeal lesions. Karthikeyan P et al in their study also found nasal cavity as the commonest site (59.38%) followed by nasopharyngeal (21.88%), nasal and nasopharyngeal (15.63%) and disseminated (3.13%).<sup>1</sup> Nasal site followed by nasal & nasopharyngeal was also the commonest site of involvement recorded in a study done by Majumdar AB et al.<sup>14</sup> Within the nasal cavity, majority of the lesions were seen in inferior turbinate (41.17%) followed by floor of the nose (27.45%) and septum(13. 72%). Inferior turbinate was also the commonest site observed by Majumdar AB et al while septum was the commonest site in studies done by Karthikeyan P et al, Chakraborty D et al and Mahmud S et al.<sup>1,3,8,14</sup> Lateral nasal wall was the commonest location reported by Bhandary S et al.<sup>11</sup>

Nasal obstruction was the most common presenting complain (34.42%), followed by nasal mass (9.8%) and mass in the throat (9.8%) and bleeding from nose (8.19%). Mahmud S et al also found similar finding in their study.<sup>8</sup> Nasal obstruction followed by bleeding from the nose was the most common presenting complain in studies done by Karthikeyan P et al and Bhandary S et al.<sup>1,11</sup> Chakraborty D et al found 85.71% of patients with nasal obstruction followed by nasal mass (78.57%), nasal discharge (71.43%) and nasal bleed (32.14%) as common symptoms.

Fine needle aspiration cytology (FNAC) from the lesions or smears of secretions from the surfaces of accessible polyps can aid in early diagnosis. In the present study, FNAC was done in one patient with past history of rhinosporidiosis who presented with soft tissue swelling of the thigh. Most of the cases underwent treatment based on the clinical diagnosis, as the clinicians in this region are familiar with this disease. CT scan of the nose and paranasal sinuses was done in all the cases before surgical treatment. All patients were treated by surgical resection and cauterization of the base.<sup>6</sup>

Histopathological examination of the resected specimen will confirm the diagnosis of rhinosporidiosis. Histopathology of rhinosporidiosis shows thick walled sporangia in the submucosa varying from 10-200mm in size containing sporangiospores. Earliest stage is thin walled juvenile sporangia (15-40µm) which develop into immature, intermediate and mature sporangia, accompanied by changes in the thickness and lamination of the walls and appearance of nuclei around which cytoplasm condenses to form endospores. Several hundreds of endospores are embedded in a mucoid matrix. The mature endospores contain up to about twenty, spherical, 1-3 mm electron dense bodies, which are considered as proteinaceous nutritive reserves and precursor of trophocytes. Each mature sporangium contains an operculum or pore through which endospores are extruded. The stroma is fibro-myxomatous and contains lymphocytes and macrophages, while neutrophils are numerous around

free endospores. Granulomas composed of giant cells are also evident around ruptured sporangia. Special stains like GMS and PAS can be helpful. Differential diagnosis include subcutaneous sperulocystic disease- Myosporulosis, Adiaspiromycosis and *Coccidioides immitis*.<sup>6</sup>

Failure to propagate *R. seeberi* in vitro, with the inability to establish experimental rhinosporidiosis, has prevented the determination of drug sensitivity that might have clinical application. The only drug effective is dapsons (4, 4-diaminodiphenyl sulphone) which arrests the maturation of the sporangia and promotes fibrosis of the stroma when used as an adjunct to surgery.<sup>4,6</sup> It could therefore be expected that presurgical dapsons therapy would minimize haemorrhage and prevent colonization and infection of new sites after the release of endospores from surgically traumatized polyps by electrocautery which is the basis of recurrence. In the present study, all the patients were treated with endoscopic resection with cauterization of base. Dapsons was given for disseminated cases.

Out of the 34 patients, 22 (64.70%) were recurrent cases with past history of surgery. Out of the 22 recurrent cases treated in our institute, 2 cases (9.09%) came with recurrence; one after 7 months and other after 11 months post-surgery. These two patients had the disease at multiple sites. There was no recurrence in fresh cases during the follow up period. Karthikeyan P et al found 6.25% and Chakraborty D et al found 2.68% of recurrences in their study.<sup>1,3</sup> In a study done by Majumdar AB et al, 19.2% gave past history of surgery.<sup>14</sup> Literature suggests a residual or recurrence rate between 10 and 70% with an average incidence of 10% related to incomplete excision.<sup>3,11</sup> This indicates disseminated and extensive disease, multiple sites are challenging to treat and prone for recurrences.

Management of recurrent Rhinosporidiosis is challenging. Laser excision and use of harmonic scalpel has been tried owing to its superior haemostasis and capability of preserving the local integrity of the tissue.<sup>10,15</sup> Coblation, radiofrequency cautery, has been reported to penetrate surrounding tissues to a depth of only 100µm. As the temperature does not exceed 60°C in coblation mode, there is less lateral thermal damage as seen with cautery and laser. Also there is constant cooling due to simultaneous irrigation.<sup>10</sup> Endoscopes have greatly helped in meticulous clearance of the disease and have been effective in minimising the recurrences.<sup>16</sup>

## Conclusion

Rhinosporidiosis is a chronic granulomatous disease, affecting people living in coastal region involved in agriculture. It is commonly seen in the occupationally active age group and males are commonly affected. Transepithelial infection while bathing in stagnant waters is the common mode of infection. The most frequent site of occurrence is nasal

cavity, leading to nasal obstruction and epistaxis. Dissemination of the disease makes treatment difficult, leading to further recurrence. Treatment is meticulous surgical excision with cauterization of base. Endoscopes have improved the surgical precision, minimising the trauma to normal tissue, hence reducing recurrence. Histopathological examination should be done for confirmation. We conclude that bringing awareness among people living in “at risk” areas through public health education will remove the etiological agent at the root level, reducing the economic burden on the person and family.

## References

1. Karthikeyan P, Vijayasundaram S and Pulimootil DT. A Retrospective Epidemiological Study of Rhinosporidiosis in a Rural Tertiary Care Centre in Pondicherry. *J Clinical and Diagnostic Research*. 2016;10(5):4-8.
2. Sahu B, Sahu P and Puhan MR. Disseminated Cutaneous Rhinosporidiosis: A Polymorphic Presentation in an Immunocompetent Patient. *Indian J Dermatol*. 2015;60(2):108.
3. Chakraborty D, Das C and Hansda R. Three Year's Experience of Management of Different Types of Rhinosporidiosis in Rural Part of Western West Bengal. *Bengal J Otolaryngol Head and Neck Surg*. 2015;23(3):92-98.
4. Das S, Kashyap B, Barua M, Gupta N, Saha R, Vaid L and Banka A. Nasal rhinosporidiosis in humans: new interpretations and a review of the literature of this enigmatic disease. *Medical Mycology*. 2011;49:311-315.
5. Das LCA and Das CAK. Endoscopic Excision of Recurrent Rhinosporidiosis. *MJAFI* 2008;64:76-77.
6. Arceuleratne SN. Recent advances in Rhinosporidiosis and Rhinosporidiumseeberi. *Indian J Medical Mycology*. 2002;20(3):119-131.
7. Aliyu D and Sahabi SM. Nasal Rhinosporidiosis in a Nigerian Child: A Rare Clinical Entity. *Int J Otolaryngol Head & Neck Surg*. 2014;3:51-53.
8. Mahmud S, Haque R, Mamun AL, Alam R, Akaiduzzaman DGM, Datta UK and Alam Z. A clinicopathological study of rhinosporidiosis. *Bangladesh J Otolaryngol*. 2015;21(2):94-96.
9. Malaiyan J, Nasimuddin S, Radhakrishnan G, Munirathinam S, Kandaswamy M, Gnanadesikan S and Paramasivan SA. A Case of Recurrent Nasal Rhinosporidiosis from Chennai, South India. *Int J Science and Research*. 2014;3(7):2026-2067.
10. Khan I, Gogia S, Agarwal A and Swaroop A. Recurrent Rhinosporidiosis: Coblation Assisted Surgical Resection – A Novel Approach in Management. *Case Reports in Otolaryngology*. 2014;1-4.
11. Bhandary S, Natesh V, Chettri S and Kumar A. Rhinosporidiosis: Analysis of Cases Presenting to a Tertiary Care Hospital in Nepal. *The internet J of tropical medicine*. 2012;8(1):1-7.
12. Rehman A, Muhammad MN and Moallam FA. Rhinosporidiosis. *J College of Physicians and Surgeons Pakistan*. 2012;22(10):671-672.
13. Shenoy MM, Girisha BS, Bhandari SK and Peter R. Cutaneous rhinosporidiosis. *Indian J Dermatol Venerol Leprol*. 2007;73(3):179-181.
14. Majumdar AB, Biswas D, Paul SS, Ray S and Kumar G. Rhinosporidiosis: a clinicopathological study from a Rural Tertiary Health Care Centre, Bihar, India. *Int J Adv Med*. 2014;1(3):213-216.

15. Chery J, Bacskai C and Mendoza E. Recurrent Rhinosporidiosis. *J Med Cases*. 2014;5(2):58-61.
16. Aroor R, Gowda MM, Bhat VS, Bhandary SK. Novel Approach to rhinosporidiosis. *Otorhinolaryngology Clinics: an International journal*. 2014;6(2):55-7.

**How to cite this article:** Bhat S.P, Sajitha K, Shetty J. K. Rhinosporidiosis- A retrospection. *Indian J Pathol Oncol*. 2018;5(4):680-685.