

Metallic foreign body (Bullet) opposite to cervical vertebra (C2 and C3): A case report and review literature

Vinod Kumar^{1*}, S.K. Kanojia², H.K Gautam³

¹Senior Resident, ^{2,3}Associate Professor, Ganesh Shankar Vidyarthi Memorial Medical College, Kanpur, Uttar Pradesh, India

***Corresponding Author:**

Email: vinod86gsvm@gmail.com

Abstract

Gunshot injuries to the upper cervical region that involve the spinal cord often result in fatality. The mortality rate from gunshot injuries reach as high as 15% and complication rates up to 30%. This is a case report of gunshot injury of 50 years male. Bullet is seen in nape of neck opposite c2 and c3 vertebral body, with no any neurological deficit. The case was managed by conservative treatment (non-surgical) with primary repair of entry wound.

Keywords: Gunshot injuries, Bullet, conservative treatment.

Introduction

The most common cause of spinal cord injury is road traffic accidents, followed by gunshot injuries.^{1,2} Gunshot injuries to the upper cervical region that involve the spinal cord often result in fatality.^{3,4} the extent of the tissue damage correlates with the distance between the gun, trajectory, shape, size and the velocity of the bullet.^{3,5} Gunshot injury to the spine accounts for 13% to 17% of all spinal cord injuries annually.⁶

The mortality rate from gunshot injuries reach as high as 15% and complication rates up to 30%.⁷ significant mortality rates constitute to surgical emergencies. There is currently very little information available about the management of these injuries, with conservative treatment (non-surgical) being recommended in most publications.

Case Report

In our case report a 50 years old male patient presented in emergency and admitted to our side as a case of gunshot injury.

On Examination

Patient was stable, well oriented to time, place and person. A small (approx 1cm) skin defect is seen on left side of submandibular region which is an entry point of bullet. There was no exit point of bullet is seen. There was no any neurological deficit seen and not any major blood vessel involved. Only surgical emphysema is seen in this region.

CT reveals a radio-opaque metallic cylindrical foreign body is seen in nape of neck opposite c2 and c3 vertebral body. Strong metallic artifacts are seen originating from the foreign body (bullet). It is reaching up to muscular layer, surgical emphysema is seen in this region. Cervical spine show moderate osteophytosis and minimal straightening of cervical spine.

Discussion

There are few absolute indications for the removal of a bullet lodged in the spinal canal, including neurological deterioration, infection, and lead or copper toxicity.⁸ A bullet can gradually move in soft tissue adjacent to the entry wound, penetrate to other organs and pass even about half body length without any symptoms, until it causes obstructive or compressive effects or impact vital organs.⁹ To recognize the direction of the bullet among shooting victims, immediate exploration of entry and exit wounds is necessary.¹⁰ In cases of retained bullets without exit wound, early detection of the bullet by imaging methods is mandatory.^{11,12} Facial treatment of gunshot injury could be divided into four steps which are meant to (a) maintain airway patency, (b) keep bleeding under control, (c) assess whether or not the injury is accompanied by any damage of large blood vessels or vital organs and (d) correct/fix the facial deformity.¹³ In our case there was no any sign and symptom of injury to vital structures and he was hemodynamically stable. The final position of the bullet was away from its entry point. On CT scan a radio-opaque metallic foreign body is seen in nape of neck opposite C2 and C3 vertebral body. It is reaching upto muscular layer. The entry wound was managed well by primary repair without any problem.

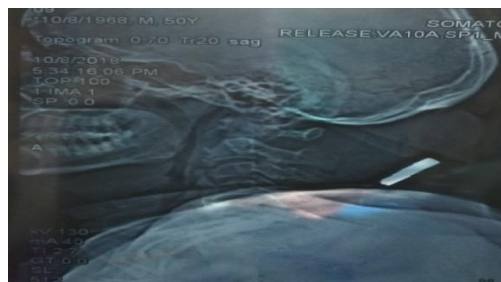

Fig. 1: Showing metallic fb (bullet) in the nape of neck

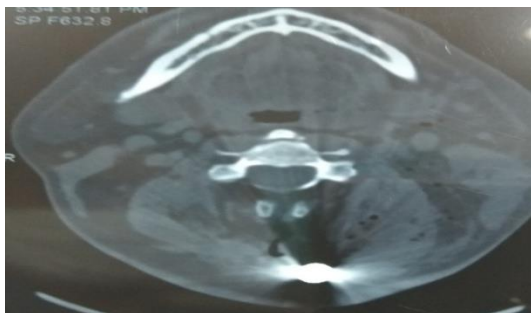


Fig. 2

Conclusion

This is case report of gunshot in which bullet is seen in nape of neck opposite c2 and c3 vertebral body, without any neurological deficit. This case was managed by conservative treatment (non-surgical) with primary repair of entry wound.

References

1. Waters RL, Sie IH. Spinal cord injuries from gunshot wounds to the spine. *Clin Orthop Relat Res.* 2003;(408):120-25.
2. Kitchel SH. Current treatment of gunshot wounds to the spine. *Clin Orthop Relat Res.* 2003;(408):115-19.
3. Bumbasirević M, Lesić A, Bumbasirević V, Rakocević Z, Djurić M. Gunshot injury to the face with a missile lodged in the upper cervical spine without neurological deficit. *Dent maxillofac Radiol.* 2006;35(1):38-42.
4. Brohi SR, Brohi AR, Brohi QR. Brown-Sequard syndrome following firearm injury with a bullet lodged in the upper cervical canal. *J Coll Physicians Surg Pak.* 2008;8(5):312-3.
5. Tender GC, Ratliff J, Awasthi D, Buechter K. Gunshot wounds to the neck. *South Med J.* 2001;94:830-32.
6. Bono CM, Heary RF. Gunshot wounds to the spine. *Spine J.* 2004;4:230-40.
7. Shackford, Steven R. Kahl, Jessica E., Calvo, Richard Y., Kozar, et al. Gunshot wounds and blast injuries to the face are associated with significant morbidity and mortality. Results of an 11-year multi-institutional study of 720 patients. In the *journal of trauma and acute care surg.* 2014;76(2):347-52. DOI: 10.1097/TA.0b013e3182aaa5b8.
8. Tindel NL, Marcillo AE, Tay BK, Bunge RP, Eismont FJ: The effect of surgically implanted bullet fragments on the spinal cord in a rabbit model. *J Bone Joint Surg Am.* 2001;83:A:884-90.
9. Ro T, Murray R, Galvan D, Nazim MH. Atypical gunshot wound: bullet trajectory analyzed by computed tomography. *Int J Surg Case Rep.* 2015;14:104-7.
10. Ministrini S, Baiocchi G, Pittiani F, Lomiento D, Gheza F, Portolani N. Gunshot wound without entrance hole: where is the trick?—a casereport and review of the literature. *World J Emerg Surg.* 2015;10(1):52.
11. Symbas PN, Harlaftis N. Bullet emboli in the pulmonary and systemic arteries. *Ann Surg.* 1977;185(3):318-20.
12. Vázquez-Valdés E, Centeno-Olguín V, Hernández-Zamora JM, Barradas-Guevara MC. [Embolism caused by a bullet. Report of a case and review of the literature]. *Rev Invest Clin.* 1989;41(1):57-62.
13. Hollier L, Grantcharova EP, Kattash M. Facial gunshot wounds: a 4-year experience. *J Oral Maxillofac Surg.* 2001;59:277-82.