

Boon to dentistry of CBCT use: A lingual mandibular bone defect – A radiographic incidental finding

Rucha K Joshi^{1,*}, Bhakti Patil Soman², Deepa Das³

¹Post Graduate Student, ²Reader, ³Professor and HOD, Dept. of Oral Medicine and Radiology, G.D. Pol. Foundation Y.M.T.D.C, Navi Mumbai, Maharashtra, India.

***Corresponding Author: Rucha K Joshi**

Email: dr.rucha.k.joshi94@gmail.com

Abstract

Objective: Since many decades we are using conventional radiography as it is commonly used world-wide. Conventional radiographs lacks many important features which needs to be enhanced in terms of quality of equipment, radiographic techniques used, to interpret accurately and radiation exposure risk, so it is a need of the day to confirm the hidden lesion with accuracy. So recent we came across a radiographic incidental finding of lingual mandibular bone defect by using CBCT.

Results: We incidentally found stafne's bone cyst below the IAN canal on left side of the jaw in mandible with the help of CBCT.

Conclusion: We concluded according to our observation, we observed that CBCT is useful and will have potential value when introduced in routine day to day life examination imaging method in dentistry to confirm the unknown hidden lesions that are most common finding.

Keywords: Cone beam CT, CT, Inferior alveolar nerve canal, Stafne's bone cysts.

Introduction

Stafne bone cyst term also called as stafne bone cavity (SBC), it is a concavity which is present in lingual cortical plate of mandible which contains salivary gland tissue and also idiopathic bone cavity. The radiolucent areas are usually seen as cortical defects that has been occurred as a result of submandibular gland extensions. While diagnosing other lesions this cyst is incidentally found in radiograph.

In 1942 Edward Stafne found 35 asymptomatic radiolucent cavities, which were located unilaterally in mandible that is in the posterior region of the mandible, between the mandibular angle and the third molar, mostly it is found below the inferior dental canal.

In literature four variants of this entity have been found and usually when the term Stafne bone cavity is found in this literature it is usually the posterior lingual variant. The posterior lingual variant is commonly found and the anterior lingual is found 7 times less frequent than the posterior variant, which is located between the lower incisors and the lower premolar areas that is above the insertion of the muscle (mylohyoid muscle).

We have notice that many authors have suggested different structures and entity which had originated due to the pressure exercised by the glandular tissues on the lingual cortical plate of the mandible. Many research found that the submandibular gland is directly associated with the posterior variant, sublingual gland is related with the anterior variant and most commonly the parotid gland with the different variants of the ascending ramus of the mandible. As we know in recent practice we diagnose with the conventional radiographs to confirm the lesions. This lesion that is stafne's bone cyst is asymptomatic and we mostly miss this lesion which is incidental finding get to know sometime incidentally.

In dentistry two most common daily basis radiograph is intraoral periapical radiographs (IOPA) and OPG. In this Orthopantomograph (OPG) we can visualize the lesion as

well defined radiolucent area with a well - defined sclerotic border that is generally recorded below the IAN canal. Sometimes the location of this cavity is atypical and complementary test are not able to provide a reliable diagnosis, so in such cases other methods such as CT, CBCT is choice of option and it should be used. Likewise, some prefer sialography as an effective tool, as it can useful in establishing a relationship between the cavity and the glandular tissue. CT is found to be very useful and has advantages which can overcome the faults and disadvantages of other imaging radiographic technique, we can also verify the peripheral origin of the lesion and conserve the lingual cortical plates, and can identify the tissues in the cavity.

Recent upcoming radiographic technique is MR (magnetic resonance). It is a radiographic technique which is considered by Branstetter et al. With the help of this radiographic technique we can determine whether the tissue which is related with the cavity is in the form of regression or herniation. And above all radiographic technique in literature we found that CT is considered a reasonably affective complementary test and is sufficiently to establish a certain diagnosis.

The radiographic findings of Stafne's bone cavity found to be unilocular, round/oval shaped. Which is radiolucent area surrounded by sclerotic cortical bone.

Different variants are found in many articles and researches. They are as follows: posterior lingual variant which is most common, second is the anterior variant which is least common, third is Ramus of mandible & fourth is Buccal Ramus.

We can give Differential diagnosis which includes OKC, Traumatic bone cyst, simple bone cyst, dentigerous cyst, periapical cyst, non-ossified fibroma, giant cell tumours, etc. which found similar as located in mandible below IAN canal. SBD can include generally salivary glands in accordance with their placement but can also include fat, connective

tissue, lymphoid tissue, muscle and blood vessels and sometimes SBCs can be empty. (Stafne bone cavity)

So to diagnose such hidden cavities/lesions it is necessary to keep radiographic records and follow up frequently which is found incidentally and can be treated accordingly. CBCT identify the suspicious radiolucent areas in all sections and it also provide the proper examination of hidden lesions and pathology with 3-D view with lower radiation exposure and higher speed, it can be used for diagnosis of SBC cases instead of CT imaging.

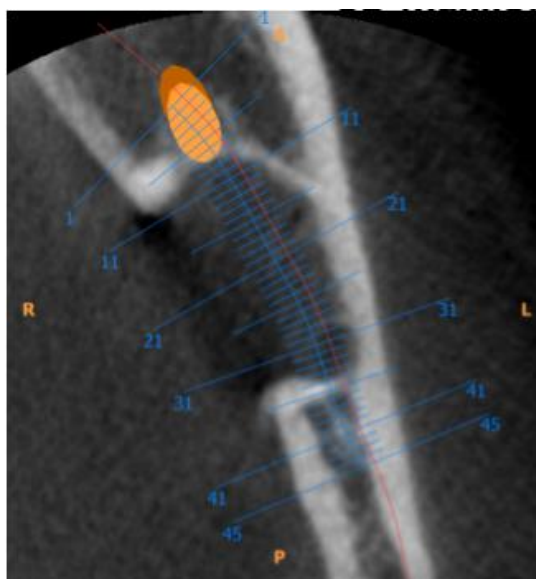


Fig. 1

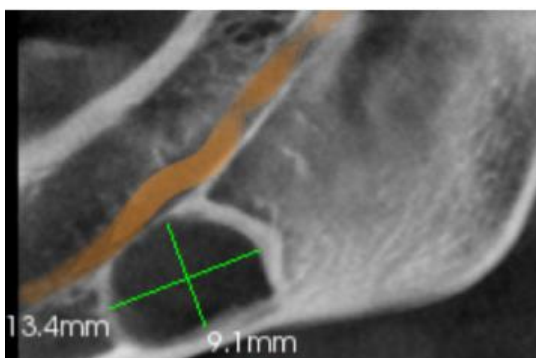


Fig. 2

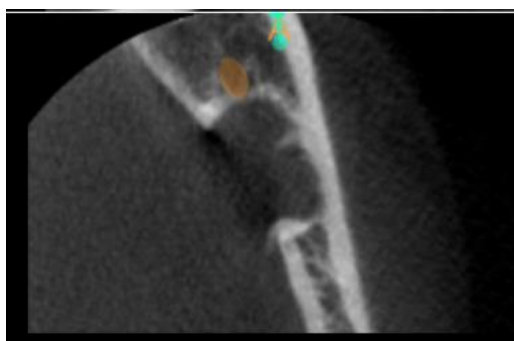


Fig. 3

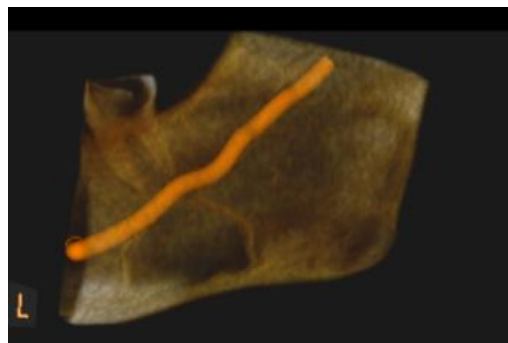


Fig. 4

The above images were recorded in our department of Oral Medicine and Radiology Kharghar. The patient was referred for a cone beam CT (CBCT) imaging series. The lesion was incidental finding in our imaging series. CBCT scan FOV 5x5 was performed with carestream, image processing was performed with CS Imaging software. A radiology report to evaluate the anatomical volume was performed.

Radiographic Findings: Solitary well corticated hypodense area is seen irt left body of mandible below inferior alveolar canal roughly oval about anteroposteriorly 13.4 and superoinferiorly 9.1mm (Fig. 1, 2, 4). Lingual cortical plate is perforated irt left mandible (Fig. 3). Gray scale values (GSV) noted are around 61 to 90. Intact lower border of left mandible seen.

Radiographic Impression: Stafne’s Bone Cyst irt left side of mandible.

Discussion

According to many studies SBD is an uncommon anomaly. CBCT should be suggested over MSCT. As both CBCT and MSCT (multislice CT) provide adequate support for the detection of SBDs but first we should see what is beneficial for the patient. Less exposure imaging technique should be advised to the patient. Few cadaver studies in article reference have revealed that the incidence of the lesion may be as high as 6.06%.⁴ We used PubMed database (National Library of Medicine) for reviewing the cases of SBC and we found most of the SBD cases are published.

Number of reports continues to accumulate, and the knowledge about the aetiology and pathogenesis of SBD is becoming limited and confusing for a long time.⁶ The use of CBCT for its diagnosis has been rarely reported in literature.⁸

In many literatures we found the information of the cavities which are incidentally found in radiograph because the lesion is usually asymptomatic.

According to the relationship of cavity to the buccal cortical plane, Stafne bone defect can be divided into three types.⁴

They are as follow: Type I: The cavity does not reach the buccal cortex, Type II: Reaches the buccal cortical plate without expansion, Type III: The buccal osseous cortex is expanded.

Along with the types it is also divided into three categories based on SBDs content.⁴

They are follows: Category F, S, G.

Category F: Indicates fat density, Category S: Soft tissue density, Category G: Glandular tissue.

Generally treatment is not required for SBDs in either of the variants that is posterior or anterior variants since these mandibular bone depressions have been shown to be an anatomical rather than a pathological condition.^{6,7} In some condition treatment is required then the management of SBDs should be conservative and radiological follow-up should be maintained on regular basis.⁴

Biopsy and surgical exploration of detected defect should only be performed when the diagnosis is uncertain or in exceptional cases when an unusually severed pathology (example pleomorphic adenoma) is suspected.⁵

Conclusion

We incidentally found Stafne's bone cyst using extra oral radiographic examination below the inferior alveolar nerve canal on left side that is CBCT. We concluded according to our observation, we observed that CBCT is useful and will have potential value when introduced in routine day to day life examination imaging method in dentistry to confirm the unknown hidden lesions that are most common finding radiographically. Stafne's cyst is rare and mostly missed from diagnosis as it is an asymptomatic hidden lesion. We suggest CBCT to confirm this incidental finding than other radiographic imaging technique. CBCT is less expensive compare to CT scan & MRI which is available in many hospitals and institution that can benefit the patients regarding radiation exposure and reduced cost rate. It is a boon in the field of Dentistry to find such hidden lesions using CBCT. This is a common defect found radiographically but is uncommon as it is missed many a times without inadequate investigations.

Abbreviations

Computed Tomography – CT, CBCT - Cone beam computed tomography, SBC - Stafne's bone cavity, SBD - Stafne's bone defect, MR - magnetic resonance, OPG - Orthopantomograph, OKC - odontogenic keratocyst, inferior alveolar nerve canal – IAN canal.

Conflict of Interest: Nil.

References

1. Kai H. Lee, J.K. Thiruchelvam, and Peter McDermott, an Unusual Presentation of Stafne Bone Cyst. *J Maxillofac Oral Surg.* 2015;14(3):841– 844.
2. Dr Bruno Di Muzio, A.Prof Frank Gaillard et al, Stafne cyst, Radiology Radiopaedia.
3. Chandramani Bhagwan More, Sunanda Das et al. Stafne's Bone Cavity: A Diagnostic Challenge. *J Clin Diagn Res: JCDR.* 2015;9(11):ZD16–ZD19.
4. Y Sisman, O Miloglu. Radiographic evaluation on prevalence of stafne bone defect: a study from two centres in turkey. *Dentomaxillofac Radiol, Br Inst Radiol.* 2012;41(2):152-158.

5. Simpson W. A stafne's mandibular defect containing a pleomorphic adenoma: report of case. *J Oral Surg.* 1965;23:553–556.
6. Quesada – Gomez C, Valmaseda - Castellon E, Berini – Aytes L, GayEscoda C. Stafne bone cavity: a retrospective study of 11 cases. *Med Oral Patol Oral Cir Bucal.* 2006;11:E277–280.
7. Belmonte – Caro R, Velez – Gutierrez MJ, Garcia DeLaVega – Sosa FJ,et al. A stafne's cavity with unusual location in the mandibular anterior area. *Med Oral Patol Oral Cir Bucal.* 2005;10:173–179.
8. Katz J, Chaushu G, Rotstein I. Stafne's bone cavity in the anterior mandible: a possible diagnostic challenge. *J Endod.* 2001;27:304–307.

How to cite this article: Joshi R. K, Soman B. P, Das D. Boon to dentistry of CBCT use: A lingual mandibular bone defect – A radiographic incidental finding. *Int J Maxillofac Imaging.* 2018;4(4):134-136.