

Prefabricated zirconia Post: an esthetic option as foundation restoration for ceramic crowns: an in vivo study

Anita Kapri^{1,*}, Sudhir Joshi²

¹Prosthodontics, ²Special Medicine, ¹Dept of Prosthodontics, ²Dept of Cardiology Indian Naval Dental Center Denteshwari, India

***Corresponding Author:**

Email: a.kapri@rediffmail.com

Abstract

Background: The choice of restoring endodontically treated anterior teeth is guided by strength and esthetics. The ultimate shade of post and core definitely affects the translucent ceramic crown systems, which is a matter of concern. The colour of the underlying core influences the definitive esthetic result especially for a highly translucent ceramic crown with a thickness of less than 1.6 mm. In case of a thin gingival biotype the cast posts may also create root discoloration and a blue-gray effect. The gold posts, which is considered as gold standard, exhibit a dull bluish hue and give an unnatural appearance. The utilization of a dissimilar material for post and core buildup often results in failure due to separation between the post and core. When the core and the foundation restoration is of ceramic, post based on ceramic material would ensure better success. The prefabricated zirconia posts are one of the novel alternatives to gold post.

Purpose: The mechanical advantage together with the aesthetic gain over the conventional materials has made zirconia the state of art option available for usage in the present day.

Materials and Methods: There are only few relative studies, which have reported on aesthetic, clinical survival and patient reported events of endodontically treated teeth with zirconia post. Hence this clinical study is undertaken to evaluate the acceptability of prefabricated zirconia post used in endodontically treated teeth especially in the anterior region with the foundation restoration being all ceramic restorations.

Results: Zirconia post is a more aesthetic alternative to fiber post especially in patients with gummy smile and thin biotype with all-ceramic crown to optimize the esthetic effect at the root and maintaining an adequate level of strength.

Conclusion: In esthetic zone prefabricated zirconia post is a more simple and viable option to conventional post giving a monoblock (one piece) design.

Keywords: Ceramic post, Esthetic post, Monoblock effect with post.

Introduction

A number of different materials have been used for the manufacturing of dental posts. The ideal post would provide core retention without creating unwanted stresses within the residual tooth structure. The fundamental posts requirements include high tensile strength, high fatigue resistance to occlusal and shear loading and a good distribution of the forces affecting the tooth root in addition to improved esthetics.^{1,2} presently there are multiple systems in use for this purpose and the selection of the most adequate is left to the dentist who ultimately has the responsibility to balance all the factors and select the most suitable system for each patient.

Foundation therapy with metal or gold post has a long-term successful history owing to their superior physical properties. However, their high elastic modulus can generate areas of stress focusing within the surrounding radicular dentin, resulting in root fractures. Many times the metallic posts turn the tooth into a dark color, which is not a favorable characteristic for restorations of the anterior teeth. Some authors have highlighted the need to use posts made with biomechanical properties similar to dentin. In recent years fiber-reinforced resin posts (like glass and carbon fibers) and woven-fiber composite resin material for posts and cores were introduced. Compared with metallic posts fiber posts are less stiff and consequently

show a more favorable stress distribution in the root, which may result in a decreasing of fractures after the restoration. Also, the fact that this kind of materials has a white translucent color (except for the carbon fiber) improves the aesthetics of the restoration. But these posts offer poor retention and have a higher risk of debonding.^{3,4}

Prefabricated zirconium post system have high stiffness and distributes stresses better to the root and provides greater clinical longevity in addition to esthetics whereby the tooth colored translucency of all-ceramic crowns can be established. Owing to the heightened use of prefabricated zirconium post systems many in vitro studies on prefabricated zirconium posts were published in the last few year and few in vivo studies about the retention, resistance, micro-leakage, light transmission and radio- density of prefabricated zirconium post are available but very few in vivo studies elaborate on esthetic improvement of prefabricated zirconium post.⁵⁻⁹

The mechanical advantage together with the aesthetic gain over the conventional materials has made zirconium the state of art option available for use in the present day. Thus, the selection of restoration materials should be based on proper visual features in addition to biocompatibility and sufficient strength of materials.¹⁰

The aim of this article was to provide data on esthetic enhancement of prefabricated zirconium post. Based on the results of this study and previous studies prefabricated zirconium posts may be used to improve the esthetic quality of metal free ceramic crowns.

Materials and Methods

The study would be carried out on consenting patients aged 18 to 45 years who have undergone endodontic treatment in the anterior region and need a foundation restoration. The inclusion criteria were all patients who require foundation restoration and have root canal therapy performed at least 3 months prior and with no subjective or objective symptoms and no lesions visible upon radiography (Fig. 1&2). Intraoral periapical radiographs were taken when the restoration was performed and were examined with approximately 5 magnifications. Teeth will receive zirconium posts. These Posts are available in different dimensions and shape to ensure better adaptation to the prepared canal. The choice of various lengths and configurations provided the possibility to find the adequate post dimension following the criteria of maximum conservation of the residual dental tissue. In accordance with previous studies, the following parameters were considered relevant: number of canals; remaining tooth tissue, defined as complete (C 66% or more of the tooth) partial (P 33% to 65% of the tooth) or absent (A less than 32% of the tooth) shape of the canal space and tooth antagonist.

Method

Clinical Procedures: Patients with root canal treated teeth within the age group of 18-45 years would be considered for the study. A total of 100 root canal treated teeth for the above subjects would be included. 50 root canal treated teeth would be receiving fiber post (Tenax Fiber Trans trademark by Coltene/Whaledent Inc. in Cuyahoga Falls, OH, 44223) and would be considered as controls. The rest 50 root canal treated teeth would be considered as study group and would receive the prefabricated zirconium post (Zirix trademark by Harald Nordin SA in CH-1817 Brent/Montreux). Both the groups will be rehabilitated with metal free crowns. Standard procedure for preparation of post and foundation restoration with metal free crowns will be followed. Resin Cement (Vario Link) will be used for cementation used for the post and metal free crowns.

Post Preparation: Following direct clinical observation and radiographic examination, the operator will select the most suitably sized prefabricated zirconium post. Root canal will be prepared with a slow-speed hand piece using a suitable drill with water spray. These calibrated burs provided a uniform preparation and a thin and equally distributed coat of resin surrounding the post after its cementation. The post was then reduced to the proper length using an 80- μ m-diamond bur in a high-speed hand piece with water spray the bur was kept perpendicular to the long axis of the post to avoid

damaging its form and its mechanical features. The size of the post will be at least equal to the length of the clinical crown, always respecting the apical seal of 4 mm.

Cementation Procedure: Vario link II (Ivoclar Vivadent, Schaan, Liechtenstein) dual-polymerizing resin cement was used. Acid etch (phosphoric acid gel 37%, Ivoclar Vivadent) was applied to the tooth for 15 seconds.¹¹ The canal was rinsed immediately with water and dried with paper points. The adhesive (Excite DSC, Ivoclar Vivadent) was applied to the canal using microbrush and excess adhesive was removed using paper points. Small amount of primer and then adhesive will be applied with a Microbrush on the post surface also and then dried to allow the evaporation of the acetone. Bonding agent will be applied in the canal with a paper cone. The cement mixed in a 1:1 ratio on a mixing pad for 10 seconds. The cement was applied to the bonding surface of the canal. The posts were also coated with the cement and inserted to the prepared canals with finger pressure, and excess cement was removed flush with the top of the tooth. The light activation was performed for 40 seconds. The excess cement was trimmed and given an adequate setting time (Fig. 3,4a, 4b). Core buildup was then performed using Multi Core (Ivoclar Vivadent) self-curing resin composite. Teeth were prepared to receive metal free crowns (Fig. 5). Metal free crowns were then cemented using Vario link dual cure luting cement (Fig. 6a and Fig. 6b).

Clinical evaluation: Recalls were performed at 6, 12, 18 months. Two dentists assessed the in vivo outcome of the restored teeth. The examiners were not blinded. Clinical Outcome was regarded fruitful only if the post and core were in situ with neither the post nor the crown showed any displacement or detachment or fracture. Esthetic parameters would include Crown morphology, Crown colour match, and mucosal discoloration. Visual Analogue Scale (VAS) scale will be used to evaluate the aesthetic performance of crowns. The aesthetic features were evaluated by using the photographs taken at the follow-up examinations combined with the preoperative clinical registrations by two different patients and the dentists. For VAS scale a 100 mm line with the end phrases very bad aesthetic on the left and very good aesthetic on the right will be used. Two prosthodontists and two patients assessed photographs twice with a gap of 1 week. Subjective signs reported by the patients were considered potential signs of failure. All the data will be analysed using suitable statistical analysis.

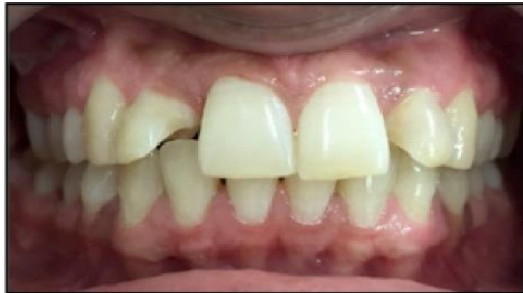

Fig. 1: Preoperative intraoral photograph

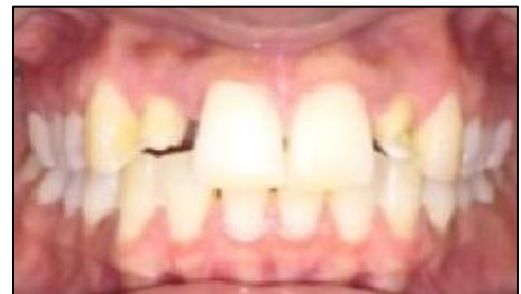

Fig. 5: Teeth preparation

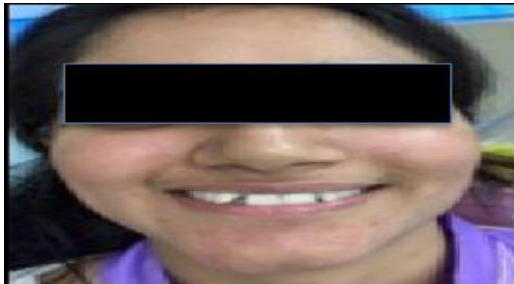

Fig. 2: Preoperative extra oral photograph

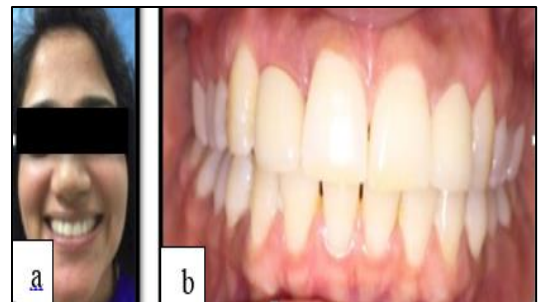

Fig. 6(a): Post treatment extra oral photograph; (b) Post Treatment intraoral Photograph

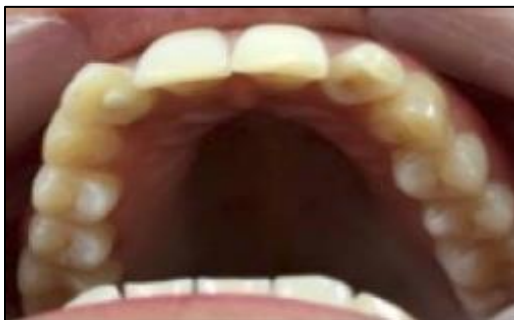

Fig. 3: Zirconia and fiber placement (clinical)

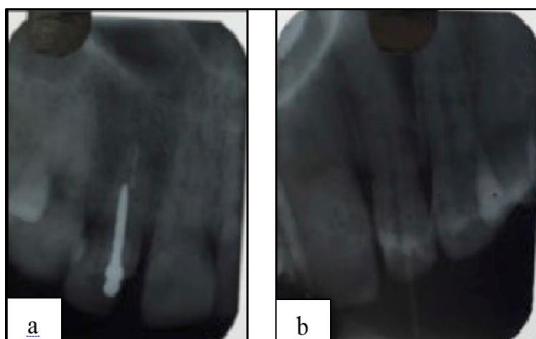


Fig. 4 (a): Zirconia Post Radiograph; (b): Fiber Post Placement (Radiograph)

Results

The total number of patients, which met the inclusion criteria was 20 of these patients 2 patients had prefabricated zirconium post fracture. The results of Copenhagen Index Score and VAS Score are mentioned in Table 1 and 2 respectively. Both the data showed statistically significant results. Among the CIS score crown color match showed highly significant results with p value= 006 Crown Morphology showed p value=. 082 and Mucosal Discoloration had p value=0.192. VAS scores very highly significant values. This could be explained as the prefabricated zirconium post with metal free crowns gave a monobloc design resulting in a highly esthetic color match and also due to the thickness of metal free crown and the luting agent which could easily mask the opaque effect of prefabricated zirconium post.

Table 1: CIS Score

Patient's No.	Crown Morphology		Mucosal Discoloration		Crown Color Match	
	Zirconia Post	Fiber Post	Zirconia Post	Fiber Post	Zirconia Post	Fiber Post
1	1	1	1	2	1	2
2	1	1	1	1	1	1
3	1	1	1	1	1	2
4	1	1	1	1	1	1
5	1	2	1	2	1	1

6	1	1	2	1	1	1
7	1	1	1	1	1	2
8	2	3	2	2	2	3
9	1	1	1	1	1	1
10	1	2	1	2	1	2
	95% CI for mean difference: (-0.587, 0.041) P-Value = 0.082		95% CI for mean difference: (-0.707, 0.162) P-Value = 0.192		95% CI for mean difference: (-0.896, -0.195) P-Value = 0.006 Statistically Significant	

Table 2: VAS Score

Patient's No.	Zirconia Post	Fiber Post
1	4	3
2	5	3
3	5	4
4	5	3
5	4	3
6	5	3
7	5	4
8	4	3
9	5	3
10	5	4
	95% CI for mean difference: (1.025, 1.703) P-Value = 0.000 Statistically Significant	

Test Applied is Paired t- Test

Discussion

As explained by Vichi et al.¹² in their study, they investigated the results of the thickness of all-ceramic crown restoration and the film thickness of luting cements on masking the opaque posts (zirconium, carbon fiber and resin composite). It was found that a ceramic thickness of 2.0 mm was needed to ensure an acceptable esthetic outcome with the opaque posts whereas luting cement thickness was found to have slight effect on the post treatment esthetics.

The ability of all ceramic materials to be bonded to enamel and dentin along with high strength and esthetics has improved the application of metal-free crowns in recent years.¹³ Restoring anterior non et al. teeth with metal post and cores will negate the very purpose of all-ceramic crown by compromising on the esthetics. Metal posts may be visible through the all-ceramic crowns and thin gingiva or at the least decrease the depth of translucency of the restoration. When nonprecious alloys are used to form the foundation discoloration may occur due to corrosion. There is a need for a post-and-core system capable of combining the translucency of ceramics and the good mechanical properties of prefabricated metal posts.

Prefabricated zirconium posts are gaining popularity as an ideal all-ceramic post as they provide optical properties for post/cores similar to that of all-ceramic crowns. Pure zirconium is not suitable to be used in the manufacture of posts without the addition of

stabilizers. Zirconium oxide is currently the strongest white-shaded ceramic. They are commonly known as YTZP (yttrium-stabilized tetragonal zirconium polycrystals) containing zirconium oxide (94.9%) and yttrium oxide (5.1%). Only this zirconia provides high performance. When subjected to stress, the tetragonal crystal phase is transformed into monoclinic phase and an associated volumetric expansion (3-5%) takes place. This in turn results in the internal stresses being developed opposing the opening of a crack, thereby increasing the resistance of the material to propagate crack. Therefore stress is absorbed and no crack formation occurs. Zirconium is also used extensively as orthopedic implants and it is the strongest and toughest ceramic available currently.¹⁴

Zirconium ceramics have flexural strength similar to metal and carbon fiber posts. The flexural strength is 900 MP. They possess excellent strength and crack resistance.¹⁵⁻¹⁷ They also possess a high elastic modulus and are less liable to fail adhesively during mastication. Prefabricated zirconium posts have superior esthetic bond to dentin and to build-up resin through adhesive cement. They are radio-opaque in comparison to other metal-free posts, and they are compatible with composite and ceramic. They can be used in direct techniques or in indirect techniques using heat-pressed ceramics. The disadvantages include that they are difficult to remove from root canal if retreatment is necessary, and a relatively higher cost. Long-term studies are not available as of now.¹⁸ Prefabricated zirconium posts are indicated in adequate overbite/overjet cases with a minimum of 2-3 mm of the remaining tooth structure and without any periapical pathology or sinus discharge.

The introduction of zirconium ceramics has flexural strength twice that of aluminous ceramic systems, which can therefore be used to construct posts of realistic diameters.¹⁹ Various zirconium fabrication technologies have shown superior physical properties especially with the development of computer-aided design (CAD)/computer-aided manufacturing (CAM) systems high-strength zirconium frameworks can be fabricated for full and partial coverage crowns, fixed partial dentures, veneers, posts and/or cores, primary double crowns, implant abutments, and implants. Data from in vivo and invitro studies show promising results regarding their performance and survival.²⁰

Zirconium ceramics have been shown to be biocompatible. Building a core of ceramic directly onto

the zirconium posts has not been possible owing to the dissimilar thermal coefficients of expansion of the core and post materials, resulting in fracture of the core.²¹ The fracture toughness of copy-milled zirconium posts is sufficiently lower than that of prefabricated zirconium posts of the same length.²²

Prefabricated zirconium posts have shown more rigidity than stainless steel posts. Aesthetic zirconium ceramic posts are available in traditional shapes and can be easily used in round root cross sections. Their radiopacity, biocompatibility, mechanical rigidity and ability to bond to variety of ceramics using resin luting materials as well as composites have made these prefabricated zirconium posts very popular.²³

Conclusion

With the zirconium material, its main advantages lie in its translucency and tooth-colored shade, thereby rendering the material usable with all-ceramic crowns in the anterior esthetic zone. Especially in a patient who has a high lip line and thin gingival biotype would require the use of a prefabricated zirconium post with an all-ceramic crown to enhance the esthetic effect at the root while maintaining an adequate level of strength. Prefabricated Zirconium post is a viable esthetic substitute to traditional post. Its simple technique and monoblock design with ceramic crowns allows it to less time consuming and a more effective foundation therapy.

References

- Alharbi FA, Nathanson D, Morgano S, Baba NZ. Fracture resistance and failure mode of fatigued endodontically treated teeth restored with fiber-reinforced resin posts and metallic posts in vitro. *Dent Traumatol.* 2014;30(4):317–25.
- Manhart J. Fiberglass reinforced composite endodontic posts. *Endod Prac.* 2009;16–20.
- Akkayan B, Gülmez T. Resistance to fracture of endodontically treated teeth restored with different post systems. *J Prosthet Dent.* 2002;87(4):431–37.
- Fokkinga WA, Kreulen CM, Bell-Rönnlöf L, Lassila L V, Vallittu PK, Creugers NH. In vitro fracture behavior of maxillary premolars with metal crowns and several post-and-core systems. *Eur J Oral Sci.* 2006;114(3):250–56.
- Zeynep Ozcutur, Ufuk Iser and Ender Kazazoglu; Zirconium ceramic post systems. A literature review and a case report; *Dent Mater J.* 2010; 29(3):233–45.
- Guido Heydeckea, Frank Butz, Jorg R. Strub; Fracture strength and survival rate of endodontically treated maxillary incisors with approximal cavities after restoration with different post and core systems: an in-vitro study. *J of Dent.* 29; 2001:427-33.
- Butz, Frank; Lennon, Áine M.; Heydecke, Guido; Strub, Jörg R; Survival Rate and Fracture Strength of Endodontically Treated Maxillary Incisors with Moderate Defects Restored with Different Post-and-Core Systems: An In Vitro Study. *Int J of Prosthodont.* 2001;14(1):58–64.
- Resistance to fracture of endodontically treated teeth restored with different post systems; Begum Akkayan, Turgut Gulmez. *J Prosthet Dent.* 2002;87(4):431–37.
- Bittner N¹, Hill T, Randi A. Evaluation of a one-piece milled zirconium post and core with different post-and-core systems: An in vitro study. *J Prosthet Dent.* 2010;103(6):369-79.
- Rosentritt M, Furer C, Behr M, Lang R, Handel G. Comparison of in vitro fracture strength of metallic and tooth-coloured posts and cores. *J Oral Rehabil.* 2000;27:595-601.
- Nordin-Catalogue-Dentaire; *Nordin Swiss Dental Products.* 2016. [updated 2016 July; cited 2018 Oct 23]. Available from: <https://reunion-sante.com/wp-content/uploads/2016/07/Nordin-Catalogue-Dentaire.pdf>
- Vichi A, Ferrari M, Davidson CL. Influence of ceramic and cement thickness on the masking of various types of opaque posts. *J Prosthet Dent.* 2000;83:412-17.
- Rosenblum MA, Schulman S. A review of all-ceramic restorations. *J Am Dent Assoc.* 1997;128:297-307.
- Vidyashree V Nandini, Vijay K Venkatesh, D Kandaswamy; Zirconium post-pressed ceramic core-supported all-ceramic crown: Case reports and 4-year follow-up. *J Ind Prosthodont Soc.* 2007;7(4):199-202.
- Ardlin BI. Transformation-toughened zirconium for dental inlays, crowns, bridges: Chemical stability and effect of low-temperature ageing on flexural strength and surface structure. *Dent Mater.* 2002; 18:590-95.
- Christel P, Meunier A, Heler M, Torre JP, Peille CN. Mechanical properties and short-term in vivo evaluation of yttrium-oxide partially-stabilized zirconium. *J Biomed Mater Res.* 1989;23:45-61.
- Wegner SM, Kern M. Long-term resin bond strength to zirconium ceramic. *J Adhes Dent.* 2000;2:139-47.
- Koutayas SO, Kern M. All-ceramic posts and cores: The state of the art. *Quintessence Int.* 1999;30:383-92.
- El-Mowafy O, Brochu JF. Longevity and clinical performance of IPS Empress ceramic restorations: A literature review. *J Can Dent Assoc.* 2002;68:233-37.
- Dominic A. *Stewardson Non-metal post systems Dent update.* 2001;28:326-336.
- Koutayas SO¹, Vagkopoulou T, Pelekanos S, Koidis P, Strub JR. Zirconium in dentistry: part 2. Evidence-based clinical breakthrough. *Eur J Esthet Dent.* 2009;4(4):348-80.
- Beck N, Graef F, Wichmann M, Karl M In vitro fracture resistance of copy-milled zirconium ceramic posts. *J Prosthet Dent.* 2010;103(1):40-44.
- Alan H Gluskin, Irfan Ahmad, Dale B.Herrero The esthetic post & core: Unifying radicular form & structure. *Pract Proced Aesthet Dent.* 2002;14(4):313-21.

How to cite the article: Kapri A., Joshi S. Prefabricated zirconia Post; an esthetic option as foundation restoration for ceramic crowns: an in vivo study *Ann Prosthodont Restor Dent* 2018;4(4):114-118.