

A case report of adult onset eccrine angiomatous hamartoma: A rare entity

Neikhrielie Khro^{1*}, Revathy. M²

¹2nd Year Post Graduate, ²Professor, ^{1,2}Dept. of Dermatology, ^{1,2}Coimbatore Medical College, Tamil Nadu, India

*Corresponding Author: Neikhrielie Khro

Email: neikhrieliekhro@gmail.com

Abstract

Introduction: Eccrine angiomatous hamartoma (EAH) is an extremely rare and benign malformation in adults which presents with single or multiple nodules or single large plaque over the extremities at birth with pain and marked sweating. On histopathological examination, there is increased proliferation of eccrine sweat glands and capillary vessels in the dermis. Herein we report a 43 year-old male who presented with a single hyperpigmented plaque over the hypothenar eminence of right palm associated with excessive sweating for 3 months duration. Biopsy from the lesion was suggestive of eccrine angiomatous hamartoma. This case has been reported due to its unusual adult onset.

Keywords: Eccrine angiomatous hamartoma, EAH, Benign tumor, Adult onset.

Introduction

Eccrine angiomatous hamartoma (EAH) is a rare and benign tumor, histologically characterized by increased number of dilated eccrine glands and capillary vessels. It was first described in 1859 by Lotzbeck as an angiomatous lesion on the cheek of a child and later EAH was coined in 1968 by Hyman and coworkers.^{1,6} EAH may appear as flesh colored, blue brown, yellow or reddish macule, plaque or nodule associated with exquisite pain on palpation and hyperhidrosis. Asymptomatic lesions do not require any treatment. It is important to recognize this benign clinical entity, for which aggressive treatment is not necessary.¹

Case Report

A 43 year old male, working as a supervisor in a hotel came with complaints of hyperpigmented plaque over right palm for 3 months duration which started as a small red itchy plaque. It was associated with excessive sweating over the plaque and pain following local pressure and physical exertion. No history of trauma or similar lesions in other parts of the body. No history of atopy. No history of hypopigmented patches or altered sensations over the extremities.

Clinical Examination

A solitary, well defined, hyperpigmented plaque of 5x3cm size present over the hypothenar eminence of Right palm. Plaque was tender, firm, cold, and incompressible with intact sensation. Amputated index finger following trauma on the left hand as shown in figure 1(b). Hair, nail, oral mucosa, genitals were normal and systemic examination was also normal.

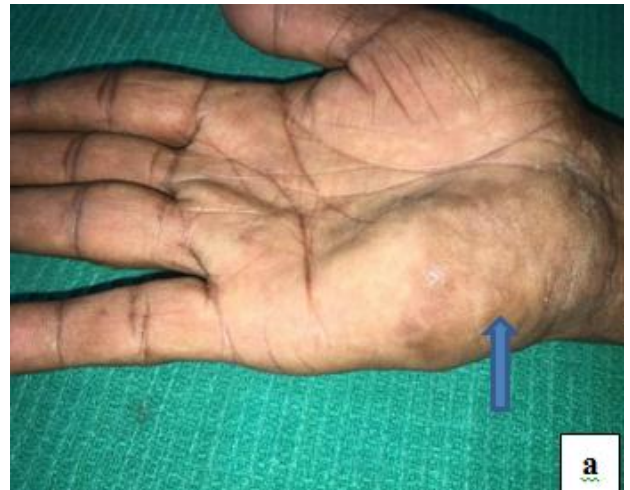

Fig. 1: a. hyperpigmented plaque on the right (blue arrow).

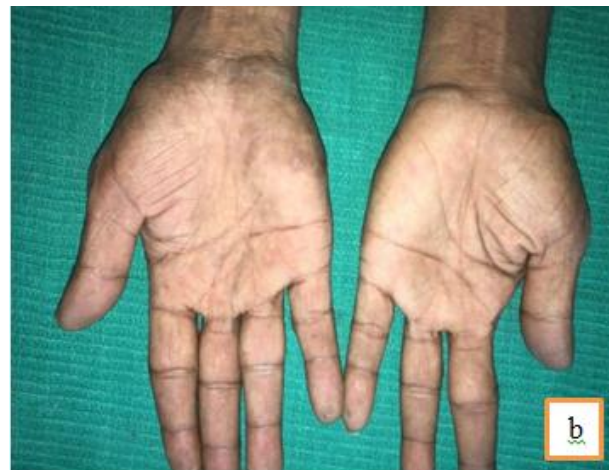

Fig. 1: b. Comparison with the normal left hand (note the amputated index finger on the left).

Clinical differential diagnosis were Glomus tumor, Tufted angioma, Blue bleb rubber nevus, Eccrine nevus, Hansen's disease (due to amputated finger).

Investigations

Routine investigations including Complete hemogram, Peripheral smear, Liver function test, Renal function test, ECG, Chest x-ray were normal. Ultrasound showed subcutaneous soft tissue thickening with no evidence of increased vascularity. Biopsy for HPE taken from the skin lesion showed hyperkeratosis, acanthosis, and increased in number of eccrine glands in mid and lower dermis with surrounding fat lobules, and stroma with abundant capillary angiomatous foci.

HPE from the lesion

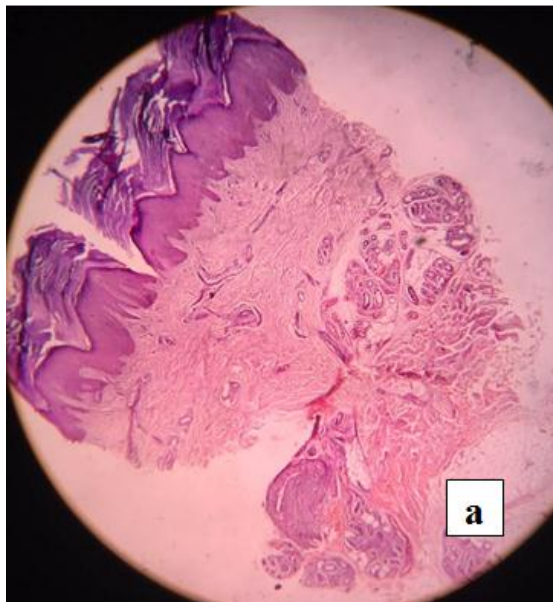


Fig. 2: a. Epidermis showing hyperkeratosis and acanthosis. Dermis showing increased no. of eccrine glands and capillaries.

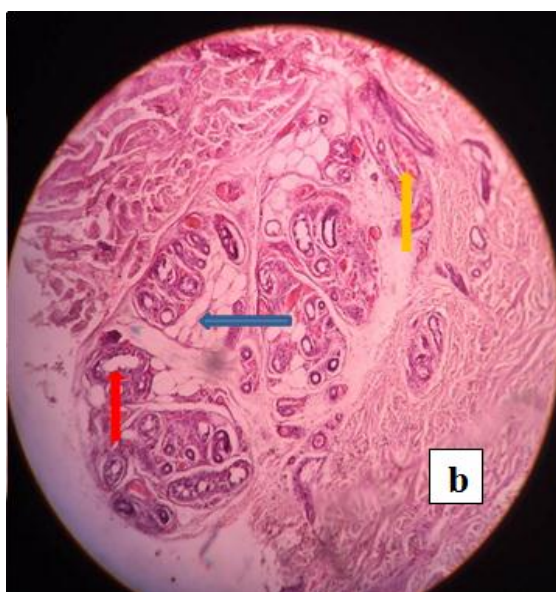


Fig. 2: b. Magnified view of dermis, red arrow-hyperplastic eccrine ducts, blue arrow-fat lobules, yellow arrow-dilated capillaries with RBCs.

Based on the clinical and skin biopsy findings, a diagnosis of Eccrine Angiomatous Hamartoma (EAH) was made and consequently surgical excision was planned but the patient was lost for follow up.

Discussion

Eccrine angiomatous hamartoma (EAH) is a benign and very rare cutaneous malformation usually appearing as a single macule or dusky bluish nodule or solitary plaque at birth or early in childhood although in our case it appeared at middle age. It can occur as multiple lesions sometimes. The size of the lesions varies from 2 mm to 3 mm to several centimeters. About 50 cases have been reported so far worldwide, out of which we could find only 8 cases in which the onset was during adulthood, as in our case.⁷ The lesions may mostly favour extremities where there is increased number of eccrine glands mainly in palms and soles associated with pain or tenderness and hyperhidrosis.^{2,3,4} Pain is seen in 42% and hyperhidrosis in 32 % of the cases.⁶ Uncommon variants of EAH are verrucous EAH where it resembles angiokeratoma or verrucous hemangioma, and palmar cutaneous hamartoma where in addition to fats, capillary channels and eccrine glands, there is neurovascular glomeric bodies.^{2,6} On HPE, Eccrine angiomatous hamartoma shows multiple dilated secretory and ductal parts of eccrine glands that are surrounded by capillary vessels and lymphatic channels in deeper dermis with invasion of adipose fats, nerve fibers, hair follicles and mucin sometimes.^{2,4} Tenderness of the lesions may be due to presence of small nerve branches in between the eccrine ducts. The exact etiology of EAH is unknown but it has been proposed that there is a faulty in differentiating epithelial-mesenchymal interactions leading to excessive proliferations of eccrine glands and vessels or due to faulty induction of heterotypic dependency during organogenesis.⁶ Late onset EAH can be due to recurrent trauma but in our case the patient denies any history of trauma. Neurofibromatosis type 1 has also been reported with EAH. Starch-iodine test can be done to demonstrate hyperhidrosis. Common clinical differential diagnosis includes Eccrine nevus, Eccrine poroma, tufted angioma, Glomus tumor, Blue bleb rubber nevus which can be easily differentiated by specific histopathological findings. Eccrine nevus can present clinically as a well circumscribed area of hyperhidrosis with a sweat discharging pore or papular lesions arranged in linear fashion and histologically distinguished by increase in number and size of eccrine coils without increase in capillary channels and fatty tissues.³ Eccrine poroma usually presents with asymptomatic skin colored nodular lesions on palms and soles with nests of small keratinocytes attached to epidermis, the number and size of eccrine glands, capillary channels are usually normal in eccrine poroma. Tufted angioma is also a close differential as it can present with hyperhidrosis but histopathologically there is proliferation of all the dermal capillaries giving cannon ball appearance. Glomus tumors can also present at third or fourth decade as single small bluish red nodule on the palms, subungual region of fingers

and foot associated with pain on exposure to cold or pressure and histologically glomus cells surrounds vascular spaces with rows of round dark nuclei and little cytoplasm giving the appearance of string of black pearls.^{3,5} A blue rubber bleb nevus can present at birth as soft, dark blue nodules with irregular spaces in the lower dermis with RBCs and fibrinous materials on HPE. Generally speaking, aggressive treatment is unwarranted in EAH since it is usually benign and slow growing. Botulinum toxin injection and aluminum chloride can be tried for hyperhidrosis. Surgical excision, Lasers and Sclerosants are other treatment options in symptomatic and cosmetically disfiguring patients. Surgical excision is usually curative in selected patients. Very rarely amputation of acral parts are indicated in extensive lesions.⁶ Spontaneous regression has been reported in some cases.²

Conclusion

This case is reported due to its rarity and unusual adult onset.

Conflicts of Interest: None.

References

1. Eccrine angiomatous hamartoma: A case report and review of the literature, *Cutis*. 2003;71(6):449-455.
2. Weedon's Skin Pathology. In: Weedon D, editor. 3rd ed. UK:

- Churchill Livingstone Elsevier; 2010.794-795.
3. Dermatopathology. In: Elston DM, Ferringer T, Ko JC, Peckham S, editors. 2nd ed. USA: Saunders Elsevier; 2014. p. 98-103.
4. Lever's Histopathology of the Skin. In: Elder DE, Elenitsas R, Rosenbach M, Johnson BL, Murphy GF, Xiaowei X, editors. 11th ed. Philadelphia: Wolters Kluwer; 2015;883-884.
5. Neoplastic Mimics in Dermatopathology. In: Wick MR, Patterson JW, editors. 1st ed. USA: Demos Medical; 2013. p. 36-38
6. Verma P, Kaur M, Narula V, Ramesh V, Singh A, Saxena A K. Verrucous eccrine angiomatous hamartoma. *Indian J Dermatol Venereol Leprol* 2017;83:367-369
7. Adult-onset eccrine angiomatous hamartoma: report of a rare entity with unusual histological features. *J Eur Acad Dermatol Venereology* 2015;28(7):981-983.

How to cite this article: Khro N, M Revathy, A case report of adult onset eccrine angiomatous hamartoma: A rare entity, *Indian J Clin Exp Dermatol*, 2019;5(1):95-97