

Assessment of hydronephrosis in obstetrics and gynaecology patients: Most useful application of MR urography

Dipali Kadam¹, Saurabh Patil^{2,*}, Meenal Jain³

¹Professor, ^{2,3}Junior Resident, Dept. of Radiodiagnosis, NKP Salve Institute of Medical Sciences & Lata Mangeshkar Hospital, Nagpur, Maharashtra, India

***Corresponding Author: Saurabh Patil**

Email: dr.slpatil24@gmail.com

Received: 11th December, 2018

Accepted: 14th January, 2019

Abstract

Introduction: MR urography has been utilised to evaluate entire urinary system with advantage of not using ionizing radiation. Differentiate between physiological hydronephrosis from pathological is main concern in pregnant patients. Early identification of hydronephrosis in cases of ca cervix is required for better prognosis. So, present study was conducted to assess hydronephrosis in these patients with MR urography.

Materials and Methods: A cross sectional prospective study was carried out on sonographically detected hydronephrosis in thirty Obstetric & Gynaecology patients including 17 pregnant women.

Discussion: MR urography was performed using two techniques- static and excretory urography. Static MR Urography utilizes urine as a static fluid for demonstration of bilateral ureters whereas contrast is used in excretory urography. In instances of pregnant patients, physiologic dilatation exhibited a trademark decreasing tapering due to extrinsic obstruction of the middle third of the ureter by the uterus, more common on the right side. High sensitivity had been accounted for detection of urinary tract dilatation and identification of the site of obstruction.

Conclusion: MR urography provides excellent imaging of entire urinary system giving exact etiology of hydronephrosis in cases of pregnant patients as well as in cases of carcinomas of female pelvis origin without use of ionising radiation.

Keywords: Hydronephrosis, MR urography, Ca cervix.

Introduction

Hydronephrosis is not a primary disease, it is a condition in which urine fails to drain in urinary bladder causing dilatation of pelvicalyceal system.¹ It's a secondary condition that results from some other underlying disease, which most commonly affects only one kidney, but it can involve both. Physiological dilatation during pregnancy is most common cause of hydronephrosis in OBGY patients, followed by calculus, cervical cancer and large ovarian mass. Hydronephrosis is considered as a normal phenomenon in most of pregnant women. This may be due to compression of growing fetus on ureters or relaxation of smooth muscle due to progesterone.^{2,3} However, sometimes this hydronephrosis give rise to symptoms like pain in lumbar region, difficulty in micturition, and if left untreated, it may result in life threatening condition which may endanger the mother and the fetus both.⁴ Cervical cancer patients often develop hydronephrosis due to compression of ureter by tumor or enlarged lymph nodes or inflammation.⁵⁻⁷ Cancers are mostly treated with nephrotoxic drugs, so if there is renal insufficiency due to hydronephrosis, drugs may get omitted.⁸ Also enlarged fibroid and large ovarian tumour can result in obstructive uropathy.

MRU provides a non-invasive visualization not only of the collecting system but also of the renal parenchyma using fast spin-echo pulse sequences as well. MR urography procedure for the demonstration of the urinary tract is divided into two categories: static-fluid MR urography and excretory MR urography. Static-fluid MR urography is performed by heavily T2-weighted sequences which uses the long T2 relaxation time of fluid in the collecting system to visualize the urinary tract as a static collection of fluid. This can be

repeated with cine MR urography to confirm stenosis in ureter. Excretory MR urography is performed with the help of intravenous administration of gadolinium contrast during excretory phase.^{9,10}

Hence, present study was carried out in our department to assess the hydronephrosis in Obstetric & Gynaecology patients with MR urography as imaging modality.

Materials and Methods

This was a cross sectional study performed over a period of a year between February 2017 to January 2018 on patients referred from Obstetric & Gynaecology department to our Radio-diagnosis department for investigation. 30 patients were included in our study out of which 17 were pregnant women. All age group female patients with clinical features of hydronephrosis and pre-detected on USG were included in our study.

The study was performed using GE 1.5 Tesla 16 channel-MRI machine. Claustrophobic patients were excluded from our study. Protocol of the study was submitted to ethical committee of the institute and necessary approval was obtained. Each patient gave an informed consent in local dialect before joining the study.

Patient was advised to void before procedure. For Adult patients, 500cc NS bolus was given immediately before scan. Following sequences were used in MR urography.

Without Contrast Sequences

1. Localizer -Abdomen & Pelvis
2. Coronal SSFSE -Abdomen & Pelvis
3. Axial T2 Fat Sat-Respiratory Triggered-Abdomen & Pelvis

4. Axial T2 Fat Sat-Breath Hold-Abdomen & Pelvis
5. Coronal 3D MRCP Thick of Kidneys

PRE Contrast sequences

1. Ureters and Bladder Thick slab MR Urographic coronal

Post contrast sequences

1. 3D Fat Sat Gradient Dynamic Axial (pre contrast-during the time of contrast-20 sec and 45 sec acquisitions)
2. 3D Fat Sat Gradient Axial - Abdomen & Pelvis (Excretory phase)
3. 3D Fat Sat Gradient Coronal - Abdomen & Pelvis (Excretory phase)

Results

Most of the patients in our study were presented with flank pain. Right side pain is more common. Distribution of patients according to the presenting symptoms is shown in Table 1.

Table 1: Distribution of patients according to symptoms

Symptoms	N	%
Flank pain	17	57
Burning micturition	5	17
Dysuria	2	7
Increased frequency	4	13
Nausea	6	20
Anorexia	4	13
Pyuria	2	7

Ultrasonography were performed first on all the patients included in our study with clinical features of Obstructive uropathy. Hydronephrosis was confirmed on USG on these patients and then MR urography was done. Out of 30 patients in our study, 17 were pregnant females. Physiological dilatation was more common in them. In rest 13 patients, Carcinoma cervix was second most common cause of hydronephrosis (Table 2). All the causes noted in table 2 were accurately diagnosed on MR urography.

Table 2: Distribution of patients according to etiology of hydronephrosis

Etiology of Hydronephrosis	N	%
Physiological dilatation in pregnancy	11	37
Calculus	3	10
Pyelonephritis	2	7
Carcinoma cervix	9	29
Ovarian tumor	3	10
Fibroid	2	7
Total	30	100

Discussion

Hydronephrosis develops due to obstruction to the normal flow of urine in urinary tract, which causes accumulation of urine within urinary tract. Any anatomical or functional lesion located between urinary tract can cause obstruction. USG, IVP and CT urography has been used since long for investigation of hydronephrosis. USG is cheap and easily available, it can provide information regarding upper urinary tract well, however fails to comment on renal function. IVP and CT urography can provide this functional information, however these modalities cannot be used in pregnant patients due to high radiation doses.

Hence we conducted this study with MR urography which has the advantage of not using ionizing radiation and the potential to provide more functional information than CT. MR urographic sequences for displaying the urinary tract can be divided into two categories: static-fluid MR urography and excretory MR urography. Static-fluid MR urography is heavily weighted T2 sequences to image the urinary tract as a static collection of fluid. Excretory MR urography is performed after the intravenous administration of gadolinium-based contrast material.

Physiological hydronephrosis during pregnancy most commonly occurred in primigravida during the second trimester. It is prominently seen on right side and within a few weeks after birth. According to various surveys, hydronephrosis develops due to gravid uterus compression of the ureters between the pregnant uterus and the linea terminalis. High grades of hydronephrosis may results in ascending urinary tract infection during pregnancy. Also chances of development of pre-eclampsia are more in these patients.¹¹ Hence early detections is required. We performed only static MR urography in pregnant patients, as requirement is only to differentiate physiological from pathological dilatation. Also few study suggested that Gadolinium is not safe during pregnancy. Most of the pregnant woman in our study had developed physiological hydronephrosis. They were managed conservatively. The imaging finding noted in these patients is tapering due to extrinsic obstruction of the middle third of the ureter by the gravid uterus, mostly on the right side (Fig. 1). Other etiology that came across our study was renal calculus and pyelonephritis. Phenomenon of renal calculus is rare,¹² we had 3 such cases. Pyelonephritis may be due to ascending infection during pregnancy. Renal calculus can be seen as filling defect on MR urography (Fig. 2) whereas fluid-fluid level is seen in cases of pyelonephritis. Renal and perirenal edema are mostly seen in acute calculous obstruction. Roy et al¹³ demonstrated urinary tract dilatation and level of obstruction in 17 pregnant patients with T2-weighted MR urography.

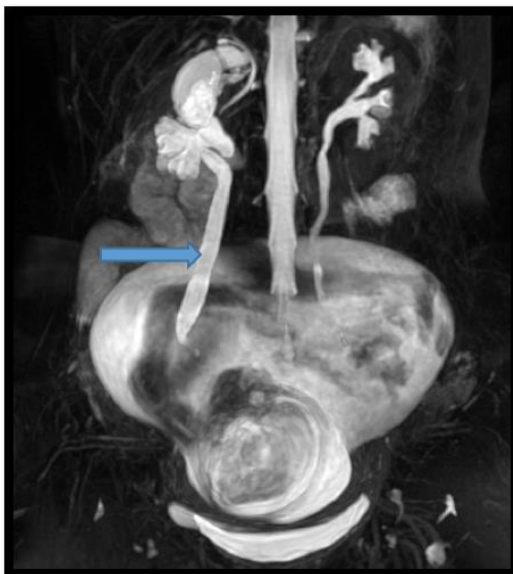


Fig. 1: A case of physiological dilatation in pregnancy. MRI 3D urogram showing right sided hydronephrosis with hydroureter

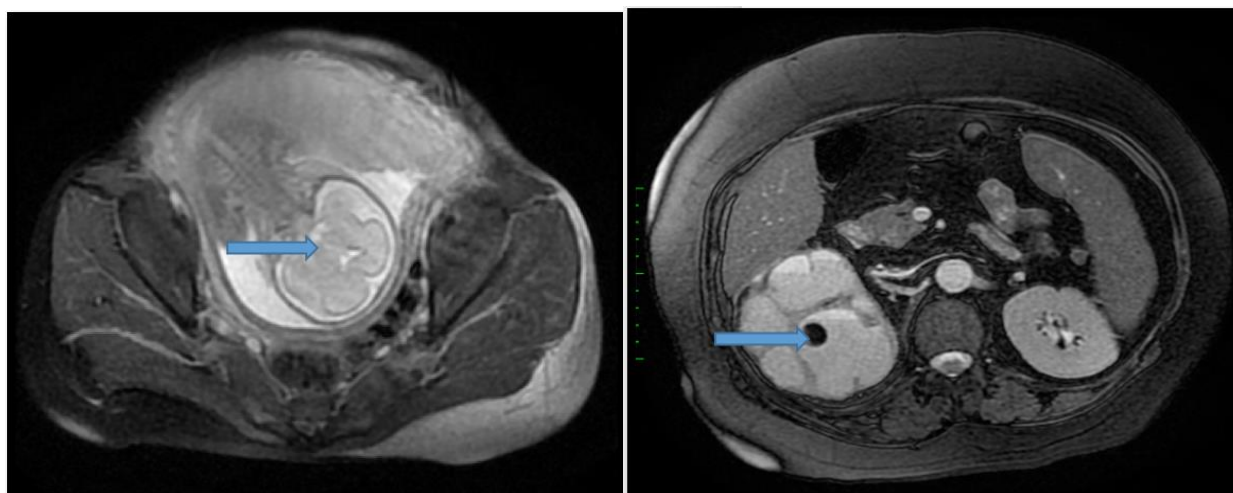


Fig. 2: A case of renal calculus in pregnant patient. MRI T2WI axial images showing gravid uterus (left image) and a filling defect in right kidney - calculus causing hydronephrosis

Hydronephrosis has been noted as survival indicator in advanced cases of cervical cancer.¹⁴ It is frequently observed as a complication in cervical cancer patients. Large tumor mass, enlarged lymph nodes or inflammation in these patients result in hydronephrosis. Various studies demonstrate that hydronephrosis is a cancer-related or cancer treatment-related complication. And is associated with notable morbidity and shortened survival.¹⁵ Few articles suggested that hydronephrosis can occur in patients after surgery where no trauma to urinary system was noted.¹⁶ We had included 9 patients of cervical cancer in our study out of which one patient was having hydronephrosis post-surgery. Most common imaging finding seen in these patients was bilateral hydronephrosis along with hydroureter (Fig. 3). 3 cases

showed unilateral hydronephrosis (Fig. 4). We had performed MR urography sequences in these patients along with routine imaging sequences of pelvis.

Another causes of hydronephrosis we came across in our study were large ovarian tumor. Hydronephrosis was due to compression of ureter by large lesion. Similar was true with fibroid. We did not perform separate MR urography in these patients. MR urography sequences were taken along with routine pelvic MR imaging sequences. We also advise same procedure for imaging in these type of patients. There is no need to perform separate MR urography procedure, just take necessary urography sequences along with routine MRI sequences.

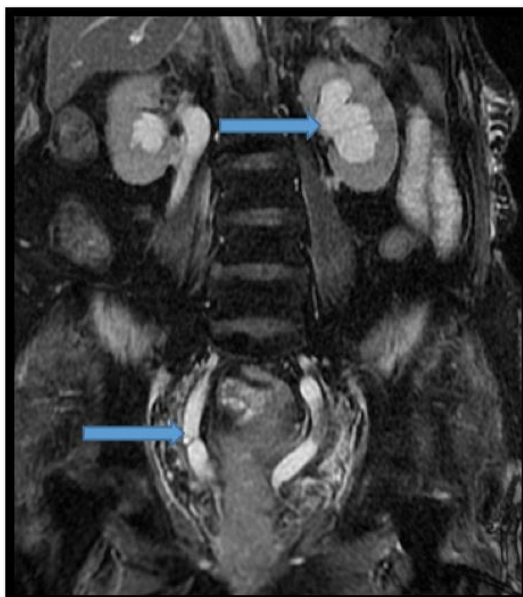


Fig. 3: A case of carcinoma of cervix. MRI Cor. T2WI showing mass in cervical region causing bilateral hydronephrosis with hydroureter

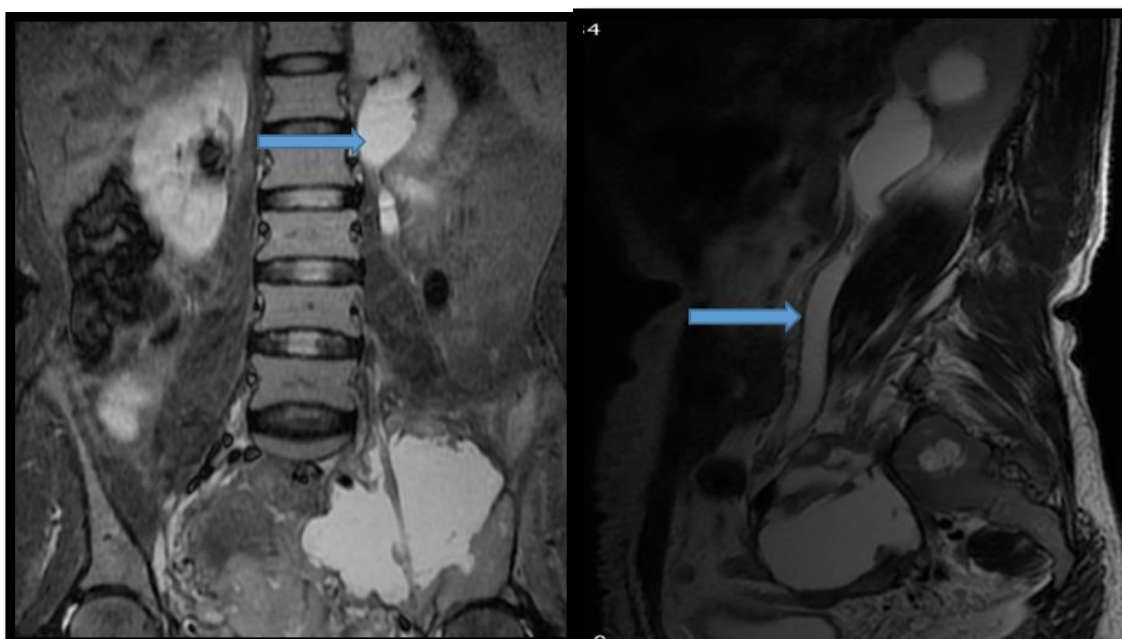


Fig. 4: Another case of carcinoma of cervix. MRI Cor. and Sag. T2WI showing mass in cervical region causing left side hydronephrosis with hydroureter

MR Urography delivered highest accuracy to demonstrate the cause, level and degree of obstruction and hydroureteronephrosis. MRU provided Information about structure, function and integrity of the urinary tract, along with identification of neoplasm and its involvement in adjacent structures. So, MRU is a better modality for evaluation of malignant as well as benign causes of obstruction due to its multi planar capability and superior soft tissue contrast. Thus, in patients with clinical features of Hydronephrosis, screening should be done with transabdominal sonography which can detect level of hydronephrosis and any abnormality if present. USG is a cost

effective and easily available method of imaging. Overall MRU is more sensitive and accurate than USG for diagnosing the cause of obstruction. So, MRU should be done to detect exact cause of obstructive uropathy, for better delineation of the abnormality, information about structure, function and integrity of the urinary tract. It could be the imaging modality of choice in patients at risk of radiation like young females and pregnant women.

Conclusion

We can conclude that MR urography is an efficient and safe method of assessment of hydronephrosis in pregnancy

and carcinoma patients due its excellent soft tissue differentiation and lack of ionising radiation. Given its accessibility, lower cost and ease of interpretability, the role of USG as a first-line modality in the workup of hydronephrosis is still indicated. Cost and availability may remain the drawbacks of MR urography, still it should be indicated as second line diagnostic test when Ultrasonography fails to determine exact etiology of Hydronephrosis.

Conflict of Interest: None.

References

- Murnaghan GF. The Physiology of Hydronephrosis. *Postgrad Med J* 1958;34(389):143-148.
- Waltzer WC. The urinary tract in pregnancy. *J Urol* 1981;125:271-276.
- Cietak KA, Newton JR. Serial qualitative maternal nephrosonography in pregnancy. *Br J Radiol* 1985;58:399-404.
- Puskar D, Balagovic I, Filipovic A. Symptomatic physiologic hydronephrosis in pregnancy. *Eur Urol* 2001;39:260-263.
- Atuhairwe S, Busingye RB, Sekikubo M, Nakimuli A, Mutyaba T. Urologic complications among women with advanced cervical cancer at a tertiary referral hospital in Uganda. *Int J Gynecol Obstet* 2011;115:282-284.
- Hazewinkel MH, Gietelink L, van der Velden J. Renal ultrasound to detect hydronephrosis: a need for routine imaging after radical hysterectomy? *Gynecol Oncol* 2012;124:83-86.
- Paick SH, Oh SY, Kim HH. The natural history of hydronephrosis after radical hysterectomy with no interoperatively recognizable injury to the ureter: a prospective study. *BJU Int* 2003;92:748-750.
- Morris M, Eifel PJ, Grisby PW. Pelvic radiation with concurrent chemotherapy compared with pelvic and para-aortic radiation for high-risk cervical cancer. *N Engl J Med* 1999;340:137-143.
- Leyendecker JR, Barnes CE, Zagoria RJ. MR Urography: techniques and clinical applications. *Radiographics Jan* 2008;28(1):23-25.
- Abou El-Ghar ME, Shokier AA, Refaie H, El-Diasty TA. MRI in patients with chronic obstructive uropathy and compromised renal function: a sole method for morphological and functional assessment. *Br J Radiol* 2008;81(968):624-629.
- Rasmussen PE, Nielsen FR. Hydronephrosis during pregnancy: a literature survey. *Eur J Obstet Gynecol Reprod Biol* 1988;27(3):249-259.
- Haller H, Mozetic V, Topljak-Polik D. Management and complications of urolithiasis during pregnancy. *Int J Gynaecol Obstet* 1993;40:135-139.
- Roy C, Saussine C, Le Bras Y. Assessment of painful uretero-hydronephrosis during pregnancy. *Eur Radiol* 1996;6:334-338.
- Pradham TS, Duan H, Katsoulakis E. Hydronephrosis as a prognostic indicator of survival in advanced cervix cancer. *Int J Gynecol Cancer* 2011;21:1091-1096.
- Wit EMK, Horenblas W. Urological complications after treatment of cervical cancer. *Nat Rev Urol* 2014;11:110-117.
- Suprasert P, Euathrongchit J, Suryachai P. Hydronephrosis after radical hysterectomy: a prospective study. *Asian Pac J Cancer Prev* 2009;10:375-378.

How to cite this article: Kadam D, Patil S, Jain M. Assessment of hydronephrosis in obstetrics and gynaecology patients: - Most useful application of MR urography. *Indian J Obstet Gynecol Res* 2019;6(1):46-50.