

## Retinal thickness in diabetic macular edema: A study using optical coherence tomography (OCT)

Rajasekar Mohan Metri<sup>1</sup>, Ashwini K G<sup>2,\*</sup>, Ganashree C P<sup>3</sup>, Amrutha A M<sup>4</sup>, Vijayalakshmi Mangasuli<sup>5</sup>

<sup>1,3</sup>Associate Professor, <sup>2</sup>Senior Resident, <sup>4,5</sup>Assistant Professor, <sup>1,2</sup>Dept. of Ophthalmology, <sup>3</sup>Dept. of Physiology, <sup>4,5</sup>Dept. of Community Medicine, Basaveshwara Medical College & Hospital, Chitradurga, Karnataka, India

**\*Corresponding Author: Ashwini K G**

Email: ashwinikg89@gmail.com

### Abstract

**Introduction:** Macular edema is the most frequent cause of visual impairment in patients with Nonproliferative Diabetic Retinopathy (NPDR). Clinically they are differentiated as focal and diffuse. Optical coherence tomography (OCT) can measure the retinal thickness and assess the response of surgery. This study was done to evaluate the efficacy of OCT as an investigative tool in diabetic macular edema.

**Materials and Methods:** A prospective study was done among 30 consecutive eyes with Clinically Significant Macular Edema (CSME) over 8 months in our institution and divided into two groups with 15 each as focal and diffuse on the basis of fundus bio-microscopy and fluorescein angiography. Baseline measurements were done by OCT. Patients were followed up after surgery at 4 weeks and 12 weeks with repeat measurements. Data entered in excel sheet and analyzed using SPSS software. Data presented as tables and graphs with Spearman's correlation and Paired t test.

**Results:** Among 15 eyes with focal macular edema mean age of patients was  $59.80 \pm 5.13$  years whereas among diffuse macular edema, it was  $67.80 \pm 3.76$  years. There was negative correlation between BCVA and FOVb among both the groups which was significant. ( $p=0.033$ ,  $p<0.01$ ). When Best corrected visual acuity, central foveal thickness, perifoveal thickness, maximum retinal thickness and total macular volume were compared at baseline, 4 weeks and 12 weeks after surgery, it was found that OCT was effective investigative tool in case of diabetic macular edema to assess the response of surgery.

**Conclusion:** Optical coherence tomography is a useful modality of investigation in patients with diabetic macular edema. Thus OCT can be used for quantitative assessment in response to surgery.

**Keywords:** Diabetes, Investigative tool, Macular edema, Retinal thickness.

### Introduction

Diabetic macular edema is a leading cause of moderate visual loss amongst diabetics.<sup>1</sup> It is also the second most common cause of severe visual loss in diabetics after proliferative diabetic retinopathy (PDR).

Macular edema is the most frequent cause of visual impairment in patients with Nonproliferative Diabetic Retinopathy (NPDR). However, the breakdown of endothelial tight junctions and loss of blood retinal barrier can be associated with NPDR and PDR. It is clinically defined only when retinal thickening is noted on stereoscopic examination methods i.e. slit lamp bio-microscopy during the clinical examination, either with a contact or hand-held lens.<sup>2,3</sup>

Clinically, diabetic macular edema can be differentiated as.

1. Focal diabetic macular edema - visible micro-aneurysms within the macular area associated with micro-aneurysms that leak and also, hard exudates formed by leaking plasma.
2. Diffuse diabetic macular edema – 2 or more disc area of retinal thickness involving foveal avascular zone with or without cystoids.

Diabetic Macular edema is managed in three ways:

1. Intensive Glycemic control.
2. Control of associated condition such as hypertension and hyperlipidemia.
3. Laser photocoagulation.

Optical coherence tomography<sup>4</sup> is a new diagnostic technology for high resolution cross sectional, quantitative (objective) imaging of the human retina. OCT can maintain

high depth resolution even when the available aperture is small. This accounts for its exceptionally high resolution (approximately  $10 \mu$ ). The OCT system performs multiple longitudinal scans at a series of lateral locations to provide a two dimensional map of the reflection sites.

**Lacunae in Knowledge:** At the time of the initiation of study there was only one report in literature measuring retinal thickness using OCT findings in evaluation of response of photocoagulation for macular edema.<sup>5</sup> However, no prospective trials had been conducted to know the response of focal and diffuse diabetic edema separately to frequency doubled Nd: YAG.

We conducted this study to evaluate the efficacy of OCT as an investigative tool in diabetic macular edema in respect to quantitative assessment of retinal thickness.

### Materials and Methods

**Patients:** A total of 30 consecutive patients with NPDR with CSME were recruited from our outpatient department over 8 months and they were divided into 2 groups, on the basis of fundus biomicroscopy and fluorescein angiography. Group I: 15 eyes of focal diabetic edema  
Group II: 15 eyes of diffuse diabetic edema

Inclusion criteria were patients with type II diabetes mellitus having NPDR with CSME on slit lamp biomicroscopy with 90D with focal / diffuse leak on fluorescein angiography. Exclusion criteria were pregnancy, PDR, history of previous laser therapy, uncontrolled HTN, renal disease, patients with epi-retinal membrane, pseudophakic macular edema and macular edema secondary

to central or branch vein occlusion or any other diseases of the eye that can have an effect on vision like ARMD etc. Informed consent was obtained before inclusion and the study was performed in accordance with common ethical standards. A standard eye examination including best-corrected visual acuity (ETDRS chart), slit-lamp biomicroscopy (90-diopter [D]lens), clinical fundus photography, fluorescein angiography and retinal thickness with OCT was done. The blood level of glycosylated hemoglobin (HBA1c), FBS, PPBS was determined to assess the quality of blood sugar control. Patients were followed up at 4 weeks and 12 weeks after surgery.

**Optical Coherence Tomography:** Patients underwent axial length measurements and estimation of refractive error as prerequisites to the documentation of OCT. OCT evaluation was carried in Humphrey Zeiss Stratus 3.0. Patients were briefed about the procedure and consent was taken.

Patient details were fed to the computer. The scan image was optimized. Fast macular thickness type of scan mode was selected with 6 radial scans of 6 mm at 30° interscan distances taken in each eye which was to be

evaluated. Retinal thickness/volume tabular output analysis protocol was used to analyze the retinal thickness.

Retinal scan images were acquired from the retinal map analysis protocol.

**Statistics Analysis**

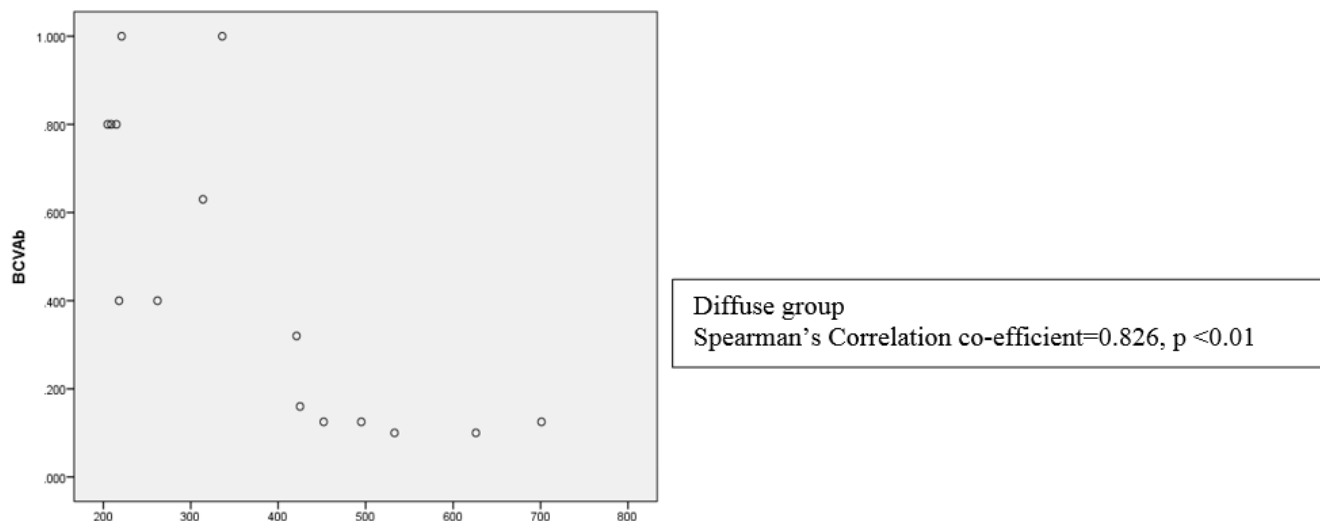
The data were entered in a Microsoft excel spreadsheet and analyzed using SPSS software. The demographical data was analyzed with descriptive and the correlations by Spearman’s correlation. The main effects of the repeated measures were analyzed on a general linear model, comparing with confidence interval adjustment being done by Bonferroni method. Means were compared by using Paired t test.

**Results**

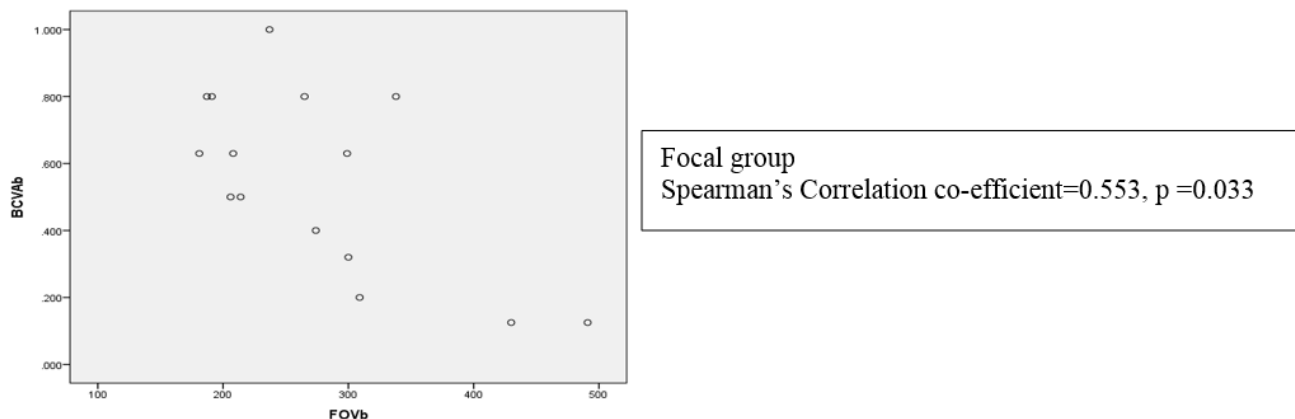
Among 15 eyes with focal macular edema mean age of patients was 59.80 ± 5.13 years ranging from 53-70yrs. Whereas among diffuse macular edema, it was 67.80 ± 3.76 years, ranging from 53 – 68 years. (Table 1)

**Table 1: Socio-demographic determinants of study participants**

Socio-demographic variable		Focal	Diffuse
Age(Mean ± SD)		59.80 ± 5.13 yrs	67.80 ± 3.76 yrs
Gender	Male	12 (80%)	14 (93.33%)
	Female	3 (20%)	1 (6.67%)



**Fig. 1: Correlation between BCVA and FOVb of diffuse macular edema patients**



**Fig. 2: Correlation between BCVA and FOVb of focal macular edema patients**

In both the groups there was negative correlation between BCVA and FOVb which was significant. (Fig. 1 and 2)

The retinal thickness in each area was noted and the area in which there was maximum retinal thickness was marked for each individual patient. Among diffuse group temporal inner macula was the most commonly involved area where the retina was maximally thickened with 27% of

patients having maximum thickness in this area followed by fovea where 20% of patients had maximum thickness of retina in this area. Where-as among focal group superior inner macula was the most commonly involved area where the retina was maximally thickened with 34% of patients having maximum thickness in this area followed by nasal inner macula where 20% of patients had maximum thickness of retina in this area.

**Table 2: OCT measurements among patients with focal macular edema**

Focal Macular Edema	BCVA (mean)	Central foveal thickness (mean microns)	Peri-foveal thickness (mean microns)	Maximum retinal thickness (mean microns)	Total macular volume(mean cumm)
Baseline	0.55	275	282	342	7.83
4 weeks	0.58	298	291	338	7.83
12 weeks	0.69	296	284	322	7.63
p value (baseline and 4 weeks, baseline and 12 weeks)	(0.52, 0.74)	(0.28, 0.96)	(0.349, 1.0)	(1.0, 0.677)	(1.0, 1.0)

**Table 3: OCT measurements among patients with diffuse macular edema**

Diffuse Macular Edema	BCVA (mean)	Central foveal thickness (mean microns)	Peri-foveal thickness (mean microns)	Maximum retinal thickness (mean microns)	Total macular volume(mean cumm)
Baseline	0.46	376	354	450	9.56
4 weeks	0.42	368	331	392	8.86
12 weeks	0.49	307	308	351	8.49
p value (baseline and 4 weeks, baseline and 12 weeks)	(1.0, 1.0)	(1.0, 0.06)	(1.0, 0.06)	(0.135, 0.018)	(0.281, 0.89)

When Best corrected visual acuity, central foveal thickness, perifoveal thickness, maximum retinal thickness and total macular volume were compared at baseline, 4 weeks and 12 weeks after surgery, it was found that OCT was effective investigative tool in case of diabetic macular edema to assess the response of surgery. (Table 2 and 3)

**Discussion**

In our study, the patients were subjected to retinal thickness evaluation at prior to laser photocoagulation and then at 1 and 3 months after the treatment. The follow up period of the study conducted by Rivellesse M et al<sup>5</sup> was 12-18 weeks, Shilelattanizio et al<sup>6</sup> had a follow up period of more than 3 months. The prospective study by Masahiko

Shimura et al<sup>7</sup> had a follow up of 6 months, while Laursen M L et al<sup>8</sup> had retinal thickness evaluated at 3 and 6 months.

Patients with diabetic macular edema have shown correlation coefficients between visual acuity and central foveal thickness ( $p < 0.001$ ). Our study also confirmed the correlation ( $p = 0.001$ ). However, Laursen M L<sup>8</sup> et al could not find such a correlation ( $p = 0.37$ ). Some patients had stabilized or even improved visual acuity in spite of an increase in central foveal thickness when individual patients were analyzed in our study and as well in study by Laursen M L et al.<sup>8</sup> This incites need for further work on the understanding of the concept in relation to each layer of the retina at the fovea. Such an effort is possible as optical coherence tomography provides high resolution cross sectional images of the retina.

All previous studies had measured retinal thickness in the central fovea. Rivellese M et al<sup>5</sup> found that the average central foveal thickness for all prior to laser photocoagulation was  $368 \mu$  and post treatment central foveal thickness was  $276 \mu$ . The Percentage decrease in the central foveal thickness would therefore be 25% Lattazio R et al<sup>6</sup> also noted that the central foveal thickness before and after treatment was  $468.2 + 83.17 \mu$  and  $372.1 + 120.63 \mu$ . This would account for a decrease of 20.5%.

In the study by Masahiko Shimura et al,<sup>7</sup> there was a decrease in the mean central foveal thickness with thickness before laser therapy being  $534.7 \pm 120 \mu$  and that after 6 Months of laser therapy found to be  $286.9 \pm 98.6 \mu$ , which corresponded to a decrease of  $45.4\% \pm 17.1\%$  Laursen M L et al<sup>8</sup> the central foveal thickness at baseline was  $293 \pm 43 \mu$  and following laser therapy the central foveal thickness was  $318 \pm 74 \mu$  and  $341 \pm 81 \mu$  at 3 and 6 months respectively.

## Conclusion

Optical coherence tomography is a useful modality of investigation in patients with diabetic macular edema. Thus OCT can be used for quantitative assessment in response to surgery.

**Conflict of Interest:** None.

## References

1. Klein R, Klein BE, Moss SE. Visual impairment in diabetes. *Ophthalmol* 1984;91:1-9.
2. Early Treatment Diabetic Retinopathy Study Research Group. ETDRS report number 10. Grading diabetic retinopathy from stereoscopic color fundus photographs—an extension of the Modified Airlie House classification. *Ophthalmol* 1991;98:786-806.
3. Early Treatment Diabetic Retinopathy Study Research Group. Fluorescein angiographic risk factors for progression of diabetic retinopathy. ETDRS report number 13. *Ophthalmol* 1991;98:834-840.
4. Huang D, Puliafito CA, Fujimoto JG. Optical coherence tomography. *Sci* 1991;25:1178-1181.
5. Rivellese M, George A, Puliafito C. Optical coherence tomography after laser photocoagulation for clinically significant macular edema. *Ophthalmic Surg Lasers* 2000;31:192-197.
6. Lattanzio R, Brancato R, Pierro L. Macular thickness measured by optical coherence tomography (OCT) in diabetic patients. *Eur J Ophthalmol* 2002;12(6):482-487.
7. Shimura M, Yasuda K, Nakazawa T. Effective treatment of diffuse diabetic macular edema by temporal grid pattern photocoagulation. *Ophthalmic Surg Lasers Imaging* 2004;35(4):270-280.
8. Laursen ML, Moeller F, Sander B. Subthreshold micropulse diode laser treatment in diabetic macular edema. *Br J Ophthalmol* 2004;88(9):1173-1179.

**How to cite this article:** Metri RM, Ashwini KG, Ganashree CP, Amrutha AM, Mangasuli V. Retinal thickness in diabetic macular edema: A study using optical coherence tomography (OCT). *Indian J Clin Exp Ophthalmol* 2019;5(1):8-11.