

A comparative study of complications and its management following phacotrabeculectomy in primary open angle glaucoma, primary angle closure glaucoma and pseudo-exfoliative glaucoma with cataract

Kaiyoor Surya Divyalakshmi^{1*}, Rengappa Ramakrishna²

¹Assistant Professor, ²Chief Medical Officer, Dept. of Ophthalmology, ¹Yenepoya Medical College, Mangaluru, Karnataka, ²Aravind Eye Hospital, Tirunelveli, Tamil Nadu, India

*Corresponding Author: Kaiyoor Surya Divyalakshmi

Email: divyalakshmikns2002@yahoo.com

Abstract

Introduction: Glaucoma is a progressive optic neuropathy with characteristic optic disc and visual field changes. Major types include primary open angle and primary closed angle glaucoma. Cataract is a progressive degeneration of crystalline lens resulting in its opacification. Incidence of concurrent cataract and glaucoma is increasing. Combined cataract and glaucoma surgery i.e Phacotrabeculectomy can be considered in these cases. Intraoperative and postoperative complications are known in combined surgeries. Comparison of complications and its management in 3 different types of glaucoma undergoing phacotrabeculectomy will be done.

Materials and Methods: In this study, 90 eyes with cataract were divided into three groups, group A with POAG, group B with PACG, and group C with PXFG. All patients underwent phacotrabeculectomy by a single surgeon. Intraoperative and post-operative complications at 1 day, 1 week, 1 month, 3 months and 6 months were documented. Management of the complications were also noted.

Results: No significant difference was seen in the three groups with respect to complications except at 1 month when high IOP was noted in POAG and PACG, which was statistically significant ($p < 0.05$). All these cases underwent Argon suture lysis. One case of bleb failure due to late fibrosis was noted each in angle closure and pseudo-exfoliation group at 6 months follow up, which was not statistically significant.

Conclusion: No significant difference was noted in the rate of intraoperative and post-operative complications between 3 types of glaucoma following phacotrabeculectomy. This study shows that phacotrabeculectomy might be used as safe surgery in patients having co-existent cataract and glaucoma.

Keywords: Cataract, Complications, Glaucoma, Phacotrabeculectomy.

Introduction

Glaucoma is a progressive optic neuropathy with characteristic changes in the optic nerve head¹ and visual field changes. It can result in irreversible damage from death of retinal ganglion cells. In a rural population study in South India, the Prevalence of Glaucoma of any type has been estimated as 2.6%, with POAG accounting for 1.2% of cases, PACG 0.5% and 2 PXFG 0.4%.² Visually significant cataract and glaucoma can coexist. In such cases both conditions may have to be tackled simultaneously. For simultaneous surgical management of cataract and glaucoma, phacotrabeculectomy is often the treatment of choice.³⁻⁷ Complications of combined cataract and trabeculectomy includes intraoperatively button holing of conjunctiva, hyphema, positive vitreous pressure, iridodialysis, residual cortex, nucleus dislocation into vitreous, vitreous loss, expulsive haemorrhage, zonular dialysis and failure to implant posterior chamber intraocular lens. Post-operative complications includes in early phase corneal edema, shallow anterior chamber, iritis, hyphema, iris prolapse, pupillary capture, wound leak, residual cortex, pupillary block glaucoma, choroidal detachment, IOL decentration. Late complications include endophthalmitis, posterior capsular opacification, cystoid macular oedema, hypotony, bleb failure & increased IOP.⁸ Our study aims at comparing the complications and its management in 3 different groups of glaucoma.

Materials and Methods

A prospective, comparative, interventional study was done from November 2008 to October 2009 in a tertiary care center in South Tamilnadu. Patients with POAG, PACG (sub acute and chronic angle closure, post peripheral iridectomy) and PXFG, with visually significant cataract were included. All cases were divided into 3 groups. Group A- POAG, Group B - PACG and Group C- PXFG. Patients with history of previous ocular procedures, laser trabeculoplasty, secondary glaucoma, complicated cataracts and subluxated lens, mature and hyper mature cataract; corneal opacity, conjunctival inflammation, age-related maculopathy, high myopia, and diabetic maculopathy were excluded. 90 eyes of 90 patients who satisfied above said criteria included in the study. All patients underwent baseline BCVA, Slit lamp examination, Applanation tonometry, Gonioscopy, Fundus examination, Visual fields (HFA 24-2 SITA STANDARD) and Biometry. After approval of Ethics Committee of Aravind Eye Care System, written, informed consent was taken. All patients underwent phacotrabeculectomy by a single experienced surgeon. The technique of phacotrabeculectomy was similar in all groups. All cases were reviewed and followed up for a period of 6 months with 5 post-operative follow-ups (1 day, 1 week, 1 month, 3 month, 6 month).

Intra-operative complications if any and its management, post-operative complications and

interventions like argon laser suturolysis (ALS), release of sutures, bleb needling were documented.

Statistical percentage, mean and standard deviations were used for analysis wherever necessary. Analysis was performed by the statistical package SPSS (13.0) at 5% level of significance ($p=0.05$) using ANOVA and test of proportions.

Results

90 eyes of 90 cases were included. Intra-operative complications were few. 2 eyes with PACG and 1 eye with PXFG had posterior capsular dehiscence, 1 eye in PXFG group had zonular dialysis needing intraoperative capsule tension ring (CTR) placement (Fig. 1). Posterior capsule rupture was managed by anterior vitrectomy and foldable three piece intra-ocular lens was placed in the bag.

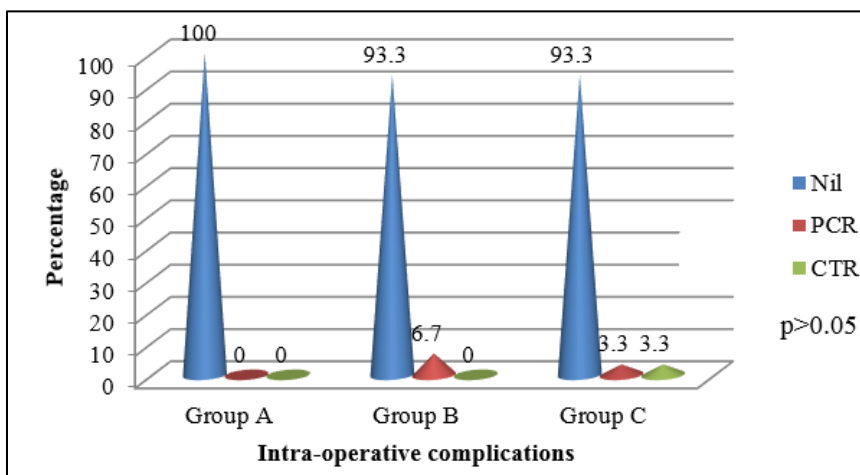


Fig. 1: Intra-operative complications

At 1 day post-operatively, 1 eye (3.3%) in group C had shallow anterior chamber and was managed by cycloplegics and tight pad and bandage. 1 eye (3.3%) in group A and 2 eyes (6.7%) in group B had high intraocular pressure due to tight sutures and were managed by release of releasable

sutures. 2 eyes (6.7%) in group B and 1 eye (3.3%) in group C had severe corneal edema and were managed by intravenous administration of Mannitol. 1 eye (3.3%) in group A had severe anterior chamber reaction and striae keratitis, and 3 eyes (10%) in group C had striae keratitis. They were managed with systemic steroids.

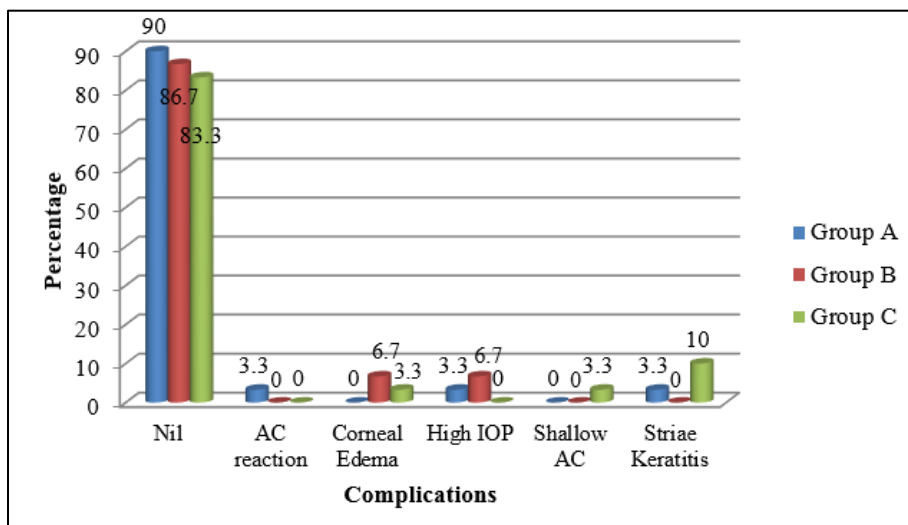


Fig. 2a: Complications at 1 day post - operatively

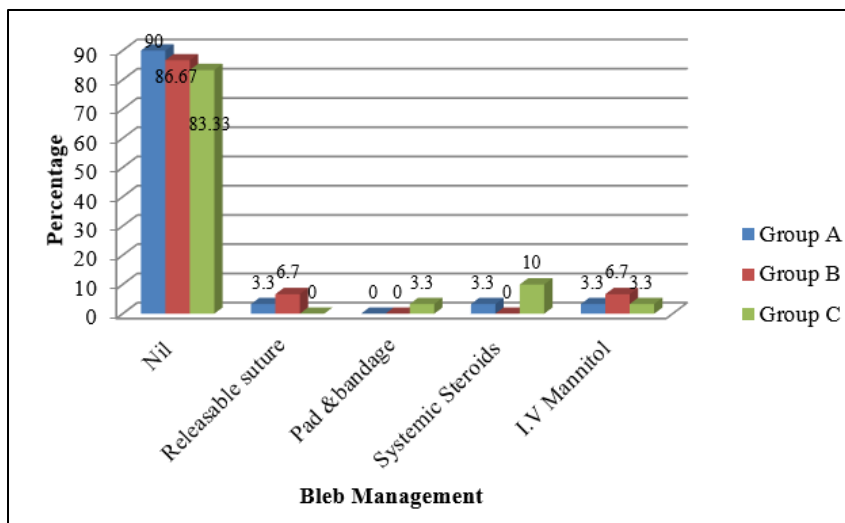


Fig. 2b: Bleb management 1 day post operatively

At 1 week post-operatively, 1 eye (3.3%) in group A and 2 eyes (6.7%) in group C developed choroidal detachment and were managed by administration of oral steroids. 8 eyes (26.7%) in group A, 9 eyes (30%) in group B and 7 eyes (23.3%) in group C had high Intraocular pressure. 2 eyes in group A were observed without any bleb

intervention. Other eyes underwent argon laser suturolysis. 4 eyes (13.3%) in group B showed a flat bleb and were effectively managed by release of releasable sutures. 1 eye (3.3%) in group A showed a mild bleb leak and was managed by bandaging.

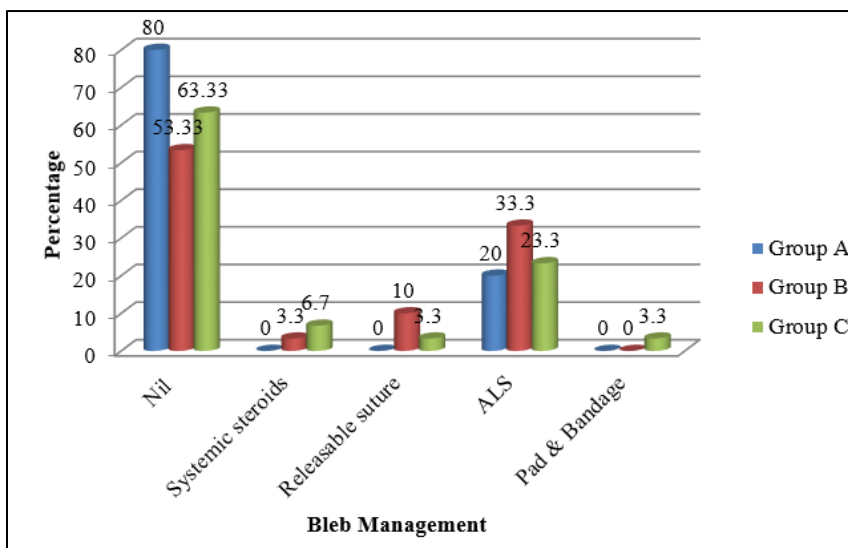


Fig. 3b: Bleb Management at 1 week post operatively

At 1 month postoperatively 10 eyes (33.3%) in group A, 5 eyes (16.7%) in group B and 2 eyes (6.7%) in group C had high Intraocular pressure. 6 eyes (20%) and 3 eyes (10%) in group A who had high Intraocular pressure were managed by argon laser suturolysis and release of releasable sutures respectively. Other 2 eyes (6.7%) were started on topical anti-glaucoma medications. 5 eyes (16.7%) in group

B who had high Intraocular pressure underwent argon laser suturolysis. Other 4 eyes (13.3%) that developed a flat bleb and had already undergone bleb intervention in the last visit were managed conservatively. 2 eyes (6.7%) who had high IOP and 1 eye (3.3%) with a flat bleb in group C were effectively managed by argon laser suturolysis and release of releasable sutures respectively.

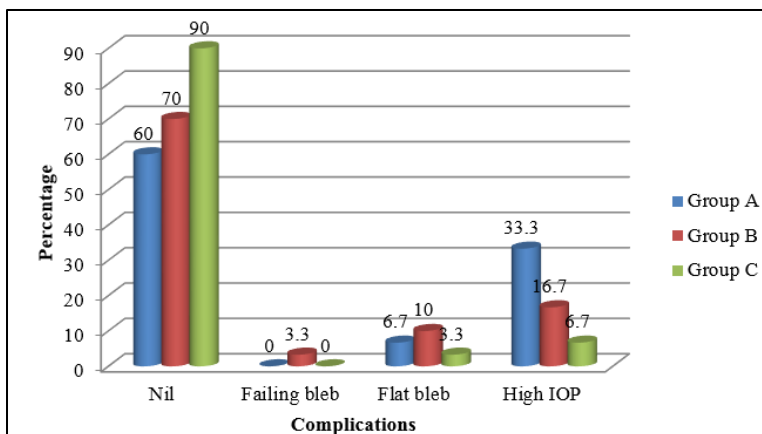


Fig. 4a: Complications at 1 month post operatively

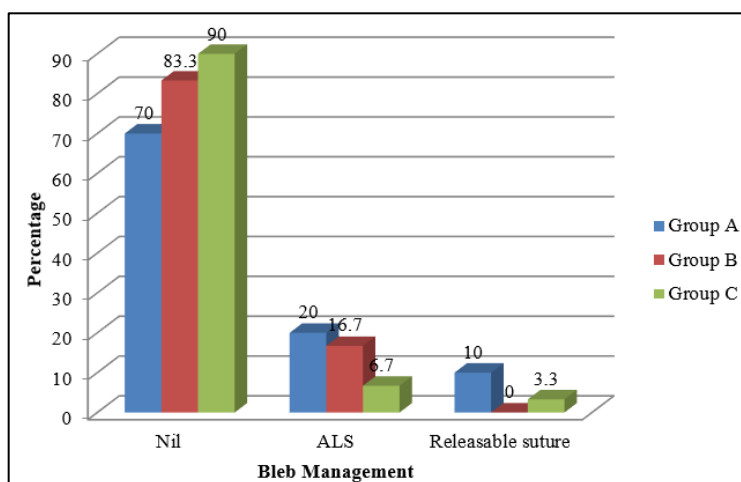


Fig. 4b: Bleb management at 1 month post operatively

At 3 month postoperatively 1 eye (3.3%) in group B had a blocked ostium and underwent Nd:YAG internal revision of the bleb. 1 eye (3.3%) in group C developed a Tenon cyst and underwent bleb needling with intraoperative 5-Flurouracil. 1 eye (3.3%) in group A developed cystoid macular edema and was managed by posterior sub-Tenon

injection of steroids. 1 eye (3.3%) each in group A, group B and group C had high Intraocular pressure and were managed conservatively with topical anti-glaucoma medications. 3 eyes (10%) each in group A and group B and 1eye (3.3%) in group C had a failing bleb and were managed conservatively with topical anti-glaucoma medications.

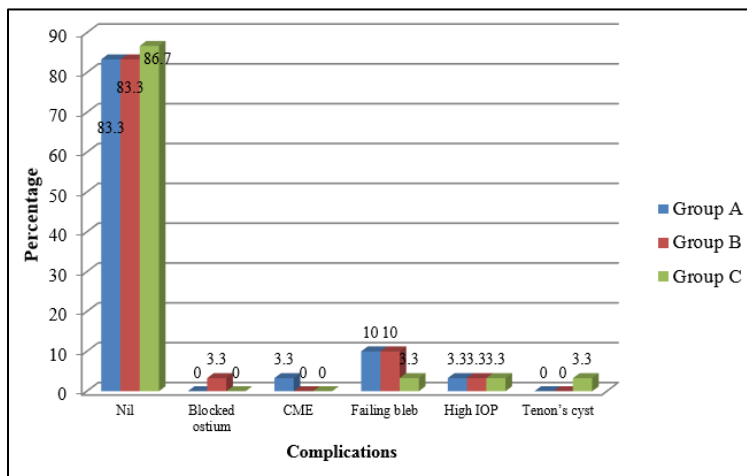


Fig. 5a: Complications at 3 month post operatively

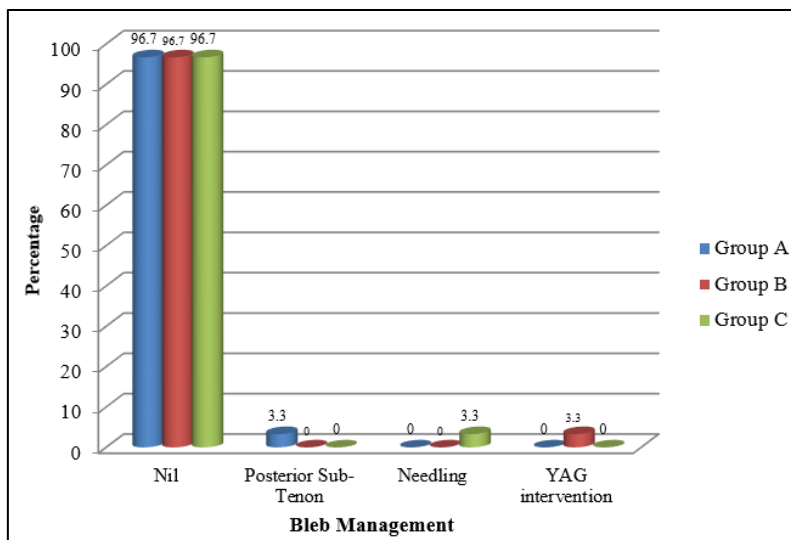


Fig. 5b: Bleb management at 3 month post operatively

At 6 month postoperatively, in 1 eye (3.3%) each in group B and group C, failure of the filtering bleb was seen. They were managed conservatively with topical anti-glaucoma medications. 3 eyes (10%) in group A and 2 eyes (6.7%) in group B had flat blebs and were managed with topical anti-glaucoma medications. 1 eye (3.3%) each in

group A and group B had high IOP and was managed with topical anti-glaucoma medications. 1 eye (3.3%) in group C continued to have a Tenon cyst inspite of bleb needling. It was also managed conservatively with topical anti-glaucoma medications. No interventions were made at 6-month follow-up in any of the 3 groups.

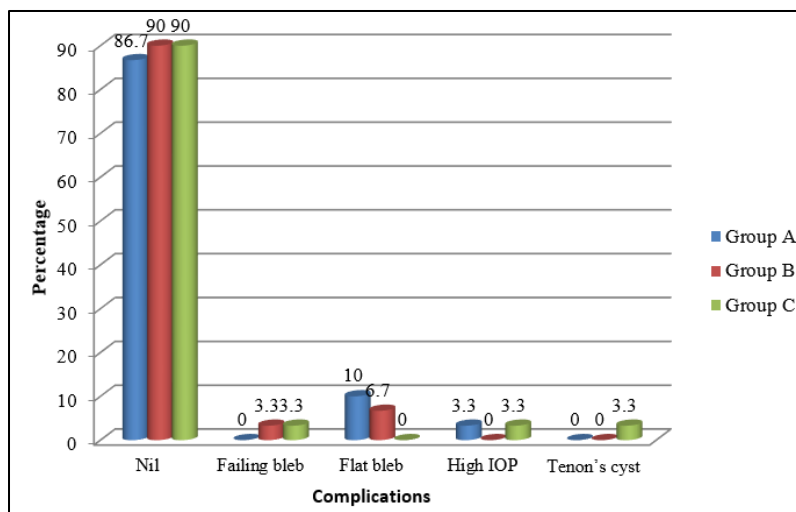


Fig. 6: Complications at 6 month post operatively

Discussion

Our study was aimed at comparing intraoperative and post-operative complications of phacotrabeculectomy in three different types of glaucoma with cataract. 4 (4.44%) patients of PACG and PXFG had intra-operative complications i.e posterior capsule dehiscence and zonular dialysis. Similar to our study, Landa G et al⁹ did not report any significant difference in the complication rate between PXFG and non-PXFG, although more frequent transition to ECCE was noted in PXF group.

At 1-week follow-up, 2 eyes (6.7%) in pseudo-exfoliation group and 1 eye (3.3%) in angle closure glaucoma group had shallow anterior chamber with

choroidal detachment. They were effectively managed with systemic steroids, which resolved in one week. There was no significant difference in early postoperative complications between the three groups, as also noted by Namrata D, M Bhaskaran et al.¹⁰ In their study they reported no significant difference in the early complication rate between primary open angle glaucoma and angle closure glaucoma. However 3 eyes required early surgical intervention. Anterior chamber reformation was done in 3 eyes with shallow anterior chamber and choroidal effusion. 1 eye with Hemorrhagic choroidal detachment needed Choroidal drainage. Anterior chamber wash was done in 1 eye with Hyphema. Most common intervention performed was anterior chamber reformation. G Venkatraman et al,¹¹

in their study reported shallow anterior chamber and choroidal detachment as the most common complication.

Post-operatively, laser suturolysis was done in 20%, 33.3% and 23.3% at 1 week and 20%, 16.7% and 6.7% at 1-month follow-up in primary open angle glaucoma, angle closure glaucoma and pseudo-exfoliation glaucoma respectively and showed statistically significant difference.

At 3 month follow up 1 eye (3.3%) in angle closure glaucoma group had blocked ostium, and was treated with Nd YAG intervention. 1 eye (3.3%) in pseudo-exfoliation group developed Tenon's cyst and bleb needling with 5-fluorouracil was done. Borggreffe et al¹² reported an overall 6% eyes requiring needling of the bleb. There was one case of failure due to late fibrosis of the bleb each in angle closure glaucoma group and pseudo-exfoliation glaucoma group. No surgical intervention was done and patient was started on topical antiglaucoma medication.

Conclusion

The excellent results achieved in the three different groups of glaucoma imply that the technique of phacotrabeculectomy might be used as a safe procedure to safely manage cases of concurrent cataract and glaucoma. There has been no significant difference in the rate of intraoperative complications between pseudo-exfoliation glaucoma and eyes with other types of glaucoma, although complications are expected to be more in pseudoexfoliation glaucoma. Refinement of surgical technique has made combined procedure a safe option and phacotrabeculectomy as a procedure of choice for patients with co-existent cataract and glaucoma.

Conflict of Interest: None.

References

1. Foster PJ, Burhmann R, Quigley HA, Johnson GJ. The definition and classification of glaucoma in prevalence surveys. *Br J Ophthalmol* 2002;86:238-242.
2. R. Ramakrishnan. Glaucoma in rural population of South India - Aravind Comprehensive Eye Study *Ophthalmology* 110;2003.
3. Park HJ, Weitzman M, Caprioli J. Temporal corneal phacoemulsification combined with superior trabeculectomy; a retrospective case-control study. *Arch Ophthalmol* 1997;15:318-323.
4. El-Sayyad FF, Helal MH, Khalil MM, El-Maghraby MA. Phacotrabeculectomy versus two-stage operation: a matched study. *Ophthalmic Surg Lasers* 1999; 30:260-265
5. Yu CB, Chong NH, Caesar RH. Long-term results of combined cataract and glaucoma surgery versus trabeculectomy alone in low-risk patients. *J Cataract Refract Surg* 1996;22:352-357.
6. Wedrich A, Menapace R, Radax U, Papapanos P. Long-term results of combined trabeculectomy and small incision cataract surgery. *J Cataract Refract Surg* 1995;21:49-54.
7. Song X, Wang W, Yang G. Trabeculectomy combined with phacoemulsification for treatment of glaucoma complicated with cataract]. *Chung Hua Yen Ko Tsa Chih* 2000;36:431-434.
8. Shields MB. Textbook of Glaucoma. 4th edition. Lippincott Williams and Wilkins 1999; 518-527.
9. Landa G. Results of combined phacoemulsification and trabeculectomy with mitomycin-c in pseudoexfoliation versus

non-pseudoexfoliation glaucoma. *Graefe's Arch Clin Exp Ophthalmol* 2005;243:12:1236-1240.

10. Namratha D, M Bhaskaran. Comparison of early postoperative complications for filtering surgery in primary open angle glaucoma and primary angle closure glaucoma. *Asian J Ophthalmol* 2006;8:6: supplement2:336.
11. G Venkatraman. Prospective analysis of phacotrabeculectomy and intraocular lens implantation with mitomycin-c and single releasable suture. *Asian J Ophthalmol* 2006;8:6:supplement2:pg331.
12. Borggreffe J, Lieb W, Grehn F. A prospective randomized comparison of two techniques of combined cataract-glaucoma surgery. *Graefes Arch Clin Exp Ophthalmol* 1999;237:887-892.

How to cite this article: Divyalakshmi KS, Ramakrishna R. A comparative study of complications and its management following phaco- trabeculectomy in primary open angle glaucoma, primary angle closure glaucoma and pseudo-exfoliative glaucoma with cataract. *Indian J Clin Exp Ophthalmol* 2019;5(1):121-126.