

Dental arch and pharyngeal space changes associated with rapid maxillary expansion

Biswas P. P^{1,*}, Hridya K. G², Sonu Thomson P³, Vaisakh R⁴, Subairuddeen⁵

¹Professor and HOD, ²⁻⁵PG Student, Dept. of Orthodontics and Dentofacial Orthopedics, Royal Dental College, Chalissery, Palakkad, Kerala, India

***Corresponding Author: Biswas P. P**

Email: kg_hridya@gmail.com

Abstract

RME is the most routinely used orthopedic procedures in young patients for the correction of transverse maxillary dimensions. It is a skeletal type of expansion that involves the splitting of mid palatal suture and maxillary shelves are moved away from each other. In the present study 5 patients who were treated with RME followed by fixed mechanotherapy were selected. Using pretreatment and post treatment models and cephalograms, the changes in the maxillary arch and airway were assessed. Significant expansion of maxillary arch with positive change in the airway were obtained.

Keywords: Maxillary expansion, Air way changes, Dental arch changes.

Introduction

Constricted maxilla is a common clinical condition faced by the orthodontists. It can be either skeletal or dental origin and it may be due to genetic or environmental factors. Environmental factors responsible for constricted arches include thumb sucking habit, obstructive sleep apnoea, iatrogenic cleft repair, syndromes like Klippel Feil syndrome, Marfans syndrome etc. Problems with transverse deficiency include a deficient middle third of the face which can be manifested by a narrow high arched palate and a poor transverse growth of maxilla. Maxillary constriction can be associated with other problems also, that includes improper occlusion, functional problems due to narrow upper and lower airway and altered tongue posture.

Rapid maxillary expansion (RME) is an orthopedic procedure that has been used routinely in young patients for the correction of maxillary transverse dimension. RME is a skeletal type of expansion that involves the separation of the mid palatal suture and maxillary shelves are moved away from each other. RME basically came within the field of orthodontics, yet its importance takes it into such other surgical disciplines as oral surgery, ENT and plastic surgery. This method was first introduced in 1860 by E. C. Angel. The goal of RME is to split the mid palatal suture, providing an optimum increase in maxillary width. Unilateral or bilateral posterior cross bites involving, anteroposterior discrepancies like class II division I malocclusion with posterior cross bite, class III malocclusion, borderline skeletal and pseudo class III malocclusions with narrow maxillary arches are the main indications for RME. Contraindications include apertognathia, vertical growth pattern, and convex profile, adults with severe anteroposterior and vertical skeletal problems and patients who have completed the pubertal growth spurt. The ideal time to treat a patient with RME is before the attainment of peak in skeletal growth velocity, i.e. under 12 yrs. of age (CVMI Stage I to III, MP3F stage in hand wrist). RME can be either banded or bonded. Banded RME is attached to the teeth by means of bands on first molars and premolars while the bonded RME is

attached with an acrylic cap over the posterior segments which are then bonded to the teeth. Due to the effects of RME on maxillary shelves, there is an increase in dental arch transverse dimensions especially intercanine and inters molar width. There is lowering of palate and decrease in palatal depth, lateral bending of the alveolar process also occurs. Opening of midline between maxillary central incisors and buccal tipping of posterior teeth are also the effects of RME. RME could lead to concurrent expansion of lower arch as much as 4mm in intercanine and 6mm in intermolar width. Furthermore studies have shown that maxillary expansion increases the volume and width of nasal cavity, straightens the nasal septum and reduces the nasal airflow resistance hence improves nasal respiration. It has been reported that RME results in an increase of 4.1 mm in nasal cavity width. Due to the various effects on the physical health of patients, the number of indications for RME has increased dramatically. The main objective of the present study is to determine the airway changes as well as dental arch changes followed by RME.

Material and Methods

In the present study, 5 patients treated with RME followed by fixed appliance therapy were selected.

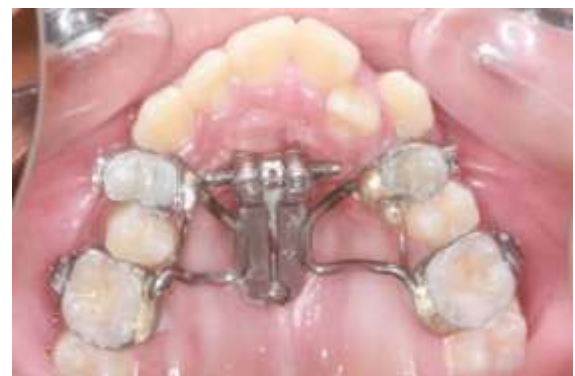

Fig. 1: RME appliance

The inclusion and exclusion criteria's were as follows:

Inclusion Criteria

1. Patients with constricted maxillary arch (below trans palatal width of 35-39mm).
2. Patients who did not receive any previous orthodontic treatment.
3. Patients with no history of dentofacial anomalies.
4. Patients with any history of adenoidectomy/tonsillectomy prior to or during orthodontic treatment.

Exclusion Criteria

1. Patients with missing teeth.
2. Patients who had completed growth.

Measurements done on the Models

Pre-treatment and post treatment casts were used to assess the changes in the following parameters.

1. **Inter canine Width:** Inter canine width was measured from one canine cusp tip to the cusp tip in the contralateral side.¹
2. **Inter Premolar Width:** Inter premolar width was measured from tip of one premolar cusp to the cusp tip on the premolar in the contralateral side.²
3. **Intermolar Width:** Inter molar width is measured from mesial cusp tip of first permanent molar to the cusp tip on the contralateral side.³
4. **Arch Perimeter:** Arch perimeter was measured by passing a brass wire from mesial to the first molar and along the cusp tips of premolars and incisal edges of incisors to the opposite side till the mesial side of first molar on the opposite side.⁴
5. **Arch Length:** Arch length was measured as the perpendicular distance from the labial contact point between two central incisors to a line constructed between contact points mesial to the first permanent molar on either side.⁵
6. Palatal index is measured as a ratio of palatal depth/palatal width which is measured between maxillary first molars.

All the changes were measured with the help of a ruler and a divider.

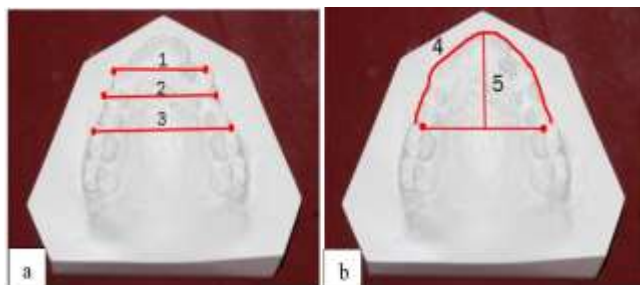


Fig. 2a: Points used for measurements; b: Arch length and arch perimeter

Measurements done on the Cephalogram

Using pre-treatment and post expansion cephalograms, changes in the upper and lower airway were assessed. Upper airway was measured from a point on the posterior outline of the soft palate to the closest point on the pharyngeal wall.⁶

Lower airway was measured from the point of intersection of the posterior border of the tongue and the inferior border of the mandible to the closest point on the posterior pharyngeal wall.^{11,7}

Results

The data obtained were analyzed for statistical significance using post hoc test. The results are as follows.

Arch Width Changes

Inter Canine Width

The pretreatment inter canine width was 22.4+/-1.52mm. Post expansion inter canine width was 26.8+/-1.79mm. The mean difference from pretreatment to post expansion was 4.4 mm with a 'p' value of 0.042 which is statistically significant.

Inter Canine Width	Number of patients	Pre treatment	Post expansion
	5	22.4+/-1.52mm	26.8+/-1.78mm

Inter Premolar Width

The pretreatment inter premolar width was 24.4+/-1.52mm. Post expansion inter premolar width was 30.2+/-0.84mm. The mean difference from pretreatment to post expansion was 5.8 mm with a 'p' value of 0.032 which is statistically significant.

Inter Premolar Width	Number of patients	Pre treatment	Post expansion
	5	24.4+/-1.52mm	30.2+/-0.84mm

Inter Molar Width

The pretreatment inter molar width was 35.4+/-1.14mm. Post expansion inter molar width was 41.8+/-2.39mm. The mean difference from pretreatment to post expansion was 6.4 mm with a 'p' value of 0.041 which is statistically significant.

Inter Molar Width	Number of patients	Pre treatment	Post expansion
	5	35.4+/-1.14	41.8+/-2.39

Arch Perimeter Changes

The pretreatment arch perimeter was 69.8+/-2.39mm. Post expansion arch perimeter was 74.2+/-1.92mm. The difference from pretreatment to post expansion was 4.4mm with a 'p' value of 0.041 which is statistically significant.

Arch perimeter	Number of patients	Pre treatment	Post expansion
	5	69.8+/-2.39mm	74.2+/-1.92mm

Arch Length Changes

The pretreatment arch length was 21.8+/-2.17mm. Post expansion arch length was 19.8+/-2.28mm. The difference from pretreatment to post expansion was -1.4mm with a 'p' value of 0.041 which is statistically significant.

Arch Length	Number of patients	Pre treatment	Post expansion
	5	21.8+/-2.17mm	19.8+/-2.28mm

Palatal Index Changes

The mean pretreatment palatal index was 47.8+/-3.38%. Mean post expansion palatal index was 45.0+/-4.06%. The difference from pretreatment to post expansion was -2.8% with a 'p' value of 0.038 which is statistically significant. It indicates that after RME there is a significant decrease in palatal depth.

Palatal Depth	Number of patients	Pre treatment	Post expansion
	5	47.8+/-3.38%	45+/-4.06%

Airway Changes

The mean pretreatment upper airway was 9.0+/-2.28mm. Post expansion upper airway was 10.5+/- 2.81mm. The mean difference is 1.5mm with a 'p' value of 0.024 which is statistically significant.

Upper Airway	Number of patients	Pre treatment	Post expansion
	5	9.0+/-2.28mm	10.5+/-2.81mm

The mean pretreatment lower airway was 7.7+/-2.04mm. Post expansion lower airway was 9.0+/- 2.0mm. The mean difference is 1.3mm with a 'p' value of 0.020 which is statistically significant.

Lower Airway	Number of patients	Pre treatment	Post expansion
	5	7.7+/-2.04mm	9.0+/-2.0mm

Discussion

The results obtained from the present study indicate that there are considerable dental arch changes following rapid maxillary expansion. All measurements pertaining to arch width changes showed a significant increase which was observed by most other investigators.¹⁻⁷ Expansion was greater in the posterior segment when compared to the anterior segment. This is in accordance with the study done by Mossez et al. The study conducted by Beiderman et al., Ekstrom et al., and Timms showed a contrary result with

greater expansion in the anterior region compared to the posterior region.

Similar to other studies, the arch perimeter showed a significant increase and the arch length showed a significant decrease. In the present study the palatal depth showed a decrease of 2.8% which was similar to study done by Handel man et al.

The present study showed a significant increase in upper and lower airway. The investigators like El and Palomo and Zao et al found no evidence to support that RME increases the volume of oropharyngeal airway while study by Fitin Aloufi found that there was a significant increase in the upper airway with no change in the lower airway.

The following conclusions were made from the present study. The intercanine width increased by 4.4mm, inter premolar width increased by 5.8mm, intermolar width increased by 6.4mm, arch perimeter increased by 4.4mm, arch length decreased by 1.4mm, palatal depth decreased by 2.8%, upper pharyngeal airway increased by 1.5mm, lower airway increased by 1.3mm. All these changes were statistically significant.

Conclusion

RME is a valuable device for an orthodontist. The present study evidenced significant expansion of maxillary arch with positive changes in the airway also.

Conflict of Interest: None.

References

- Adkins MD, Nanda RS, Currier GF. Arch perimeter changes on rapid palatal expansion. *Am J Orthod Dentofacial Orthop* 1990;97:194-199.
- Akkaya S, Lorenzon S, Uçem TT. Comparison of dental arch and arch perimeter changes between bonded rapid and slow maxillary expansion procedures. *Eur J Orthod* 1998;20:255-261.
- McNamara JA Jr, Baccetti T, Franchi L, Herberger TA. Rapid maxillary expansion followed by fixed appliances: A long-term evaluation of changes in arch dimensions. *Angle Orthod* 2003;73:344-353.
- Aparecida CC, Abrão J, Reis SA, de Fantini SM. Correlation between transverse expansion and increase in the upper arch perimeter after rapid maxillary expansion. *Braz Oral Res* 2006;20:76-81.
- Cozzani M, Guiducci A, Mirengi S, Mutinelli S, Siciliani G. Arch width changes with a rapid maxillary expansion appliance anchored to the primary teeth. *Angle Orthod* 2007;77:296-302.
- Mutinelli S, Cozzani M, Manfredi M, Bee M, Siciliani G. Dental arch changes following rapid maxillary expansion. *Eur J Orthod* 2008;30:469-476.
- Handelman CS, Wang L, BeGole EA, Haas AJ. Non-surgical rapid maxillary alveolar expansion in adults: A clinical evaluation. *Angle Orthod* 1997;67:291-308.
- Baccetti T, Franchi L, Cameron CG, McNamara JA Jr. Treatment timing for rapid maxillary expansion. *Angle Orthod* 2001;71:343-350.
- Bishara SE, Staley RN. Maxillary expansion: Clinical implications. *Am J Orthod Dentofacial Orthop* 1987;91:3-14.

10. Lagravere MO, Major PW, Flores-Mir C. Long-term dental arch changes after rapid maxillary expansion treatment: A systematic review. *Angle Orthod* 2005;75:155-161.
11. Radiographic cephalometry from basics to 3D imaging, 2nd edition- Alexander Jacobson.

How to cite this article: Biswas PP, Hridya KG, Thomson SP, Vaisakh R, Subairuddeen. Dental arch and pharyngeal space changes associated with rapid maxillary expansion. *Int J Oral Health Dent* 2019;5(1):23-26.