

## A non-pathological lesion - Stafnes bone CYST

Avinash Tejasvi<sup>1</sup>, Harsha Bhayya<sup>2\*</sup>

<sup>1</sup>Associate Professor, <sup>2</sup>Assistant Professor, Dept. of Oral Medicine and Radiology, Kamineni Institute of Dental Sciences, Narketpally, Telangana, India

**\*Corresponding Author: Harsha Bhayya**

Email: dr.sbharsha@gmail.com

### Abstract

Stafne bone cysts (SBC) are asymptomatic bony depressions present on the lingual aspect of mandible caused by soft tissue involvement. As SBC's are asymptomatic radiolucent lesion on the mandible, they are incidentally seen during a routine radiographic examination. Diagnosis of such lesions is essential due to its radiographical similarities with that of other odontogenic pathologies. We present a case of SBC which was firstly diagnosed with plain radiograph.

**Keywords:** Static bone cyst, Stafne bone defect, Static bone defect, Latent bone cyst, Idiopathic bone cavity.

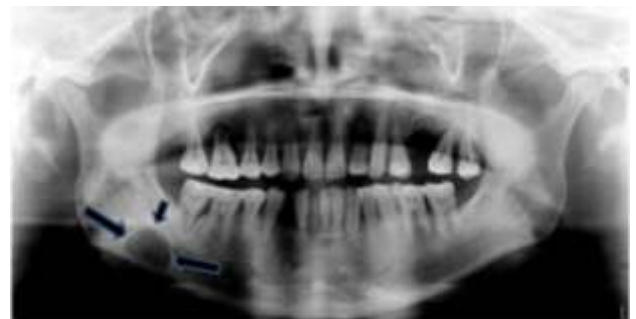### Introduction

Dr. Edward Stafne in 1942 described first about the developmental bony defect occurring in the mandible as Stafne bone defect, which is also known as lingual mandibular cavity. On radiographic examination of 35 asymptomatic patients, he reported well defined unilocular radiolucent cavities occurring on the posterior aspect of mandible. Most of the lesions were seen between mandibular angle and the third molar, below the mandibular canal and above the lower border of mandibular.<sup>1</sup> These developmental mandibular defects are the bony concavity which appears as a deep and well defined depression on the lingual surface of body of the mandible in the posterior aspect.<sup>2</sup> Various terms have been used to describe such developmental defects as static bone cyst, static bone defect, Stafne bone cavity, latent bone cyst, latent bone defect, idiopathic bone cavity, developmental submandibular gland defect of the mandible, aberrant salivary gland defect in the mandible. Non-invasive imaging modalities have been used to analyze Stafne bone defects as they are asymptomatic in nature. Diagnosis of such lesions is essential due to its radiographical similarities with that of other odontogenic pathologies.

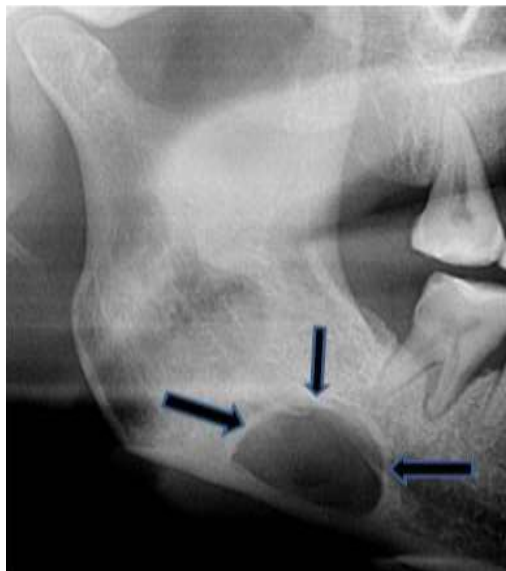
### Case Report

A 55 years old male patient was referred to oral radiology by department of prosthodontics for orthopantomograph (OPG) as a routine evaluation procedure to assess the periodontal status of the patient, for replacement of his missing teeth. OPG showed a well-defined radiolucent area in the mandibular posterior region on right side. This was located between mandibular canal and lower border of mandible, near the region of the antegonial notch below the root of the second molar region molar area. On examining the orthopantomograph (OPG) on the contralateral side there was no such radiolucency. The lesion was unilocular which was measuring around 2 cm in diameter, presenting radiopaque thick corticated margins surrounding the radiolucency. The internal structure was completely radiolucent without any trabeculation and there was no such evident effect on the surrounding structure

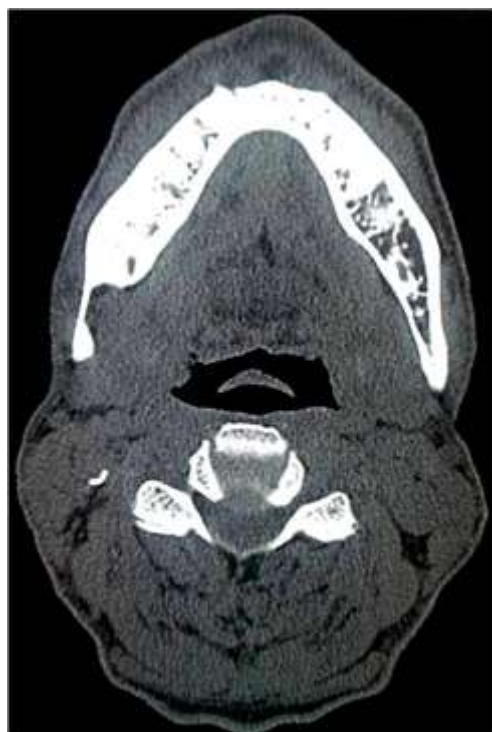[Fig. 2]. Computed tomography (CT) axial view shows a hypodense area in the mandibular molar region on right side suggestive of defect [Fig. 3]. Considering the radiographic features a retrograde clinical examination was done, patient was healthy and did not report any relevant information regarding medical or dental history, and did not mention the use of any medication previously. Patient did not give any history of swelling, pain or sensory disturbance. On further clinical examination, did not reveal any pathology and vitality test was done in relation to the right first and second molar which responded and was interpreted teeth were vital. A final diagnosis of Stafne bone cavity was made based on clinical and radiological findings, and no further therapy was instituted. Patient was recalled every month for a period of 8 months to assess any increase in size of the lesion, where in the lesion appeared same size after 8 months.



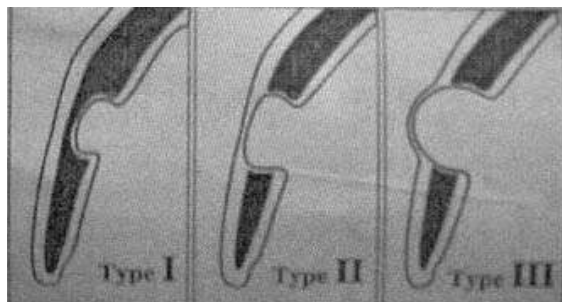
**Fig. 1: A well-defined radiolucency at the level of right second molar region below the inferior alveolar canal suggestive of stafne cavity**



**Fig. 2:** Cropped image of the orthopantomogram



**Fig. 3:** Axial CT view showing defect



**Fig. 4:** Schematic diagram of the classification

## Discussion

Stafne bone defects are developmental defects seen on the mandibular posterior region. Stafne bone cyst is a misnomer and not a true cyst as fluid contents have never been reported. Stafne bone defect has been described by various terms in the literature as Developmental lingual mandibular salivary gland depression posterior variant, latent bone cyst, lingual mandibular bone concavity, Static bone cyst, developmental bone defect of the mandible. Diagnosis of the lesions is mainly based on the characteristic location of a corticated radiolucency. Cross-sectional imaging that shows the submandibular gland (or, rarely, other soft tissues) within the bone cavity confirms the diagnosis.<sup>3</sup> The Stafne bone cavity can be seen in the age group of 11 and 87 years, but generally detected in patients in the 5th and 6th decade of life.<sup>4</sup> The defect is more prevalent among men and is usually found accidentally during the diagnostic phase.<sup>5</sup> In our present case patient was around 55 years old male patient.

Stafne bone cavity is thought to originate to accommodate submandibular gland that lies in close proximity on the lingual aspect of the mandible, by the pressure exercised by glandular tissue on the lingual cortex of the mandible.<sup>6</sup> These depressions are considered developmental rather than congenital. The most common location of SBC is submandibular gland fossa referred as posterior variant located close to the lower border of mandible, Defects in the apical region of the premolars are associated with sublingual glands are referred as lingual anterior variant.

Rarely these defects are seen on the medial surface of ascending ramus of mandible associated with parotid gland referred as medial ramus variant.<sup>7</sup>

Thorough clinical and radiological evaluation has to be done before going for a dental implant procedures even when the radiolucent pathology seen on radiographs is remote from the intended site, as failure to make a satisfactory initial radiological assessment could lead to a charge of negligence if the dental pathology is neither treated nor monitored. Also in implantology, the remote site may be a site for harvesting of autogenous bone graft that may be needed for the implantation to be successful.<sup>8</sup>

As the lesion is asymptomatic radiographic imaging modalities are the choice for analyzing Stafnes bone cyst, which may assist clinicians to better differentiate this defect from more frequent mandibular radiolucencies such as traumatic bone cysts and ameloblastomas. Advanced imaging modalities such as CT, MRI are also helpful not only as diagnostic but also as a follow up imaging. Though Stafne bone cavity is incidental finding, evaluation and diagnosis of Stafne's bone defect is necessary in order to avoid invasive treatments such as bone exploration and trephination.<sup>9</sup>

In panoramic radiographs, the lingual objects are projected upward, so some lesions may appear higher than they really are.<sup>10</sup> To assess the relationship of submandibular salivary gland with that of lingual aspect of mandible, siaolographic evaluation can be done. To

determine the borders and shape of the lesion 3D imaging modalities like CT can be performed. The quantitative nature of CT and advanced analytical software makes it possible to truly determine the inner compartment of intra-osseous defects such as Stafne's cavity. There are some reports regarding the CT density of submandibular glands. According to these reports, the fat content of this tissue is less than the parotid glands and therefore, is closer to muscle density (approximately 40 HU).<sup>11</sup>

In 2006, Ogunsalu et al reported in their study that, average depth and width of concavities are 7.9 and 16.3mm respectively. These concavities are divided based on their outline and relationship to the buccal cortical plate as three different types, which are as follows

Type I: The base of the concavity did not reach the buccalcortical plate.

Type II: The base of the concavity reached the buccalcortical plate but no expansion or distortion of the plate is seen.

Type III: The base of the concavity is characterized by a buccal expansion of the cortical plate.

Depression of salivary gland may produce various shapes of SBC which can be appreciated in panoramic radiographs as 1. Round; 2. Ovoid; 3. Triangular; 4. Heart-shaped. Based on the content of these concavities as determined by axial CT analysis, they are divided in to three types. Type F, if it is filled only with fat density with the CT values varied from – 50 to 200 HU. Type S with density of soft tissue structure suggesting a lymph node, vessel, connective tissue or others. Type G, if the submandibular gland was entrapped in or was located close to the concavity.<sup>8</sup>

The clinical significance of SBC is mainly based on the asymptomatic radiolucent cavity which differentiates it from other possible pathologies regardless of content and site of the lesion. Although posterior variants of well-defined unilocular SBCs are usually diagnosed first on conventional panoramic radiographs, various presentations are prone to be misdiagnosed with benign odontogenic inflammatory or cystic lesions an unnecessary treatment might be done. Hence unilocular radiolucent that can be considered as a differential diagnosis of SBC include Traumatic bone cyst, Periapical cyst, Dentigerous cyst, Odontogenickeratocyst, Focal osteoporotic bone marrow defect, Brown tumor in hyperparathyroidism. Although the asymptomatic character of the lesion and the lack of expansion of cortical plates and history of inflammation seems to be enough to exclude possible to asses benign or primary malignant odontogenic pathologies. Submandibular Salivary gland depressions are not usually treated; they tend to remain more stable. The two main therapeutic options are based on either surgical intervention or a 'wait and see' approach, the latter being preferred, always with periodic clinical and radiological controls.<sup>12</sup>

## SBC

**Courtesy:** C Ogunsalu, K Pillai, S Barclay. Radiological Assessment of Type II Stafne Idiopathic Bone Cyst in a Patient Undergoing Implant Therapy-A Case Report. *West Indian Med J* 2006;55(6):447-450.

**Conflict of Interest:** None.

## References

1. Stafne EC. Bone cavities situated near the angle of the mandible. *J Am Dent Assoc* 1942;29:1969-1972.
2. Ariji E, Fujiwara N, Tabata O, Nakayama E, Kanda S, Shiratsuchi Y, y cols. Stafne's bone cavity: Classification based on outline and content determined by computer tomography. *Oral Surg Oral Med Oral Pathol* 1993;76:375-380.
3. Prapanpoch S, Langlais RP. Lingual cortical defect of the mandible: an unusual presentation and tomographic diagnosis. *Dentomaxillofac Radiol* 1994;23:234-237.
4. Shimizu M, Osa N, Okamura K, Yoshiura K. CT analysis of the Stafne's bone defects of the mandible. *Dentomaxillofac Radiol* 2006;35(2):95-102.
5. Grellner T, Frost D, Brannon R. Lingual mandibular bone defect: Report of three cases. *J Oral Maxillofac Surg* 1990;48:288-296.
6. Philipsen H, Takata T, Reichart P, Sato S, Suei Y. Lingual and buccal mandibular bone depressions: A review based on 583 cases from a world-wide literature survey, including 69 new cases from Japan. *Dentomaxillofac Radiol* 2002;31:281-290.
7. Philipsen H, Takata T, Reichart P, Sato S, Suei Y. Lingual and buccal mandibular bone depressiones: A review based on 583 cases from a world-wide literature survey, including 69 new cases from Japan. *Dentomaxillofac Radiol* 2002;31:281-290.
8. C Ogunsalu, K Pillai, S Barclay. Radiological Assessment of Type II Stafne Idiopathic Bone Cyst in a Patient Undergoing Implant Therapy-A Case Report. *West Indian Med J* 2006;55(6):447-450.
9. Philipsen H, Takata T, Reichart P, Sato S, Suei Y. Lingual and buccal mandibular bone depressiones: A review based on 583 cases from a world-wide literature survey, including 69 new cases from Japan. *Dentomaxillofac Radiol* 2002;31:281-290.
10. Langlais RP, Langland OE, Nortjé CJ. Diagnostic Imaging of the Jaws, 2nd ed. USA: Williams and Wilkins; 2nd ed. Philadelphia, PA: Lea and Febiger; 1995. p 1-17.
11. Bailey BJ, Johnson JT, Newlands SD. Head and Neck Surgery-Otolaryngology. 4th Ed. Philadelphia: Lippincott Williams & Winkins; 2001. p. 529.
12. Reuter I. An unusual case of Stafne bone cavity with extra-osseous course of the mandibular neurovascular bundle. *Dentomaxillofac Radiol* 1998;27:189-191.

**How to cite this article:** Tejasvi A, Bhayya H. A non-pathological lesion - Stafnes bone CYST. *Int J Oral Health Dent* 2019;5(1):44-46.