

Diagnosis and step by step systematic management of cleft anomalies underlining the importance of an early referral and non-surgical interceptive treatment modalities: A review

Rajarshi Basu^{1,*}, Arun Ramaiah², Mathew P.C³, Naved Khan⁴, Junaid Shaikh⁵

^{1,2}Fellow, ³Project Director, ⁴Assistant Professor, ⁵Senior Lecturer, Dept. of Cleft & Craniofacial Surgery, ¹⁻³St. Thomas Hospital, Chengannur, Kerala, ⁴Government Dental College, Raipur, Chhattisgarh, ⁵Saraswati Dhanwantari Dental College, Parbhani, Maharashtra, India

*Corresponding Author: Rajarshi Basu

Email: rajarshi.omfs@gmail.com

Abstract

Cleft lip and cleft palate are two of the most frequently recorded birth defects in the world. It may occur as an isolated condition or it may be associated with other developmental birth defects. Either way, cleft related deformities are completely treatable and the children born with such conditions can lead a normal healthy life following its correction. The aim of this article is to communicate a systematic time bound treatment algorithm underlining the importance of the various adjuvant interceptive non-surgical modalities.

Keywords: Cleft anomaly, Non-surgical interceptive Treatment Modality, Time bound treatment algorithm, Prenatal diagnosis and parent counselling.

Introduction

Orofacial cleft, is a group of conditions that includes cleft lip (CL), cleft palate (CP), and both together (CLP).^{1,2} Cleft lip and Cleft Palate may be unilateral, bilateral, incomplete or complete.¹ Cleft lip and palate are the result of tissues of the face not joining properly during development.¹ Risk factors include smoking during pregnancy, diabetes, obesity, an older mother, and certain medications (such as some used to treat seizures).^{1,2}

These disorders can result in feeding problems, speech problems, hearing problems, and frequent ear infections.¹ Apart from the various Physical Anomalies, the incomprehensive speech associated with such patients can lead to social isolation and development of inferiority complex.

The various Surgical Procedures for the Correction of the cleft deformities are well known and have been discussed in

detail in previous literatures. This article focusses primarily on the importance of prenatal diagnosis, Parenteral Counselling, the various Adjuvant Interceptive Non-Surgical Treatment Modalities and the Importance of a proper Time Bound Treatment Algorithm (Chart 1).

Prenatal Diagnosis and Parent Counselling

Ultrasound screening for foetal structural abnormalities is generally recommended at 19-21 weeks of gestational age. The accuracy in detecting malformations by ultrasound, however, shows great variability among centres and operators.³ Cleft lip and Palate deformities can be diagnosed by prenatal ultrasound screening (Fig. 1). At this juncture, parental counselling is very necessary and the parents have to be explained that this structural anomaly is completely treatable. Failure to do so can very easily lead to the confused parents opting for medical termination of pregnancy.

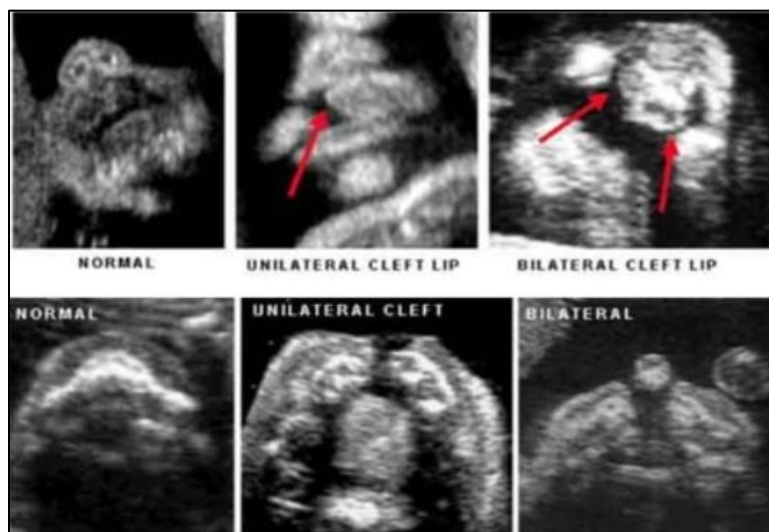
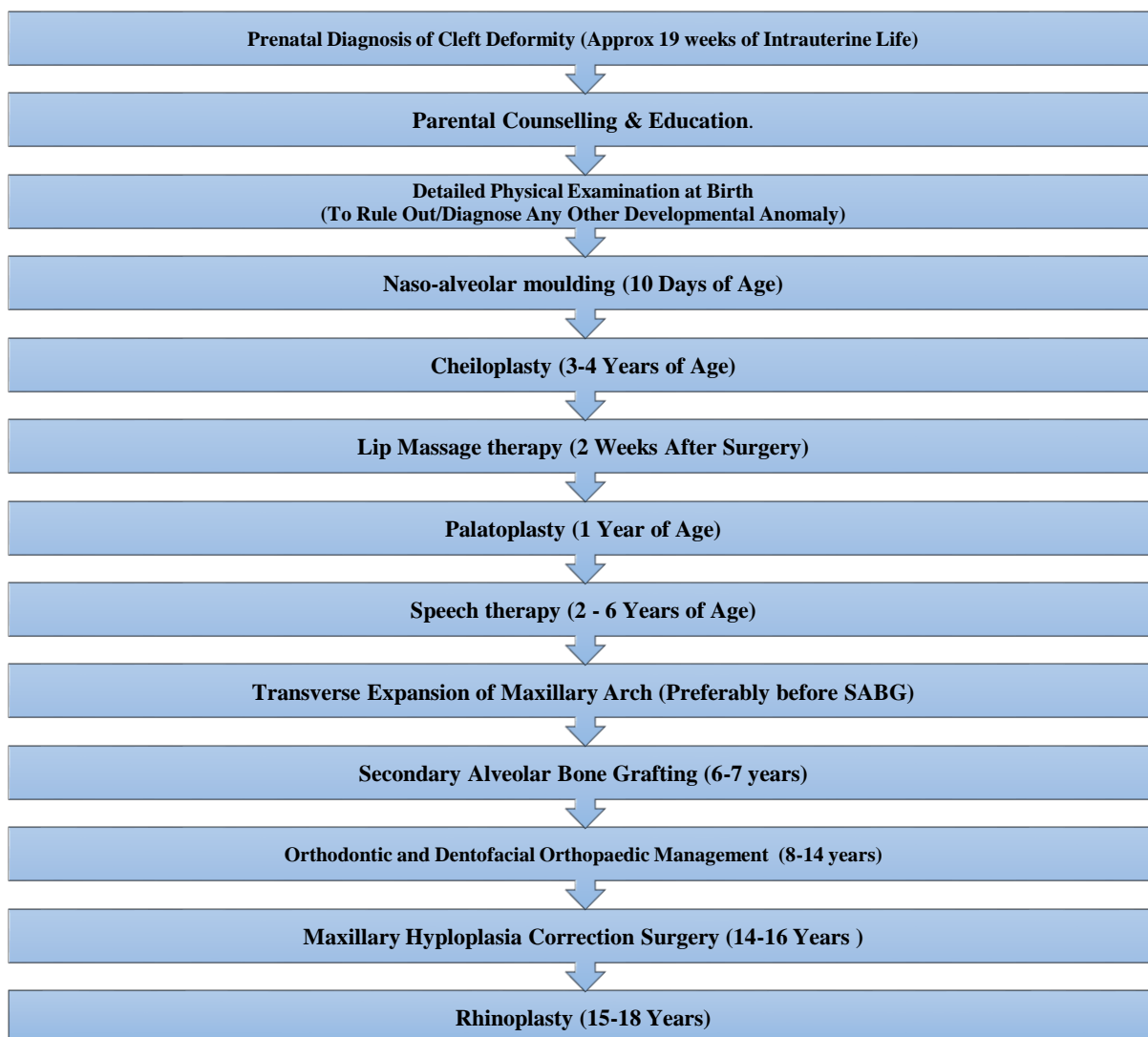


Fig. 1: Prenatal USG images of cleft anomalies

Chart 1



Presurgical Naso-Alveolar Moulding (10-20 Days of Age)

Nasoalveolar molding (NAM) represents a paradigm shift from the traditional methods of presurgical infant orthopaedics. NAM technique moulds the nasal cartilages, premaxilla, and alveolar ridges into normal form and position during the neonatal period (Fig. 2). Literature advises it be started at 10 days after birth. This technique takes advantage of the malleability of immature nasal cartilage and its ability to maintain a permanent correction of its form. In effect, this presurgical management of the cleft infant not only reduces the severity of the oronasal deformity prior to surgery, but also makes it easier for the surgeon to deliver better cosmetic results.

Cheiloplasty (Cleft Lip Correction Surgery) (3-6 months)

Cheiloplasty or cleft lip correction surgery is performed to join together (fuse) properly the tissues on the either sides

of the cleft defect. Surgical repair corrects the defect, preventing future problems with breathing, speaking, and eating, and improves the person's physical appearance. Cleft of lip can either occur unilaterally or bilaterally (Fig. 3). The cleft may involve the entire lip extending up to the nasal floor or it might involve just a portion of it. Different surgical techniques have been suggested in the literature for the correction of unilateral and bilateral cleft lip conditions.

The cheiloplasty procedure is usually undertaken when the patient is 3 to 4 months of age with an approximate weight of 5 kg. The earlier the surgery is undertaken, the better the cosmetic outcome of the procedure. The cosmetic outcome is observed to be better where the cheiloplasty procedure is done secondary to the NAM. The Surgical Lip Correction is followed by a Rigorous Lip Massage Therapy for a minimum duration of 6 Months to obtain better cosmetic results.

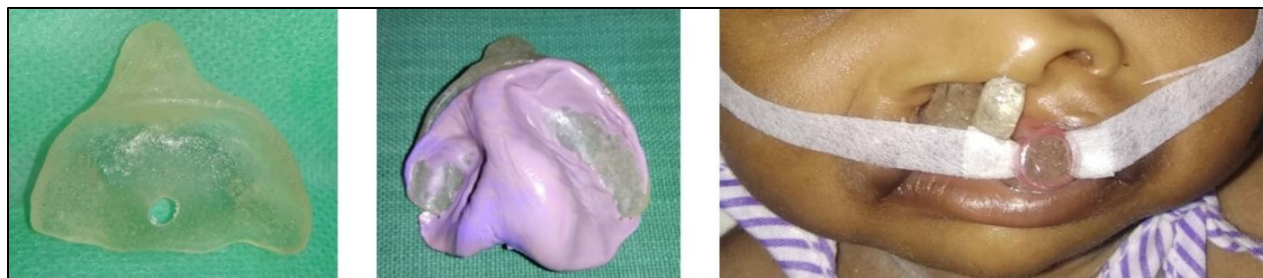
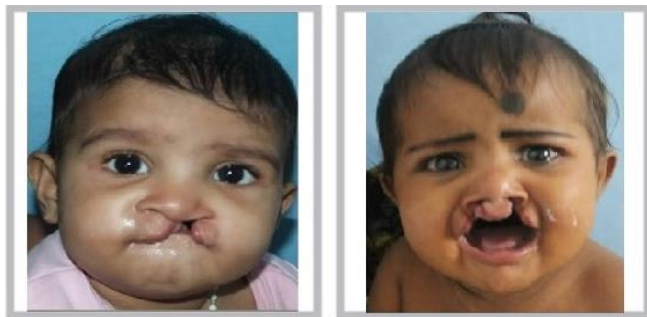
Fig. 2: Naso-alveolar moulding (NAM)



unilateral cleft

Bilateral cleft

Fig. 3: Unilateral & bilateral complete cleft lip

Lip Massage Therapy (usually started 2 weeks after surgery)

The success of the Cheiloplasty procedure depends a lot on the postoperative lip massage therapy. It is usually started 2 weeks after the surgery. The purpose of this therapy is to reduce the postoperative scar formed as a result of the surgery. It is started approximately 2 weeks after the surgery and is continued for a minimum period of 6 months. Usually a steroid or allantoin based ointment is incorporated during the massage to obtain the best cosmetic results. The lip massage when done in a correct manner and for adequate

duration can deliver excellent cosmetic results (Fig. 4). It is therefore highly important to demonstrate the proper massaging technique to the parents and educate them about its significance.

Palatoplasty (Cleft Palate correction surgery) (1-2 years)

A cleft palate can involve the hard palate (the bony front portion of the roof of the mouth), and/or the soft palate (the soft back portion of the roof of the mouth). Cleft lip and cleft palate can occur on one or both sides of the mouth. Because the lip and the palate develop separately, it is possible to have a cleft lip without a cleft palate, a cleft palate without a cleft lip, or both together.

Palatoplasty is recommended at 1-2 years of age. The presence of cleft palate has both aesthetic and functional implications for patients in their social interactions, particularly on their ability to communicate effectively. The principle behind palatoplasty is a good muscle dissection and reorienting it in correct anatomic position there by achieving goals such as normal speech, minimizing growth disturbances, and establishing a competent velopharyngeal sphincter.⁵ An early palatoplasty procedure followed by rigorous speech therapy is observed to produce better results in terms of phonation of the patient. The closure of wide palatal clefts becomes easier when the patient has been subjected to NAM therapy in his neonatal age (Fig. 5).

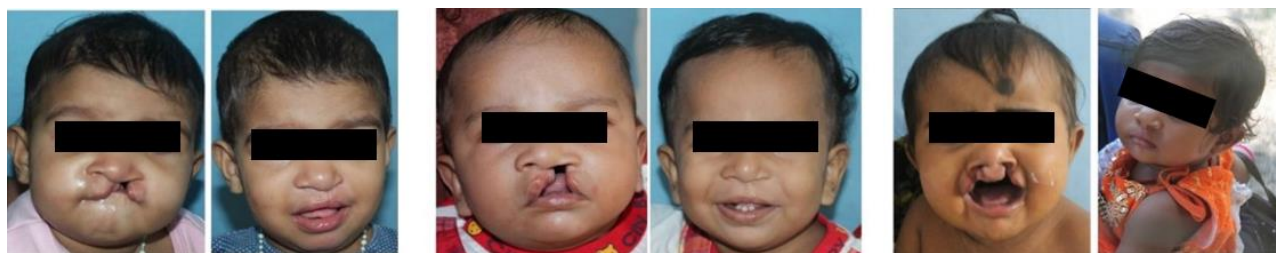

Fig. 4: Pre-op & post-op pictures of cleft lip patients after lip massage therapy

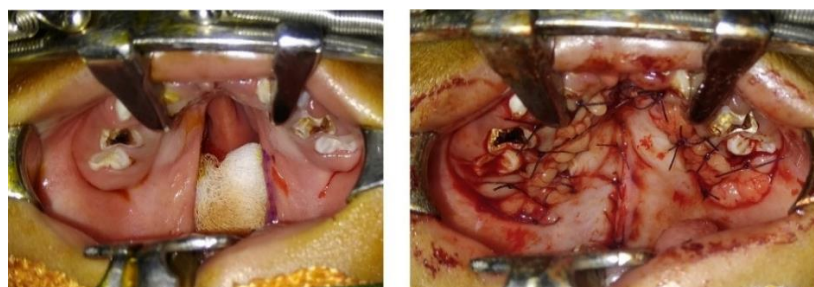


Fig. 5: Pre-op & post-op pictures of unilateral complete cleft palate

Speech Therapy (2-6 years)

Speech development is paramount in the appropriate management of cleft palate. In addition to speech therapy for cleft palate speech deviations, treatment may also address developmental articulation, phonology disorders and language delays or disorders. A comprehensive cleft management centre is incomplete without a dedicated team of speech pathologists working to improve the speech and phonetics of the cleft palate patients. Subjecting a child to an Early Speech Therapy leads to better phonetics and enhances communication skills.

Transverse Expansion of Maxillary Arch (Preferably before SABG)

Approximately 21% of cleft children have some form of transverse skeletal discrepancy involving the dental arches.⁶ The cause of maxillary constriction has been shown to be environmental, genetic, or multifactorial.⁷ In order to address the problem of transverse discrepancy, most of cleft cases require expansion of the maxillary arch. The expansion procedures are performed during mixed dentition, or early adolescence, since mid-palatal and other circum-maxillary sutures are still patent. The basic need for expansion comprises of: alignment for collapsed arches, correction of cross-bites to the correctable extent, to expand the arch and align in order to prepare them for ABG (alveolar bone growth), to improve the airway dimensions following expansion, to facilitate nasal expansion, to improve tongue placement and facilitating speech development. Expansion procedures can be classified either as rapid maxillary Expansion (appliances are generally activated 0.2 to 0.5 mm per day) or slow maxillary expansion (rates of expansion generally occur at approximately 0.5 to 1.0 mm per week). Various protocols and devices are given for both the two modalities.

Secondary Alveolar Bone Grafting (6-7 years)

Secondary bone grafting of the maxilla and the residual alveolar cleft has become an adjunctive procedure aiming to further improve the functional and aesthetic rehabilitation of patient with unilateral or bilateral cleft lip and palate.⁸ The present thinking is that alveolar grafting should be ideally timed somewhere between 6-7 years of age at the stage of transitional dentition preceding eruption of the canine.⁹ This procedure not only helps guide the canine to erupt in a normal anatomical position but also provides a normal arch form. Patients who completed maxillary expansion prior to secondary alveolar bone grafting surgery reported less incidences of relapse.⁹

Orthodontic and Dentofacial Orthopaedic Management (8-14 years)

Over the years the role of the orthodontist has been multiple because it is synergistic with other treatment needs of the cleft patient. Treatment rendered by the orthodontist is based on the developmental and functional needs of the patient. It influences the position of teeth (orthodontic effect), their supporting bones (orthopaedic effect), or both.

Orthodontics for cleft patients is divided into various phases depending on the age of the patient. Orthodontics helps to expand the already constricted maxilla due to the cleft palate surgery, align the teeth, and also prepares the patient for Cleft Orthognathic Surgery. It is therefore the job of the orthodontist to plan and align the dentition in such a manner that the normal overjet and overbite values are restored after the cleft orthognathic surgery.

Maxillary Hypoplasia Correction Surgery (14-16 Years)

Cleft lip and palate patients normally undergo surgical soft tissue repair of the cleft lip and palate during infancy. The advantages of this surgical procedure shine brightly with the aesthetic and functional improvement in the early days of the infant's life. Unfortunately, this pleasing effect is lost when impaired maxillary growth begins to make an appearance as the child grows. The resulting secondary deformities of the jaw and malocclusion are only a consequence of early soft tissue repair of the cleft palate.¹⁰ Maxillary advancement using traditional one stage le Fort osteotomy is an accepted treatment modality in treating maxillary deficiencies in cleft patients. However in patients with severe midface deficiency, the maxillary advancement is also conjugated with mandibular setback using a bilateral sagittal split osteotomy. Such surgeries involving both maxilla and mandible are often referred to as a Bi-Jaw Surgery. In certain cases surgical advancement of the genium is also done to provide a pleasing cosmetic profile to the patient (Fig. 6).

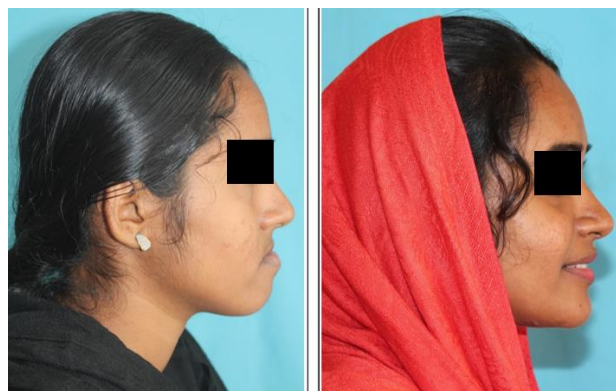

Fig. 6: Pre-op & Post-op of cleft orthognathic surgery

Rhinoplasty (15-18 Years)

Nasal deformity correction in cleft lip patients remains a challenging problem. Cleft lip nasal deformity is a complex three-dimensional deformity involving skin, cartilage, vestibular lining and skeletal platform. The primary deformity is an imbalance between abnormal muscle insertion and maxillary skeletal hypoplasia.¹¹ The objectives of cleft-rhinoplasty are positioning of lower lateral cartilage to a more normal anatomic position, achieving a symmetric projection of both alar domes, elongation of columella when deemed necessary and to provide a structural support by means of bone or cartilage grafts.^{12,13}

Conclusion

A cleft lip or palate condition may impact an individual's self-esteem, social skills and behaviour. Adolescents with cleft lip or palate are at an elevated risk for developing psychosocial problems especially those relating to self-concept, peer relationships and appearance. Most children who have their clefts repaired early enough are able to have a happy youth and social life. Having a cleft lip or palate does not inevitably lead to a psychosocial problem. Early diagnosis, a proper systematic treatment approach along with effective parent and child counselling can in most cases enable children born with such deformities to lead a normal and fruitful life. Therefore to conclude, we can safely state that apart from the various surgical procedures, the adjuvant non-surgical Interceptive Modalities are equally important to attain desirable functional and cosmetic rehabilitation for the cleft patients.

Conflict of Interest: None.

References

1. Facts about Cleft Lip and Cleft Palate. October 20, 2014. Archived from the original on 8 May 2015. Retrieved 8 May 2015.
2. Watkins SE, Meyer RE, Strauss RP, Aylsworth AS. Classification, epidemiology, and genetics of orofacial clefts. *Clin Plast Surg* 2014;41(2):149–63. doi:10.1016/j.cps.2013.12.003. PMID 24607185.
3. Todros T, Capuzzo E, Gaglioti P. Prenatal diagnosis of congenital anomalies. *Images Paediatr Cardiol* 2001;3(2):3-18.
4. Grayson BH, Maull D. Nasoalveolar Molding for Infants Born with Clefts of the Lip, Alveolus, and Palate. *Semin Plast Surg* 2005;19(4):294-301. doi:10.1055/s-2005-925902.
5. Ysunza PA, Repetto GM, Pamplona MC, et al. Current Controversies in Diagnosis and management of Cleft Palate and Velopharyngeal Insufficiency. *Biomed Res Int*. 2015.2015:196240.
6. da Silva Filho OG, Santamaria M, Jr., Capelozza Filho L. Epidemiology of posterior crossbite in the primary dentition. *J Clin Pediatr Dent* 2007;32:73-8.
7. Proffit WR. Contemporary Orthodontics, Third Edition. Saint Louis: Mosby, Inc.; 2000.
8. Ozawa T, Omura S, Fukuyama E, Matsui Y, Torikai K, Fujita. Factors influencing secondary alveolar bone grafting in cleft lip and palate patients: prospective analysis using CT image analyzer. *K Cleft Palate Craniofac J* 2007;44(3):286-91.
9. Newlands LC. Secondary alveolar bone grafting in cleft lip and palate patients. *Br J Oral Maxillofac Surg* 2000 Oct; 38(5):488-91.
10. McIntyre GT, Devlin MF. Secondary alveolar bone grafting (CLEFTSiS) 2000-2004. *Cleft Palate Craniofac J* 2010;47(1):66-72.
11. Ross, R. (1987) Treatment variables affecting facial growth in complete unilateral cleft lip and palate: An overview of treatment and facial growth. *Cleft Palate Craniofac J* 1987;24:71-7.
12. Sykes JM, Senders CW. Pathologic anatomy of cleft lip, palate and nasal deformities. In: Meyers AD, editor. *Biological Basis of Facial Plastic Surgery*. New York: Thieme Medical Publishers; 1993. pp. 57–71.
13. Ortiz Monasterio F, Ruas EJ. Cleft lip rhinoplasty: the role of bone and cartilage grafts. *Clin Plast Surg* 1989;16(1):177-86.

How to cite this article: Basu R, Ramaiah A, Mathew PC, Khan N, Shaikh J. Diagnosis and step by step systematic management of cleft anomalies underlining the importance of an early referral and non-surgical interceptive treatment modalities: A review. *J Oral Med, Oral Surg, Oral Pathol, Oral Radiol* 2019;5(1):9-13.