

Central giant cell granuloma: Diagnostic difficulty and multi-stage treatment

Rajesh B Dhirawani¹, Anshika Grover², Sanyog Pathak³, Sanchit Jain^{4,*}

¹HOD, ²Resident, ³Reader, ⁴Senior Lecturer, Dept. of Oral and Maxillofacial Surgery, Hitkarini Dental College and Hospital, Jabalpur, Madhya Pradesh, India

***Corresponding Author: Sanchit Jain**

Email: sanchit.ja90@gmail.com

Abstract

The Central Giant Cell Granuloma or CGCG is a fibro-osseous lesion which is considered to be reactive in nature by many authors. Here we are attempting to report a case of CGCG which has been given combination therapy. The combination therapy included local infiltration of corticosteroids along with surgical enucleation of the lesion. The surgical therapy was done after 4 successful administrations of steroids intra-lesionally in clinically aggressive lesion of CGCG. The patient who had been treated by combination therapy has been symptom free from past 3 yrs. This combination therapy is hence found to be of adequate success in treating these aggressive lesions which can be addressed without resection of the bone. The morbidity of treatment carried out hence could be reduced a ton. Thereby we are attempting to report and review the treatment protocol for management of such large giant cell lesions which are not so commonly seen in oral and maxillofacial region. The case reported here has been secondarily reconstructed with iliac crest grafting with adequate success.

Keywords: CGCG, Giant Cell lesion, Giant cell Granuloma, Multistage treatment.

Introduction

The granuloma as a disease entity is generally a reactive lesion which is owing to the fact that the source of the lesion is not removed by the normal immunity system of the body. These lesions hence are triggered by various factors. The central giant cell granuloma as the name suggest was also considered to be one such lesion which is not so. This lesion is mainly bone lesion which does not regress easily but keeps on increasing in size if not treated adequately.

The central giant cell granuloma is categorized under fibro-osseous lesion. This lesion is highly variable in its presentation. Owing to the wide ranges of clinical presentation of the central giant cell granuloma, the central giant cell granuloma is currently considered to a true neoplasm of bone. The lesion is basically an osteolytic one which erodes the bone in a variable degree. The first report of this lesion was done by Jaffe in the year 1953 where this lesion was considered to be a reparative lesion by the author. The treatment of this lesion hence followed a more conservative treatment protocol by various authors during that time. With the increased study on the lesion and attempt to evaluate the success of the treatment it was noted that the lesion shows a lot of recurrences.¹⁻³

The central giant cell granuloma is currently defined by World Health Organization as an intraosseous lesion composed of both cellular and dense connective tissues that contain multiple hemorrhagic foci, an aggregation of multinucleated giant cells and occasional bone tissue trabeculae.^{4,5} There has been various attempts to understand the origin of this lesion which has not been clearly understood. The most commonly accepted reason being local trauma, inflammation, intraosseous hemorrhage and genetic abnormalities. The trauma is most commonly accepted cause many cases are found to be associated with trauma which is also most common association with AOT.^{6,7}

Case Presentation

A patient aged 21 years female reported to our hospital with a chief complaint of diffuse swelling which is present on the left side of the face since 1 year. On detailed history taking it was noted that the patient had similar swelling on the left side of face 3 years ago. The excision of the lesion was done 3 years ago and the histopathologic examination of the lesion was done. The examination revealed the lesion to be of chronic inflammatory origin. The lesion was suppressed for 2 years after which it slowly increased in size to achieve current size. The lesion on inspection was found to single, diffuse lesion which was evident on the left side of the face which lead to raise in the left ala of the nose along with mild distortion of the lip. The swelling is 2.5 cm x 2 cm, ovoid, extending from ala of the nose till preauricular region antero-posteriorly. All the inspectory findings were confirmed on palpation. The swelling was firm in consistency, single, non fluctuant. The swelling was tender on palpation and the temperature over the swelling was normal. There is presence of scar on the swelling which was due to attempt of FNAC which carried out by general surgeon. On detailed history taking it was revealed by the patient that the swelling lead to obstruction of one side of the nose making it difficult for the patient to respire from left side. The intraoral examination of the swelling revealed the obliteration of the buccal vestibule from canine region till the second molar region. There swelling extended palatally which did not cross the midline. (Fig. 1 Preoperative Photographs). Radiographic evaluation was done to understand the lesion. The OPG of the patient revealed presence of mixed radiolucency which also obliterated the maxillary sinus. (Fig. 2 Radiographic Evaluation) The incisional biopsy was then carried out to confirm the diagnosis of the lesion. The lesion was diagnosed to be CGCG. The patient hence was advised CT scan to understand the extent of the lesion and plan treatment for the same. (Fig. 2 CT scan Images)

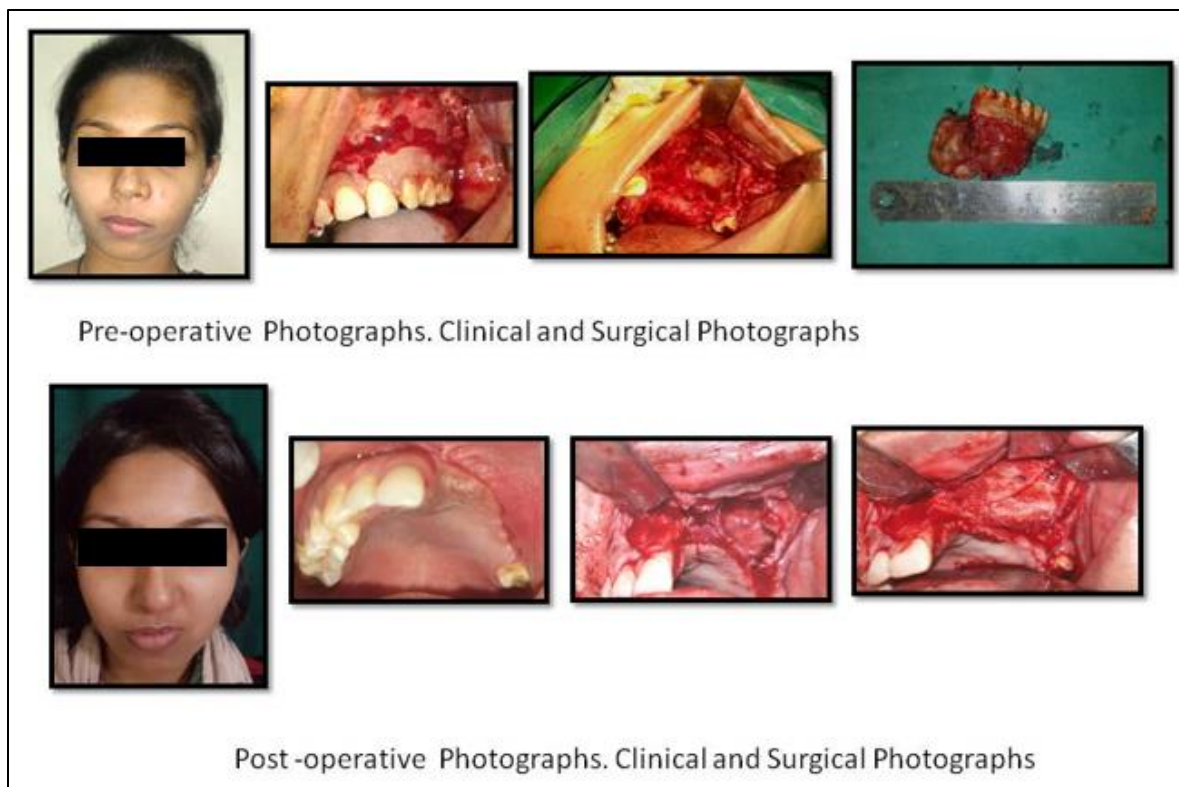


Fig. 1

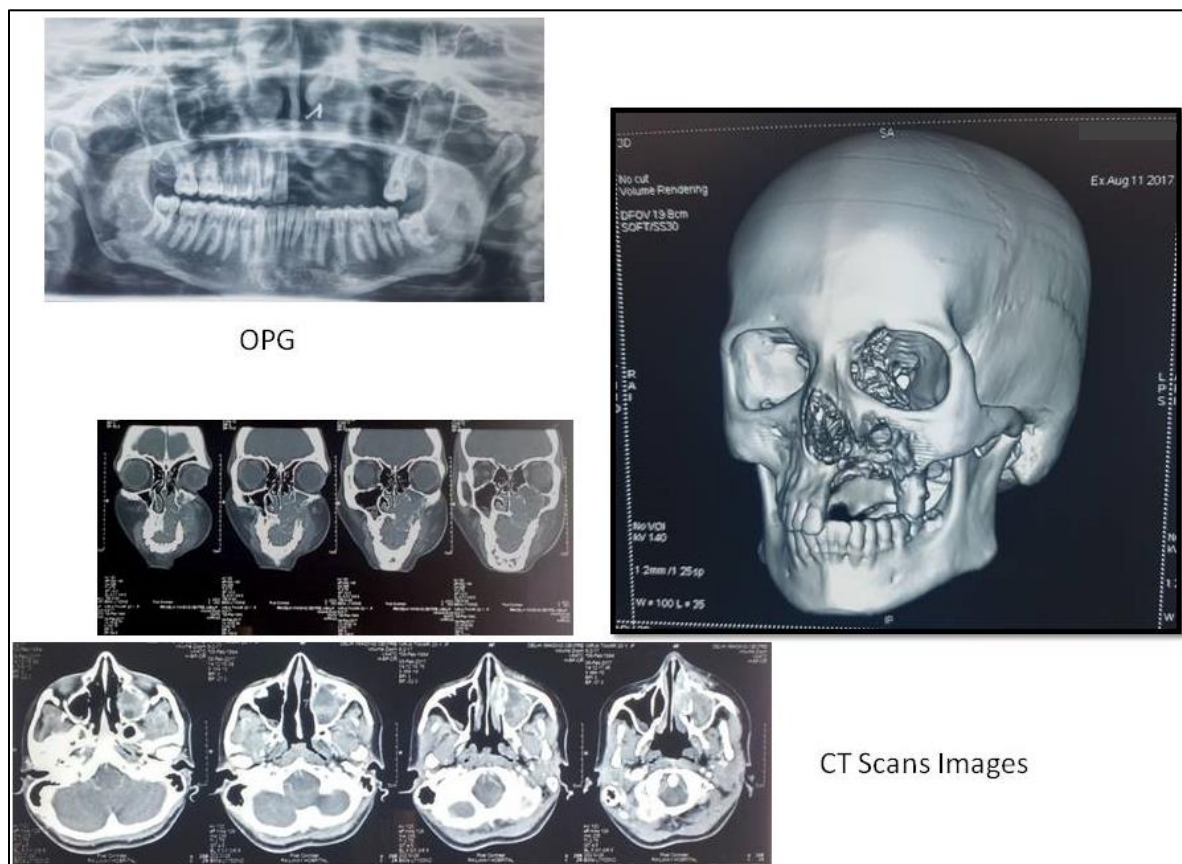


Fig. 2

The patient was hence planned for partial maxillectomy. The vestibular incision was given at the left maxillary region to expose the lesion and whole lesion was then exposed buccally at the left side. Followed by this the palatal flap which was raised to expose the palatal aspect the lesion. The whole lesion was then curetted and completely separated from its margins followed by infrastructural partial maxillectomy cuts was done. The lesion was surgically excised. Later on, bony margins were refreshed. Closure was done in the layer wise. (Fig. 1 Intraoperative pictures Stage I)

The patient was planned for secondary reconstruction using Iliac Crest Graft owing to the fact that the lesion was recurrent in nature. The reconstruction was done after harvesting bone graft. Crestal incision was given and full thickness mucoperiosteal flap was raised and dissection was done to expose the bone defect. This was followed by harvesting the cortico-cancellous graft from the anterior superior iliac spine. The harvested bone graft was fixed over the defect area with 1x2mm x 10mm screw and 2x1.5mm x 10mm screws. The residual defect which was observed after the block grafting was covered with cancellous bone chips. Closure was done in the layer wise. The postoperative period was uneventful. (Fig. 1: Stage II Photographs)

The postoperative photograph of the patient after 6 months was taken which reveals adequate healing and uptake of the graft which was placed in second surgery.

Discussion

Central giant cell granuloma is very difficult to be diagnosed clinically. The diagnosis of this lesion is mainly done with the help of histology diagnosis by incision biopsy. The lesion most commonly occurs in anterior mandible region and is noted to be around 7% of all benign tumors of jaws. CGCG is generally affects in younger age group below 30 years with high prevalence in female with ratio of 3:1.⁸

The histopathologic examination reveals presence of multinucleated giant cells which are spread throughout the lesion. The cells are focally distributed around hemorrhagic areas and in reverse evenly distributed in granulomas of long bones. Matrix contains spindle cells, hemorrhagic areas and giant cells with up to evenly distributed 30 nuclei, in contrast to giant cells of tuberculosis with horseshoe shape arrangement.² Many studies conclude spindle cells to be the active component of the lesion and the giant cells being osteoclasts. Similar histological appearances are seen in the following lesions, which must often be differentiated:

1. The brown tumor of hyperparathyroidism. If there is any doubt (with an aggressive lesion, a recurrent lesion, an atypical lesion or multiple lesions), hyperparathyroidism should be excluded with serum calcium and phosphate determination and in many cases also a parathormone assay.²
2. The aneurysmal bone cyst. This lesion has more hemorrhage in it and also cystic areas, but many authorities agree that it actually represents a cystic variant of the central giant cell granuloma.^{2,7}
3. Cherubism is also included to be one of the differential diagnosis owing to multicystic appearance of the lesion

and the incidence in the similar age group. The lesion is present bilaterally and hence makes the clinical differentiation easy from the CGCG. There is also presence of multiple impacted tooth which also in one of the pathognomic finding in cherubism.^{2,7,9}

4. Odontogenic myxoma is another most common differential. This may appear as a poorly defined or well-circumscribed radiolucent defect, which may be unilocular or multilocular. The multilocular variant shows a tennis racquet appearance.

The fibrous lesion are most variable lesions which is owing to the fact that the clinical presentation and radiographic presentation of all the lesions are almost similar to each other. These lesions are mainly diagnosed only on the histological basis. The fibrous lesions when seen radiographically mainly shows mixed radiolucency. The mixed nature is due to difference in the density of the lesion which varies and present as different mixed lesions.

The lesions which are histologically identified as CGCG can further be classified as aggressive or non aggressive types. The clinic presentation plays a main role in such lesions. This classification was given by Choung in 1986^{10,11} which had various aspects which kept on added with that time. The aggressive non clinically is determined by root resorption of the tooth in vicinity of the lesion, rapid growth, cortical perforation, cortical thinning, Size greater than 5cm in diameter.⁶ The three of the above features if present is seen is concerned to be aggressive.

Owing to these findings the treatment of the CGCG is variable which extending from a more conservative treatment plan of intralesional injections to a more aggressive treatment of an resection of the lesion with wide margin followed by secondary reconstructions.¹² The presented case was treated aggressively owing the aggressiveness and secondary reconstructed after adequate follow-up. The time period which was given was to allow the complete growth of the maxilla and hence facilitate adequate reconstruction.

The intralesional injections are aimed at reducing the inflammatory reaction which is evident in such lesions. The intralesional injections of corticosteroids, interferon – α , bisphosphonates and calcitonin are most commonly used to treat such lesions.^{5,13} The growth of these lesions are mainly seen to occur in the puberty hence conservative therapy is given importance in younger age group. The aggressive lesions in younger age groups is treated conservatively which includes combination therapy. The combination is mainly association of curettage along with intralesional injection after curettage to avoid recurrences. Steroids and calcitonin have been postulated to act by inhibition of osteoclastic activity and hence is still in use. Out of all the conservative drug therapy, the most common administration of equal parts of triamcinolone acetone (10 mg/mL) and 0.5% bupivacaine injected into the lesion for a period of 11 weeks have been shown to be effective in younger age group.¹³ There are various contraindications to this therapy which includes medical conditions, such as diabetes mellitus, peptic ulcer and generalized immune-compromised states. Owing to such

changes in the patient after intralesional lesions there is constant need to check the blood and systemic profiles.¹³

A combination of interferon α and imatinib has been used with adequate success for treatment also. Our case owing to its aggressive nature was treated by surgical excision. This was followed by bone grafting where iliac crest was used as source of the bone.

Conflict of Interest: None.

References

- de Lange J, van den Akker HP, van den Berg H. Central giant cell granuloma of the jaw: a review of the literature with emphasis on therapy options. *Oral Surg, Oral Med, Oral Pathol, Oral Radiol Endodontol* 2007;104(5):603-15.
- Pogrel AM. The diagnosis and management of giant cell lesions of the jaws. *Ann Maxillofac Surg* 2012;2(2):102.
- Jerkins D, Malotky M, Miremadi R, Dole M. Central giant cell granuloma of the mandible requiring multiple treatment modalities: A case report. *J Oral Maxillofac Surg* 2016;74(8):1596-607.
- Daroit NB, de Marco RG, Sant' Anna Filho M, Fritscher GG. The challenge in the treatment of central giant cell granuloma—What is the best approach?. *J Oral Maxillofac Surg, Med Pathol* 2017;29(2):122-8.
- Bayar OF, Ak G. Treatment of giant cell granuloma with intralesional corticosteroid injections: a case report. *J Istanbul Univ Fac Dent* 2015;49(3):45.
- Chrcanovic BR, Gomes CC, Gomez RS. Central giant cell lesion of the jaws: An updated analysis of 2270 cases reported in the literature. *J Oral Pathol Med* 2018 Sep;47(8):731-9.
- Ahmad M, Gaalaas L. Fibro-osseous and other lesions of bone in the jaws. *Radiol Clin* 2018;56(1):91-104.
- da Rocha Vieira R, Biasoli ÉR, Crivelini MM, Miyahara GI. Total spontaneous regression of a central giant cell granuloma after incisional biopsy: a four-year follow-up case report. *J Oral Maxillofac Surg* 2014;72(4):730-6.
- Gulati D, Bansal V, Dubey P, Pandey S, Agrawal A. Central giant cell granuloma of posterior maxilla: first expression of primary hyperparathyroidism. *Case Rep Endocrinol* 2015;2015.
- Tosco P, Tanteri G, Iaquina C, Fasolis M, Rocchia F, Berrone S, Garzino-Demo P. Surgical treatment and reconstruction for central giant cell granuloma of the jaws: a review of 18 cases. *J Cranio-Maxillofac Surg* 2009;37(7):380-7.
- Schreuder WH, van den Berg H, Westermann AM, Peacock ZS, de Lange J. Pharmacological and surgical therapy for the central giant cell granuloma: a long-term retrospective cohort study. *J Cranio-Maxillofac Surg* 2017;45(2):232-43.
- Nogueira RL, Osterne RL, Cavalcante RB, Abreu RT. Surgical Treatment, Oral Rehabilitation, and Orthognathic Surgery After Failure of Pharmacologic Treatment of Central Giant Cell Lesion: A Case Report. *J Oral Maxillofac Surg* 2016;74(12):2567-e1.
- Dolanmaz D, Esen A, Mihmanlı A, Işık K. Management of central giant cell granuloma of the jaws with intralesional steroid injection and review of the literature. *Oral Maxillofac Surg* 2016;20(2):203-9.

How to cite this article: Dhirawani RB, Grover A, Pathak S, Jain S. Central giant cell granuloma: Diagnostic difficulty and multi-stage treatment. *J Oral Med, Oral Surg, Oral Pathol, Oral Radiol* 2019;5(1):22-5.