

Comparative study on evaluation of results of DHS/PFN in management of intertrochanteric fractures femur

Santhosha Jb

Senior Residen, Dept. of Orthopaedics, Kodagu Institute of Medical Science Madikeri, Karnataka, India

***Corresponding Author: Santhosha Jb**

Email: santhoshajb@gmail.com

Abstract

Introduction: Intertrochanteric fractures constitute 38-50% of all femoral fractures' and 5-20% of fractures as whole. These fractures are common in elderly population with the incidence of 180/10000. Though dynamic hip screw is considered as a gold standard in the management of intertrochanteric fractures, its role is debatable in the management of unstable intertrochanteric fractures and intramedullary devices such as PFN are considered better implants for these fractures

Materials and Methods: The study was conducted on 100 patients with intertrochanteric fracture femur attending the outpatient and emergency department of M.L.B. Medical College, Jhansi between December 2015 to November 2017. The patients were assessed clinically and radiologically and were divided randomly in two groups A and B, patients of group A were treated by — ORIF with Dynamic hip screw and of group B were treated by closed /open reduction internal fixation with long PFN. Patients personal information, clinical findings, radiological findings and follow-up findings were recorded in the working proforma as below. The results were evaluated and compared.

Results: The mean age in both the groups was 59.88 ± 16.90 years, In DHS group, there were 5(10%) females and 45(90%) males. In PFN group, there were 13(26%) females and 37(74%) males. There was a male preponderance in both the groups in comparison to the females. In PFN group, there were 30(60%) patients who injured because of fall, while 20(40%) were injured due to RTA. In PFN group, higher number of fall patients were there, while in DHS group, higher number of RTA patients were there. The comparison of mean blood loss in both the groups showed a statistically significant difference ($P < 0.0001$), with a higher mean blood loss in DHS group in comparison to PFN group.

In DHS group, there were 4(8%) patients who had blood loss between 50-100 ml, in 6(12%) the blood loss was between 101-200 ml, in 16(32%) patients it was between 201-300 ml, in 16(32%) patients it was between 301-400 ml and in 8(16%) patients it was more than 400 ml. In PFN group, there were 44(88%) patients who had blood loss between 50-100 ml, in 6(12%) the blood loss was between 101-200 ml and none of the patients had a blood loss of more than 200 ml. In DHS group, 46(92%) patients had no complications, 1(2%) had DVT and 1(2%) had cut out of screw, 2(4%) had infection. In PFN group, 1(2%) had infection, 49(98%) shows no complication.

Interpretation and conclusion: In intertrochanteric fractures femur.

PFN helps in achieving biological reduction and imparts stability. PFN prevents excessive collapse and limb shortening. Thus it helps in achieving overall good functional outcome.

PFN is a load bearing device and gives stability of fracture area proximally and shaft distally, therefore biomechanically PFN is better choice of implant for fixation of peritrochanteric femoral fractures.

PFN is better choice of implant than DHS in terms of blood loss during surgery and early rehabilitation.

Therefore we advocate the use of PFN in comparison to DHS in intertrochanteric fractures femur except when trochanteric entry point for the PFN is fractured.

Keywords: It's comparative study.

Introduction

Intertrochanteric fractures constitute 38-50% of all femoral fractures' and 5-20% of fractures as whole. These fractures are common in elderly population with the incidence of 180/10000, though can occur at any age. With the modern methods of treatment and healthy living, life expectancy of Indian population has almost doubled from 35 years at independence to 66.4 years in 2013 resulting in enormous increase in elderly population. Number of high speed vehicles on roads have also increased tremendously and hence enormous increase in road traffic accidents and these fractures. Though dynamic hip screw is considered as a gold standard in the management of intertrochanteric fractures, its role is debatable in the management of unstable intertrochanteric fractures and intramedullary devices such as PFN are considered better implants for these fractures.

Intramedullary device (PFN) is a load sharing devices, Provide more biomechanical strength than DHS, permit

early mobilization, minimally invasive, can be performed with closed procedures without further jeopardizing the vascularity and soft tissue envelop, permits better rotational stability even in osteoporosed bone of elderly'.

On the other hand, dynamic hip screw is load sparing device, needs extensive soft tissue stripping which further jeopardize, the vascularity of periosteum and bone, but its biomechanical properties like short liver arm, greater implant strength additional antirotation screw in the femoral neck and possibility of anatomical reduction have their own advantages making it gold standard in the management of intertrochanteric fractures.

Materials and Methods

The study was conducted on 100 patients with intertrochanteric fracture femur attending the outpatient and emergency department of M.L.B. Medical College, Jhansi between December 2015 to November 2017.

The patients were assessed clinically and radiologically and were divided randomly in two groups A and B, patients of group A were treated by — ORIF with Dynamic hip screw and of group B were treated by closed /open reduction internal fixation with long PFN.

Patients personal information, clinical findings, radiological findings and follow-up findings were recorded in the working proforma as below. The results were evaluated and compared.

Inclusion Criteria

1. All intertrochantric fractures of <3 week old.

Exclusion Criteria

1. Open fracture.
2. Pathological fracture.
3. Old/neglected fracture of more than 3 weeks old/ or associated fractures in same limb.

Patient not giving consent for any of these modalities of treatment.

Follow up Protocol

Patients were called for follow up every month, on each follow up following aspects were noted

Complaints of pain if any.

Range of hip and knee movements.

Shortening.

Whether the patient assumes his/ her occupation to previous injury state.

Able to sit cross-legged, squat.

Walking ability with or without support.

Results

In our study in DHS group, there were 5(10%) females and 45(90%) males. In PFN group, there were 13(26%) females and 37(74%) males. There was a male preponderance in both the groups in comparison to the females In DHS group, there were 34(68%) patients who injured because of RTA, while 16(32%) were injured due to fall in PFN group, we used long PFN rather than conventional PFN, because conventional PFN has disadvantages of mid thigh pain and stress fracture. In PFN group, there were 30(60%) patients who injured because of fall, while 20 (40%) were injured due to RTA. In PFN group, higher number of fall patients were there, while in DHS group, higher number of RTA patients were there. The comparison of mean blood loss in both the groups showed a statistically significant difference (P < 0.0001), with a higher mean blood loss in DHS group in comparison to PFN group.

In DHS group, there were 4 (8%) patients who had blood loss between 50-100 ml, in 6(12%) the blood loss was between 101-200 ml, in 16(32%) patients it was between 201-300 ml, in 16(32%) patients it was between 301-400 ml and in 8(16%) patients it was more than 400 ml.

In PFN group, there were 44(88%) patients who had blood loss between 50-100 ml, in 6(12%) the blood loss was

between 101-200 ml and none of the patients had a blood loss of more than 200 ml.

In DHS group, 46 (92%) patients had no complications, 1(2%) had DVT and 1(2%) had cut out of screw, 2(4%) had infection.

In PFN group, 1(2%) had infection, 49(98%) shows no complication. In DHS group, in 2(4%) patient the union time was 2-3 months, in 26(52%) it was 3-4 months and in 22(44%) it was more than 4 months. The mean time for union in DHS group was 4.16 ± 0.47 months.

In PFN group, in 26 (52%) patients the union time was 1-2 months, in 22(44%) patient the union time was 2-3 months and in 2(4%) it was 3-4 months. The mean time for union in PFN group was 2.20 ± 0.50 months.

The difference in mean union time was significant (P < 0.0001) with a higher union time in DHS group in comparison to PFN group.

Observations and Results

Table 1: Distribution of patients according to type of fixation (N=100)

| Type of Fixation | Number | Percentage |
|------------------|--------|------------|
| DHS | 50 | 50% |
| PFN | 50 | 50% |
| Total | 100 | 100% |

Table 2: distribution of patients according to age group in both the groups (n=100)

| Age Group | DHS Group (n=50) | | PFN Group (n=50) | |
|-------------|------------------|-----|------------------|-----|
| | No. | % | No. | % |
| <21 years | 0 | 0% | 0% | 0% |
| 21-50 years | 03 | 06% | 07 | 14% |
| 51-70 years | 43 | 86% | 42 | 82% |
| 71-80 years | 04 | 08% | 01 | 02% |
| >80 years | 00 | 0% | 00 | 00% |

Table 3: Distribution of patients according to gender in both the groups(n=100)

| Gender | DHS Group (n=50) | | PFN Group (n=50) | |
|--------|------------------|------|------------------|------|
| | No. | % | No. | % |
| Female | 05 | 10% | 13 | 26% |
| Male | 45 | 90% | 37 | 74% |
| Total | 50 | 100% | 50 | 100% |

Table 4: Distribution of patients according to mode of injury in both the groups(n=100)

| Mode of Injury | DHS Group (n=50) | | PFN Group (n=50) | |
|----------------|------------------|------|------------------|------|
| | No. | % | No. | % |
| RTA | 34 | 68% | 20 | 40% |
| Fall | 16 | 32% | 30 | 60% |
| Total | 50 | 100% | 50 | 100% |

Table 5: Distribution of patients according to duration of surgery in both the groups (N=100)

| Duration of Surgery | DHS Group (n=50) | | PFN Group (n=50) | |
|---------------------|------------------|--------|------------------|--------|
| | No. | % | No. | % |
| <= 60 min | 45 | 90.00% | 23 | 46.00% |
| 61-120 min | 05 | 10.00% | 27 | 44.00% |
| >120 min | 00 | 00 | 00 | 00 |
| Total | 50 | 100% | 50 | 100% |
| Mean ± SD (min) | 51.88 ± 9.09 | | 73.34 ± 16.27 | |
| P Value | 0.0001 | | | |

Table 6: Distribution of patients according to blood loss in both the groups (N=100)

| Blood Loss | DHS Group (n=50) | | PFN Group (n=50) | |
|-------------------|------------------|------|------------------|------|
| | No. | % | No. | % |
| 50-100 ml | 4 | 8% | 44 | 88% |
| 101-200 ml | 6 | 12% | 6 | 12% |
| 201-300 ml | 16 | 32% | 0 | 0% |
| 301-400 ml | 16 | 32% | 0 | 0% |
| >400 ml | 8 | 16% | 0 | 0% |
| Total | 50 | 100% | 50 | 100% |
| Mean ± SD (in ml) | 260.8 ± 91.60 | | 69.68 ± 17.84 | |
| P Value | 0.0001 | | | |

Table 7: Distribution of patients according to complications in both the groups (N=100)

| Complications | DHS Group (n=50) | | PFN Group (n=50) | |
|------------------------------|------------------|-----|------------------|-----|
| | No. | % | No. | % |
| Nil | 46 | 92% | 49 | 98% |
| Infection | 2 | 4% | 1 | 2% |
| DVT | 1 | 2% | 0 | 0% |
| Cut out of screw | 1 | 2% | 0 | 0% |
| Cut-out of stabilizing screw | 0 | 0% | 0 | 0% |

| Time Period | Mean ± SD |
|-------------|--------------|
| 6 weeks | 74.36 ± 0.48 |
| 12 weeks | 77.62 ± 0.49 |
| 3 months | 78.44 ± 0.50 |

Table 8: Comparison of mean harris HIP score at 3 months, 6 months and 12 months in DHS group (N=50)

| Time Period | Mean ± SD |
|-------------|--------------|
| 6 weeks | 80.4 ± 0.49 |
| 12 weeks | 84.5 ± 4.50 |
| 3 months | 88.56 ± 0.50 |

Table 9: Comparison of mean harris HIP score at 3 months, 6 months and 12 months in PFN group (N=50)

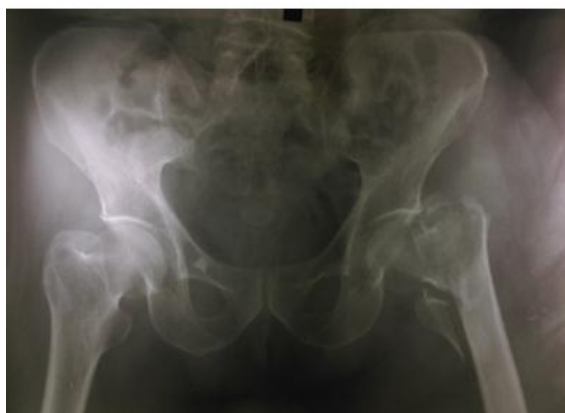| Time Period | Mean ± SD |
|-------------|--------------|
| 6 weeks | 74.36 ± 0.48 |
| 12 weeks | 77.62 ± 0.49 |
| 3 months | 78.44 ± 0.50 |

Table 10: Comparison of mean harris hip score at 3 months, 6 months and 12 months between DHS and PFN groups (N=100)

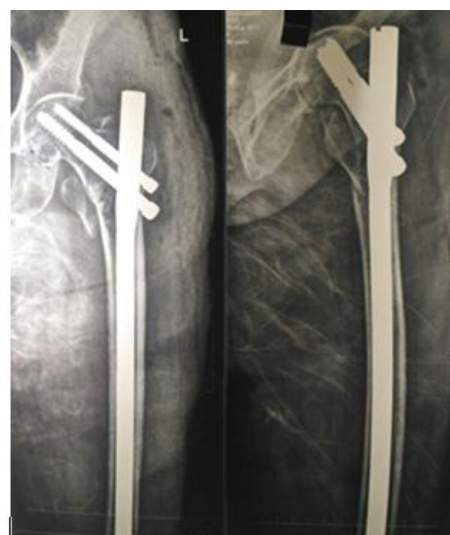
| Time Period | DHS Group [Mean ± SD] | PFN Group [Mean ± SD] | P Value |
|-------------|-----------------------|-----------------------|---------|
| 3 months | 74.36 ± 0.48 | 80.4 ± 0.49 | 0.0001 |
| 6 months | 77.62 ± 0.49 | 84.5 ± 4.50 | 0.0001 |
| 12 months | 78.44 ± 0.50 | 88.56 ± 0.50 | 0.0001 |

Case 1

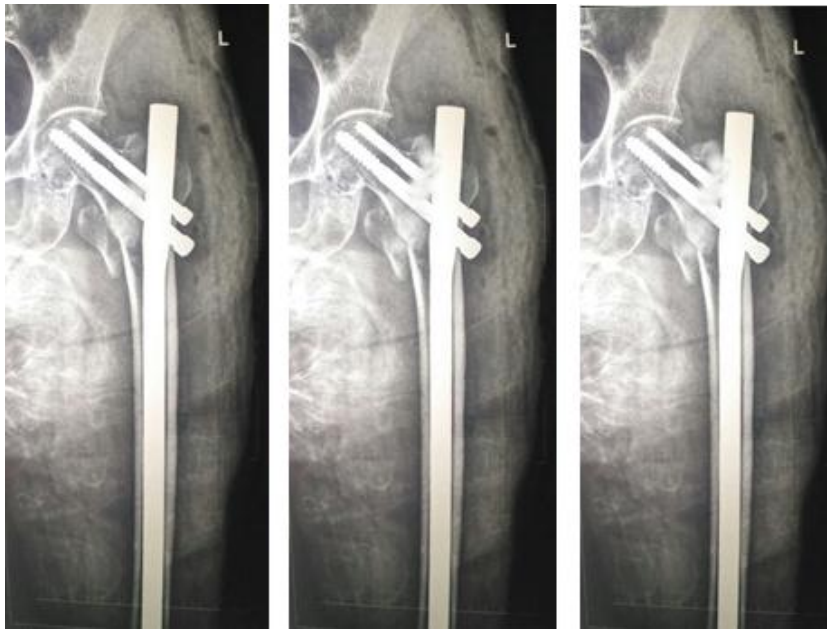
Bhagwati age -60 years sex -female



Pre-op x-ray



Immediate post-op



6 weeks post-op 3 months post-op 6 months post-op



Fig A



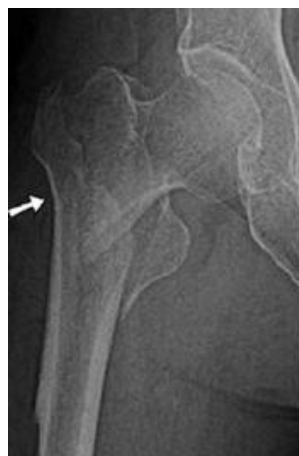Fig B



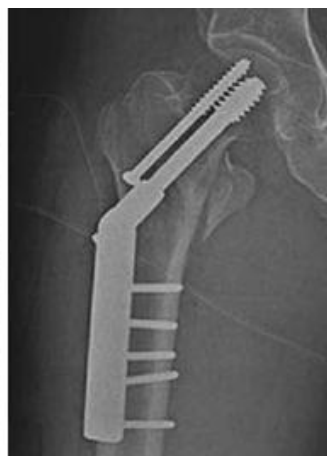Fig C

Case 2

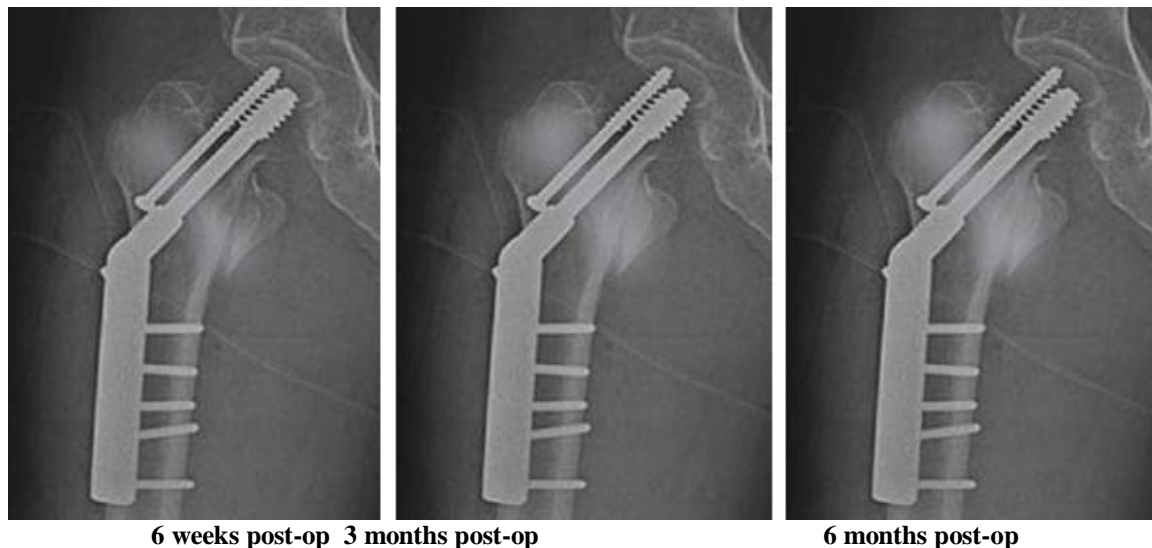
Lalluram Age - 57 Years Sex – Male



Pre-op x-ray



Immediate post-op



Discussion

Pertrochanteric hip fractures still are a major orthopaedic challenge, and those that are unstable have the poorest prognosis

Despite the fact that union rates are high in intertrochanteric hip fractures, functional outcomes tend to be disappointing.

Peritrochanteric fractures AO type 31-A2.2 – A3.3 are unstable & have poorest prognosis. This extremely unstable fracture results in a severe and prolonged period of postoperative disability. Fracture collapse is one of the postoperative complications reported in association with these fractures.

Duty of every orthopaedic surgeon is to get the patient up and out of bed with little pain as soon as possible while causing minimal surgical trauma to the already traumatized patients. In DHS group, there were 34(68%) patients who injured because of RTA, while 16(32%) were injured due to fall.

In PFN group, we used long PFN rather than conventional PFN, because conventional PFN has disadvantages of mid thigh pain and stress fracture.

In PFN group, there were 30(60%) patients who injured because of fall, while 20(40%) were injured due to RTA. In PFN group, higher number of fall patients were there, while in DHS group, higher number of RTA patients were there. The comparison of mean blood loss in both the groups showed a statistically significant difference ($P < 0.0001$), with a higher mean blood loss in DHS group in comparison to PFN group.

In DHS group, there were 4(8%) patients who had blood loss between 50-100 ml, in 6(12%) the blood loss was between 101-200 ml, in 16(32%) patients it was between 201-300 ml, in 16(32%) patients it was between 301-400 ml and in 8(16%) patients it was more than 400 ml.

In PFN group, there were 44(88%) patients who had blood loss between 50-100 ml, in 6(12%) the blood loss was

between 101-200 ml and none of the patients had a blood loss of more than 200 ml.

In DHS group, 46(92%) patients had no complications, 1(2%) had DVT and 1(2%) had cut out of screw, 2(4%) had infection.

In PFN group, 1(2%) had infection, 49(98%) shows no complication. Average screw impaction (Fracture collapse) was 6mm. Jacobs et al reported that the average fracture settling in stable patterns was 5.3 mm and in unstable patterns was 15.7 mm. Sliding of more than 15mm leads to a higher prevalence of fixation failure. Rha et al reported that excessive sliding was the major factor causing fixation failure in unstable fracture patterns. Average limb length discrepancy was 6 mm. Gross et al. found no noticeable functional or cosmetic problems in a study of seventy-four adults who had less than 2 centimetres of discrepancy¹⁰³ and thirty-five marathon runners who had as much as 2.5 centimetres of discrepancy¹⁰⁴.

Normal healing time of a fracture is about 12 wks. Intertrochanteric non-union should be suspected in patients with persistent hip pain that have x-rays revealing a persistent radiolucency at the fracture site 4 to 7 months after fracture fixation. Progressive loss of alignment strongly suggests non-union, although union may occur after an initial change in alignment, particularly if fragment contact is improved.¹⁰⁵ Average healing time in the study was 12 weeks. In DHS group, in 2(4%) patient the union time was 2-3 months, in 26(52%) it was 3-4 months and in 22(44%) it was more than 4 months. The mean time for union in DHS group was 4.16 ± 0.47 months.

In PFN group, in 26(52%) patients the union time was 1-2 months, in 22(44%) patient the union time was 2-3 months and in 2(4%) it was 3-4 months. The mean time for union in PFN group was 2.20 ± 0.50 months.

The difference in mean union time was significant ($P < 0.0001$) with a higher union time in DHS group in comparison to PFN group.

Conclusion

In intertrochanteric fractures

1. PFN helps in achieving biological reduction and imparts stability. PFN prevents excessive collapse and limb shortening. Thus it helps in achieving overall good functional outcome.
2. PFN is a load bearing device and gives stability of fracture area proximally and shaft distally, therefore biomechanically PFN is better choice of implant for fixation of pertrochanteric femoral fractures.
3. PFN is better choice of implant than DHS in terms of blood loss during surgery and early rehabilitation.
4. Therefore we advocate the use of PFN in comparison to DHS in intertrochanteric fractures femure except when trochanteric entry point for the PFN is fractured.

Complications

In DHS group, 46(92%) patients had no complications, 1(2%) had DVT and 1(2%) had cut out of screw, 2(4%) had infection, in PFN group, 1(2%) had infection, 49(98%) shows no complication.

Conflict of Interest: None.

References

1. GS Kulkarni, Rajiv Limaye, Milind Kulkarni, Sunil Kulkarni, Intertrochanteric fractures. IJOYear: 2006; 40(1):16-23
2. Felix Bonnaire Æ Henry Zenker Æ Christoph Lill Andreas T. Weber Æ Berend Linke. Treatment strategies for proximal femur fractures in osteoporotic patients Osteoporos Int 2005;16:S93-S102.
3. Marinella MA, Markert RJ. Clinical predictors of prolonged hospitalization in patients with hip fractures. JCOM 2009;16: 453-458.
4. Bentler SE. The aftermath of hip fracture. Amer J Epidemiol 2009;170:1290-1299.
5. Tejwani N. Helical blade versus sliding hip screw for treatment of unstable intertrochanteric hip fractures: a biomechanical evaluation. Inj 2006;37(10):984-989.
6. Craig Lareau, Md, And Gregory Sawyer, Md. Hip Fracture Surgical Treatment and Rehabilitation. Med Health/Rhode Island 2010;93(4).
7. Jože Ferik, Aleksander Frank. Intramedullary nailing of proximal femoral fracture-Postgraduate School Of Surgical Techniques
8. Dhal A, Varghese M, and Bhasin VB: External fixator of intertrochanteric fracture of the femur. JBJS (Br) 1991;73B:955-958.
9. Jewett EL: One-piece angle nail for trochanteric fractures. J Bone Jt Surg 1941;23:803-810.
10. McLoughlin SW, Wheeler DL, Rider J, Bolhofner B: Biomechanical evaluation of the dynamic hip screw with two- and four-hole side plates. J Orthop Trauma 2000;14(5):318-323.
11. W Schumpelick, PM Jantzen: A new principle in the operative treatment of trochanteric fractures of the femur. J Bone Joint Surg 1955.
12. WK Massie et al Fractures of the hip. J Bone Jt Surg Am 1964;1;46(3):658-690.
13. RC Mulholland, DR Gunn - Sliding screw plate fixation of intertrochanteric femoral fractures
14. The Journal of Trauma and Acute Care Surgery, 1972.
15. William P. Bartels-The Treatment of Intertrochanteric Fractures. J Bone Jt Surg Am 1939;01;21(3):773-775
16. JE Beltran -Condyllo-cephalic nail in pertrochanteric fractures of the neck of the femur. J Bone Jt Surg 1972.
17. Bohler, Collon Treatment of intertrochanteric and subtrochanteric fractures of the hip by the Ender method. J Bone Joint Surg Am 1976;01;58(5):604-611.
18. RT Rosenfeld, DR Schwartz, AH Alter. Leinbach prosthesis in intertrochanteric fractures. J Bone J Surg 1973.
19. Kaufer, Matheull & Sonstegard INJURY: volume 35 issue 10 Oct 2004.
20. Boyd HB and Griffin LL: Classification and treatment of trochanteric fractures. Arch Surg 1949;58:853-866.
21. Wright L. Oblique subcervical (reverse intertrochanteric) fractures of the femur. J Bone J Surg Am 1947;29(3):707-710.
22. Evans EM: The treatment of trochanteric fractures of the femur. J Bone Jt Surg 1949;31B:190-203.
23. Williams and Parker, 1992. Williams WW, Parker BC: Complications associated with the use of the Gamma nail. Inj 1992;23:291.
24. McConnell T, Tornetta P III, Benson E. Gluteus medius tendon injury during reaming for gamma nail insertion. Clin Orthop 2003;407:199-202.
25. Kyle RF, Gustilo RB and Premer RF: Analysis of six hundred and twenty two intertrochanteric hip fractures. J Bone Jt Surg 1979;61A:216-221.
26. William Townsley. The influence of mechanical factors on the development and structure of bone. 1948;6(1):25-46.
27. Gullberg B, Johnell O, Kanis JA. World-wide projections for hip fracture. Osteoporos Int 1997;7(5):407-413.
28. GF Stebbing. Fractures of the upper end of the femur. Br J Surg 1927.
29. Hagino H, Furukawa K, Fujiwara S, et al. Recent trends in the incidence and lifetime risk of hip fracture in Tottori, Japan. Osteoporos Int 2009;20(4):543-548.
30. Mather Cleveland; David M. Bosworth; Frederick R. Thompson; Hudson J. WilsonJR.; Tadao Ishizuka. A Ten-Year Analysis of Intertrochanteric Fractures of the Femur. J Bone Jt Surg Am 1959;01;41(8):1399-1408
31. Norton R, Campbell AJ, Lee-Joe T, Robinson E, Butler M. Circumstances of falls resulting in hip fractures among older people. J Am Geriatr Soc 1997;45(9):1108-1112.
32. EB Riska. Prosthetic replacement in the treatment of subcapital fractures of the femur Acta Orthopaedica, 1971.
33. AJ Ingram, B Bachynski. Fractures of The Hip In Children Treatment and Results. J Bone Jt Surg 1953.
34. R Hedlund, U Lindgren. Trauma type, age, and gender as determinants of hip fracture. J orthopaedic res 1987.
35. Kannus P, Parkkari J, Sievanen H, Heinonen A, Vuori I, Jarvinen M.: Epidemiology of hip fractures Bone. 1996;18(1):57S-63S.
36. JC Lotz, EJ Cheal, WC Hayes. Stress distributions within the proximal femur during gait and falls: implications for osteoporotic fracture. Osteoporosis International, 1995.
37. DS Muckle. Iatrogenic factors in femoral neck fractures. Inj 1976
38. JA Key. Internal fixation of trochanteric fractures of the femur Surgery, 1939.
39. R. C. Murray and J. F. M. Frew, Inverness, Scotland. Trochanteric Fractures of The Femur. J Bone Joint Surg A Plea for Conservative Treatment. From The Orthopaedic Unit, Raigmore Hospital, Inverness 1959
40. GN Spears, JT Owen. The etiology of trochanteric fractures of the femur. J Bone Jt Surg 1949.

41. JS Horn, YC Wang. The mechanism, traumatic anatomy and non-operative treatment of intertrochanteric fracture of the femur. *Br J Surg* 1964.
42. May JMB and Chacha PB: Displacements of trochanteric fractures and their influence on reduction. *J Bone Jt Surg* 1968;50B:318-323.
43. Martyn J Parker. Trochanteric hip fractures Fixation failure commoner with femoral medialization, a comparison of 101 cases. *Acta Orthop Scand* 1996;67(4):329-332.
44. Henrik Palm. Integrity of the Lateral Femoral Wall in Intertrochanteric Hip Fractures: An Important Predictor of a Reoperation. *J Bone Jt Surg (Am)* 2007;89:470-475.45.
45. Roger Anderson; W. B. McKibbin; Ernest Burgess. Intertrochanteric Fractures Non-Operative, Castless, and Ambulatory Method of Treatment. *J Bone Jt Surg Am* 1943;01;25(1):153-168.
46. Cecil E. Newell, M.D. The treatment of trochanteric fractures. 1947;73(2):162-174
47. RH Hafner. Trochanteric fractures of the femur; a review of eighty cases with a description of the " low-nail" method of internal fixation. *J bone jt surg Br* 1951.
48. W Schumpelick, PM Jantzen. A new principle in the operative treatment of trochanteric fractures of the femur. *J Bone Jt Surg* 1955.
49. HG Pugh. Surgical fracture fixation device for the hips- US Patent 2,702,543, 1955
50. Scott Ih..Treatment of intertrochanteric fractures by skeletal pinning and external fixation. *Clin Orthop* 1957;10:326-334.
51. JC Foster. Trochanteric fractures of the femur treated by the Vitallium McLaughlin nail and plate. *J Bone Jt Surg Br* 1958.
52. HB Boyd, SW Lipinski, JH Wiley.Observations on non-union of the shafts of the long bones, with a statistical analysis of 842 patients. *J Bone Jt Surg* 1961.
53. EP Holt. Hip fractures in the trochanteric region: treatment with a strong nail and early weight-bearing.. *J Bone Jt Surg* 1963.
54. Sarmiento A: Intertrochanteric fractures of the femur 150 degree-angle nail plate fixation and early rehabilitation. A preliminary report of 100 cases. *J Bone Jt Surg* 1963;45A:706-722.
55. Dimon JH and Hughston JC: Unstable intertrochanteric fractures of the hip. *J Bone Jt Surg* 1967;49A:440-450.
56. SL Weissman, R Salama. Trochanteric Fractures of the Femur: Treatment with a Strong Nail and Early Weight-bearing. *Clin Orthop Relat Res* 1969.
57. Sarmiento A and Williams EM: Unstable intertrochanteric fracture: Treatment with a valgus osteotomy and I-Beam nail plate. *J Bone Jt Surg* 1970;52:1309-1318.
58. TM Wright, WC Hayes. Fracture mechanics parameters for compact bone—effects of density and specimen thickness. *J Biomech* 1977;10(7):419-425,427-443.
59. J. Sreen Jensen, E. Tondevold & S. Sonne-Holm. Stable Trochanteric Fractures. A Comparative Analysis OF Four Methods Of Internal Fixation. *Acta orthop wand* 1980;51:811-816.
60. Bansal VP, Madan S, Bhaskar SK: External fixator for trochanteric fracture IOACON, 1991.
61. Gargan MF, Gundle R, and Simpson AH: How effective are osteotomies for unstable intertrochanteric fracture. *JBJS (Br)* 1994;76(s):789-792.
62. JW Barros, CD Ferreira, AA Freitas, S Farah.External fixation of intertrochanteric fractures of the femur. *Int Orthop* 1995;19(4):217-219.
63. S.S. Seif-AsaadCorresponding author contact information, A.V.F. Nargol, A. Port. Unstable intertrochanteric fractures treated with the Variwall reconstruction nail. *Inj* 1955;26(6):367-372.
64. O'Brien PJ, Meek RN, Blachut PA, Broekhuysen HM, Sabharwal S. Fixation of intertrochanteric hip fractures: gamma nail versus dynamic hip screw. A randomized, prospective study. *Can J Surg* 1995;38(6):516-20.
65. Kamble KT, Murty BS, Pal: External fixator in unstable intertrochanteric fractures of the femur. *Inj* 1996;27(2):139-142.
66. Wagner R, Weckbach A, Sellmair U, Blattert T. Extra-articular proximal femur fracture in the elderly--dynamic hip screw or intramedullary hip screw for fracture management. *Langenbecks Arch Chir Suppl Kongressbd* 1996;113:963-966.
67. Babst R & Renner N Clinical results using the trochanter stabilizing plate (TSP): the modular extension of the dynamic hip screw (DHS) for internal fixation of selected unstable intertrochanteric fractures. *J Orthop Trauma* 1998; 12(6):392-399.
68. Karl Lunsjö, Leif Ceder, Karl-Göran Thorngren, Björn Skytting, Jan Tidermark, Per-Olof Berntson, Ingemar Allvin, Sigge Norberg, Krister Hjalmar, Sune Larsson, Richard Knebel, Anders Hauggaard and Leif Stigsson. Extramedullary fixation of 569 unstable intertrochanteric fractures: A randomized multicenter trial of the Medoff sliding plate versus three other screw. *plate syst* 2001;72(2):133-140 (doi:10.1080/000164701317323372).
69. W.Y. Kim: Failure of intertrochanteric fracture fixation with a dynamic hip screw in relation to pre-operative fracture stability and osteoporosis. *Int Orthop* 2001;6:360-362
70. Dr. Paulose Chacko Kochi. Experiences with The Management of Trochanteric Fractures of The Hip. *J Kerala Orthop Assoc*: 0973-1709. Vol No. 20 No.1 April 2006.
71. Tanaka Hirofumi et al: Effectiveness of DHS and Trochanter Stabilizing Plate for Unstable Intertrochanteric Fractures. *Orthop Traumatol* 2005;54;(1):101-104.
72. T. Nizegorodcew; G. Maccauro; L. Tafuro; and A. Aulisa: Trochanteric stabilizing plate in the treatment of unstable lateral fractures of the proximal femur. *J Bone Jt Surg Br* 86-B(III)377.
73. Davis J, Harris MB, Duval M, D'Ambrosia R. Pertrochanteric fractures treated with the Gamma nail: technique and report of early results. *Orthop* 1991;14:939-942.
74. Bridle SH, Patel AD, Bircher M, Calvert PT. Fixation of intertrochanteric fractures of the femur. A randomised prospective comparison of the gamma nail and the dynamic hip screw. *J Bone Jt Surg Br* 1991;73:330-4.
75. Lindsey RW, Teal P, Probe RA, Rhoads D, Davenport S, Schauder K. Early experience with the gamma interlocking nail for peritrochanteric fractures of the proximal femur. *J Traumatol* 1991;31:1649-658.
76. Boriani S, De Iure F, Bettelli G, Specchia L, Bungaro P, Montanari G et al. The results of a multicenter Italian study on the use of the Gamma nail for the treatment of pertrochanteric and subtrochanteric fractures: a review of 1181 cases. *Chir Organi Mov* 1994;79:193-203.
77. Hardy DC, Descamps PY, Krallis P, Fabeck L, Smets P, Bertens CL et al. Use of an intramedullary hip-screw compared with a compression hip-screw with a plate for intertrochanteric femoral fractures. A prospective, randomized study of one hundred patients. *J Bone Jt Surg Am* 1998;80:618-630.
78. Radford PJ, Needoff M, Webb JK. A prospective randomised comparison of the dynamic hip screw and the gamma locking nail. *J Bone Jt Surg Br* 1993;75:789-793.
79. Harrington P, Nihal A, Singhania AK, Howell FR. Intramedullary hip screw versus sliding hip screw for unstable intertrochanteric femoral fractures in the elderly. *Inj* 2002;33:23-8.

80. Ahrengart L, Tornkvist H, Fornander P, Thorngren KG, Pasanen L, Wahlström P et al, Lindgren U. A randomized study of the compression hip screw and Gamma nail in 426 fractures. *Clin Orthop Relat Res* 2002;401:209-222.
81. Pajarinen J, Lindahl J, Michelsson O, Savolainen V, Hirvensalo E. Pertrochanteric femoral fractures treated with a dynamic hip screw or a proximal femoral nail. A randomised study comparing post operative rehabilitation. *J Bone Jt Surg Br* 2005;87:76-81.
82. Matthias Knoke, Unstable Intertrochanteric Femur Fractures: Is There a Consensus on Definition and Treatment in Germany? Matthias Knoke, MD, Gertraud Gradl, MD, Andreas Ladenburger, MD, Ivan S. Tarkin, MD, and Hans-Christoph Pape, MD 2013
83. P. Adam. Orthopaedics & Traumatology: *Surg Res* 2014;100(1):S75–S83 2013 Instructional Course Lectures (SoFCOT)
84. Jiajie Yu. Internal fixation treatments for intertrochanteric fracture: a systematic review and meta-analysis of randomized evidence 2015.
85. Butt MS, Krikler SJ, Nafie S, Ali MS. Comparison of dynamic hip screw and gamma nail: a prospective, randomized, controlled trial. *Inj* 1995;26:615-618.
86. Madsen JE, Naess L, Aune AK, Alho A, Ekeland A, Strømsøe K. Dynamic hip screw with trochanteric stabilizing plate in the treatment of unstable proximal femoral fractures: a comparative study with the Gamma nail and compression hip screw. *J Orthop Traumatol* 1998;12:241-248.
87. Crawford CH, Malkani AL, Cordray S, Roberts CS, Sligar W. The trochanteric nail versus the sliding hip screw for intertrochanteric hip fractures: a review of 93 cases. *J Trauma*. 2006;60:325-329.
88. Saudan M, Lübbecke A, Sadowski C, Riand N, Stern R, Hoffmeyer P. Pertrochanteric fractures: is there an advantage to an intramedullary nail?: a randomized, prospective study of 206 patients comparing the dynamic hip screw and proximal femoral nail. *Journal of Orthopaedic Trauma* [2002, 16(6):386-393].
89. Baumgaertner MR, Curtin SL, Lindskog DM. Intramedullary versus extramedullary fixation for the treatment of intertrochanteric hip fractures. *Clin Orthop Relat Res*. 1998;348:87-94.
90. Fogagnolo F, Kfuri M Jr, Paccola C. Intramedullary fixation of pertrochanteric hip fractures with the short AOASIF proximal femoral nail. *Arch Orthop Trauma Surg* 2004;124:31-37.
91. Umberto Tarantino, Francesco Oliva, Angelo Impagliazzo, Antonio Mattei, Giuseppe Cannata, Gian Francesco Spurio Pompili et al. A comparative prospective study of dynamic variable angle hip screw and Gamma nail in intertrochanteric hip fractures 2005, Vol. 27, No. 18-19, Pages 1157-1165 (doi:10.1080/09638280500055875)
92. JO Anglen, JN Weinstein - The Journal of Bone & Joint Surgery, 2008. Nail or Plate Fixation of Intertrochanteric Hip Fractures: Changing Pattern of Practice: A Review of the American Board of Orthopaedic Surgery Database *Bone Joint Surg Am* 2008;01:90(4):700-707. doi: 10.2106/JBJS.G.00517.
93. Laufer, Yocheved; Lahav, Miriam: Functional Recovery Following Pertrochanteric Hip Fractures Fixed with the Dynamic Hip Screw vs. the Percutaneous Compression Plate. *Sci World J* 2005 Vol. 5.
94. Antonio Moroni, Cesare Faldini, Francesco Pegreffì "Dynamic Hip Screw Compared with External Fixation for Treatment of Osteoporotic Pertrochanteric Fractures" *J Bone Jt Surg (Am)*. 2005;87:753-759.
95. K Søballe, F Christensen - The Journal of bone and joint surgery Laceration of the superficial femoral artery by an intertrochanteric fracture fragment. *J Bone Joint Surg Am* 1987;69(5):781-783.
96. WK Pun; SP Chow; KC Chan; FK Ip; JC Leong. Effusions in the knee in elderly patients who were operated on for fracture of the hip.
97. Michael J. Gardner, Mohit Bhandari, Brandon D, Lawrence, David L. Helfet. Treatment of intertrochanteric hip fractures with the AO trochanteric fixation nail. *Orthop* 2005;28:2.
98. Larsson S, Friberg S, Hansson LI. Trochanteric fractures. Influence of reduction and implant position on impaction and complications. *Clin Orthop Relat Res* 1990;(259):130-139.
99. T Morihara, Y Arai, S Tokugawa, S Fujita, K Chatani, T Kubo. Proximal Femoral Nail For Treatment Of Trochanteric Femoral Fractures. *J Orthop Surg* 2007;15(3):273-277.
100. Jacobs RR, McClain O, Armstrong HJ. Internal fixation of intertrochanteric hip fractures: a clinical and biomechanical study. *Clin Orthop* 1980;146:62
101. Rha JD, Kim YH, Yoon SI, et al. Factors affecting sliding of the lag screw in intertrochanteric fractures. *Int Orthop* 1993;17(5):320-324
102. Gross RH. Leg length discrepancy: how much is too much? *Orthop* 1978;1:307-310.
103. Gross, R. H.: Leg length discrepancy in marathon runners. *Am J Sports Med* 1983;11:121-124.
104. Baumgaertner MR. Intertrochanteric hip fracture. In: Browner BD, Jupiter JB, Levine AM, Trafton PG, eds. *Skeletal Trauma*. Philadelphia, PA: Saunders; 2003:1776-1816.
105. Sperner G, Wanitschek P, Benedetto KP, Glötzer W. Technical errors and early complications of osteosynthesis of pertrochanteric femoral fractures using the dynamic hip screw. *Unfallchirurg* 1989;92(12):5716.
106. TR Davis; JL Sher; A Horsman; M Simpson; BB Porter; and RG Checketts. Intertrochanteric femoral fractures. Mechanical failure after internal fixation. *J Bone Jt Surg Br* 1990;72-B(1):26-31.
107. M.J.Parker. Cutting out of the Dynamic Hip Screw Related to its position. *JBJS[Br]* 1992;74-B:625.
108. MR Baumgaertner, SL Curtin, DM Lindskog and JM Keggi. The value of the tip-apex distance in predicting failure of fixation of peritrochanteric fractures of the hip. *J Bone Joint Surg Am* 1995;77:1058-1064.
109. M. R. Baumgaertner, MD, Associate Professor; and B. D. Solberg, MD. Awareness Of Tip-Apex Distance Reduces Failure Of Fixation Of Trochanteric Fractures Of The Hip. *J Bone Joint Surg Br* 1997;79-B(6):969-97.
110. Pervez H, Parker MJ, Vowler S: Prediction of fixation failure after sliding hip screw fixation. *Injury*. 2004 Oct;35(10):994-8.
111. Gill JB, Jensen L, Chin PC, Rafiei P, Reddy K, Schutt RC Jr. Intertrochanteric hip fractures treated with the trochanteric fixation nail and sliding hip screw. *J Surg Orthop Adv* 2007;16(2):62-66.
112. Bendo JA, Weiner LS, Strauss E, Yang E. Collapse of intertrochanteric hip fractures fixed with sliding screws. *Orthop Rev* 1994;(suppl):30-37.
113. A Lenich, H Vester, M Nerlich, E Mayr, U Stöckle. Clinical comparison of the second and third generation of intramedullary devices for trochanteric fractures of the hip—Blade vs screw. *Inj* 2010;41(12):1292-1296.
114. RICHARD F. KYLE. Fractures of the Proximal Part of the Femur. *J Bone Joint Surg Am* 1994;01;76(6):924-950.
115. Andrew Pollak. SpotCheck: Intertrochanteric fracture treatment. AAOS Now. January 2009.

116. R.K.J Simmermacher, A.M Bosch, Chr Van der Werken. The AO/ASIF-proximal femoral nail (PFN): a new device for the treatment of unstable proximal femoral fractures. *Inj* 1999;30(5):327-332.
117. Joachim Windolf, Dirk A. Hollander, Mohssen Hakimi, Wolfgang Linhart Pitfalls and complications in the use of the proximal femoral nail. *Langenbeck's Arch Surg* 2005;390(1):59-65.
118. Pavelka T, Kortus J, Linhart M. Osteosynthesis of proximal femoral fractures using short proximal femoral nails. *Acta Chir Orthop Traumatol Cech* 2003;70(1):31-38.
119. Christophe Sadowski, MD; Anne Lübbeke, MD; Marc Saudan, MD; Nicolas Riand, MD; Richard Stern, MD; Pierre Hoffmeyer, MD. Treatment of Reverse Oblique and Transverse Intertrochanteric Fractures with Use of an Intramedullary Nail or a 95° Screw-Plate: A Prospective, Randomized Study. *J Bone Jt Surg Am* 2002;01;84(3):372-381.
120. Christian Boldin, Franz J Seibert, Florian Fankhauser, Gerolf Peicha, Wolfgang Grechenig and Rudolf Szyszkowitz. The proximal femoral nail (PFN) - a minimal invasive treatment of unstable proximal femoral fractures: A prospective study of 55 patients with a follow-up of 15 months. 2003;74(1):53-58.

How to cite this article: Santhosha Jb, Comparative study on evaluation of results of DHS/PFN in management of intertrochanteric fractures femur. *J Surg Allied Sci* 2019;1(1):17-25.