

## Histopathological spectrum of meningiomas: A retrospective study

Niranjan J<sup>1\*</sup>, Vishnu Priya V<sup>2</sup>, Shivarudrappa A S<sup>3</sup>

<sup>1</sup>Associate Professor, <sup>2</sup>Tutor, <sup>3</sup>Professor and HOD, Dept. of Pathology, Vydehi Institute of Medical Sciences, Bangalore, Karnataka, India

\*Corresponding Author: Niranjan J

Email: dmiranjanjayaram@gmail.com

Received: 25<sup>th</sup> September, 2018

Accepted: 26<sup>th</sup> October, 2018

### Abstract

**Aims and Objectives:** To study the incidence of meningiomas, their histomorphological variants and WHO grading.

**Materials and Methods:** It is a retrospective study conducted in the department of Pathology, Vydehi institute of medical sciences and research centre, Bangalore. About 57 cases of meningiomas diagnosed from period between 2015-2018 were reviewed retrospectively.

**Observation & Results:** Meningiomas were most common in the age group of 41-50yrs (36.84%) followed by 51-60yrs (26.32%). Out of the 57 cases, 36 were female (63.16%) and 21 were male (36.84%). Most common histological subtype was found to be Meningothelial meningioma in 19 cases (33.33%) and least common being Rhabdoid and Anaplastic type (1.75% each). Majority of the cases were found to be intracranial (82.46%) in comparison to the spinal meningiomas (15.79%). One of the cases was found to have extracranial origin (1.75%). About 92.98% tumors belonged to WHO GRADE I whereas WHO GRADE II and WHO GRADE III tumor comprise 3.51% each of total cases.

**Conclusion:** Meningiomas account for 28-30% of primary central nervous system tumors and unveil a heterogeneous histopathology. The histological appearance of meningioma determines the grading for the management of the various subtypes and also associated with patient's prognosis. Hence a continuous revision of histopathological classification systems is required to improve the diagnostic accuracy.

**Keywords:** CNS tumors, Meningioma, WHO grading, Anaplastic.

### Introduction

Meningiomas are a group of slow growing primary intracranial neoplasms.<sup>1</sup> It was termed as Meningioma by Cushing in 1922.<sup>2</sup> They are said to originate from the arachnoidal cap cell, a type of meningiothelial cell in the arachnoid membrane. The arachnoid cells are most prevalent near the collections of arachnoid villi at the dural venous sinuses and their tributaries.<sup>3</sup>

Meningiomas account for about 15% of the intracranial tumours. A vast majority of them being histomorphologically benign. More than 90% of all meningiomas are solitary. Exact etiology is unknown. Ionizing radiation is the only established environmental risk factor for meningioma, with higher risk among people who were exposed in childhood than as adults. They can occur at any age, median age being 65 years, with risk increasing with increasing age.<sup>1</sup> It has a female preponderance, with a female/male ratio of approximately 2:1 intracranial and 10:1 on the spine.<sup>3</sup>

Meningiomas produce neurological signs and symptoms due to compression of adjacent structures; the specific deficits depend on tumour location. Headache and seizures are common nonspecific presentations.<sup>4</sup> Although benign, they have a broad spectrum of clinical characteristics, and histologically distinct subsets that are associated with high risk of recurrence. The present grading system is based on histological features found in many clinicopathological studies to be of prognostic importance. However, the criteria given are hampered by subjective assessments and lack of precise findings that can make the practical application difficult.<sup>4</sup> The WHO 2016 classification (Table 1) aims to better predict these divergent characteristics of meningiomas with histological grading

system, which is important for the treatment, prognosis and follow up of the patients.<sup>5,6</sup>

**Table 1: WHO 2016 grading of meningioma and its variants**

Grade	Variants
<b>Grade I</b> Histologic subtypes without anaplasia	Meningiothelial Fibrous Transitional Psammomatous Angioblastic Secretory Lymphoplasmocytic rich
<b>Grade II</b> Histologic subtypes with 4-19 Mitotic figures per 10 HPF and brain invasion.	Chordoid Clear cell Atypical
<b>Grade III</b> Histologic subtypes with > 20 Mitotic figures per 10 HPF.	Papillary Rhabdoid Anaplastic

### Aims and Objectives

- To study the incidence of meningiomas.
- To study the histomorphological variants of meningiomas.

### Materials and Methods

The present study is a retrospective study conducted in the department of Pathology, Vydehi institute of medical sciences and research centre, Bangalore. During this study,

57 cases of meningiomas diagnosed from period from 2015 to 2018 were reviewed retrospectively.

Biopsy slides stained with H&E and case history were retrieved from archival material and were studied in detail with respect to site, age and sex distribution, histomorphological features and WHO grade of tumour.

### Observation and Results

In our study, a total of 57 cases of meningiomas were studied histologically 36 patients were female (63.16%) and 21 patients were male (36.84%). Hence, female predominance was seen in meningioma (Table 2). Most common age group for presentation of meningioma is 41–50 years (36.84%), which consists of 21 cases. In the age group of 0–10 years, no case was recorded (Table 3). Among them the most common variant was meningothelial meningioma, 19 cases (33.33%), followed by transitional consisting of 16 cases (28.07%), angiomatous consisting of 6 cases (10.53%), psammomatous and fibroblastic, each variant consisting of 5 cases each (8.77%), followed by microcystic and atypical variant each consisting of 2 cases (3.51%). Least being the rhabdoid and anaplastic variant, one case each (1.75%). So the most common variant was the meningothelial meningioma (Table 4). According to the World Health Organization (WHO) grading, WHO grade 1 consists of 53 cases (92.98%), WHO grade II consists of 2 cases (3.51%) of meningioma, among them two cases were of atypical meningioma. WHO grade III consists of two cases (3.51%), one each of rhabdoid and anaplastic meningioma. Most meningioma were benign in WHO grade 1 (Table 5). Among all other histological variants of meningiomas, most of the 47 cases (82.46%) were intracranial, 9 cases were of spinal origin (15.79%). One case had an extracranial origin, arising from scalp (1.75%). So the most common site of meningioma in CNS is intracranial (Table 6).

### Histomorphological Variants of Meningioma

#### Angioblastic Meningioma

Features numerous blood vessels, which often constitute a greater proportion of the tumour mass than do the intermixed meningioma cells.<sup>1</sup> (Fig. 1)

#### Fibrous Meningioma

A variant of meningioma that consists of spindled cells forming parallel, storiform, and interlacing bundles in a collagen-rich matrix.<sup>1</sup> (Fig. 2)

#### Meningothelial Meningioma

A common variant of meningioma, with medium-sized epithelioid tumour cells forming lobules, some of which are partly demarcated by thin collagenous septa.<sup>1</sup> (Fig. 3)

#### Transitional Meningioma

Shows lobular and fascicular foci side by side with conspicuous tight whorls and psammoma bodies.<sup>1</sup>

#### Microcystic Meningioma

Characterized by cells with thin, elongated processes encompassing microcysts and creating a cobweb-like background.<sup>1</sup> (Fig. 4)

#### Psammomatous Meningioma

Variant of meningioma with predominance of psammoma bodies over tumour cells.<sup>1</sup>

#### Atypical Meningioma

Intermediate grade between benign and malignant forms, with increased mitotic activity, brain invasion on histology, or at least three of the following features: increased cellularity, small cells with a high nuclear-to-cytoplasmic ratio, prominent nucleoli, sheeting and foci of spontaneous necrosis.<sup>1</sup> (Fig. 5)

#### Rhabdoid Meningioma

Uncommon variant of meningioma that consists primarily of rhabdoid cells: plump cells with eccentric nuclei, open chromatin, a prominent nucleolus, and prominent eosinophilic paranuclear inclusions, appearing either as discernible whorled fibrils or compact and waxy.<sup>1</sup> (Fig. 6)

#### Anaplastic Meningioma

A meningioma that exhibits overtly malignant cytology (resembling that of carcinoma, melanoma, or high-grade sarcoma) and/or markedly elevated mitotic activity.<sup>1</sup>

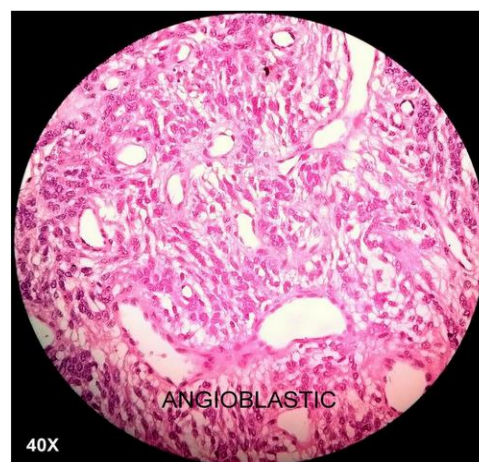


Fig. 1

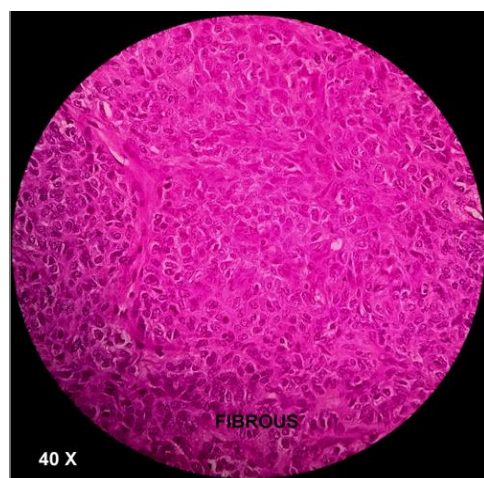

Fig. 2

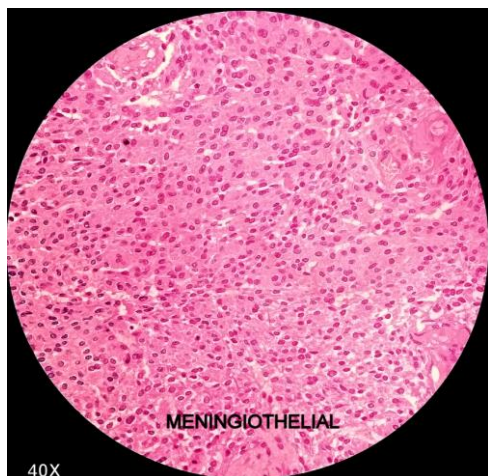


Fig. 3

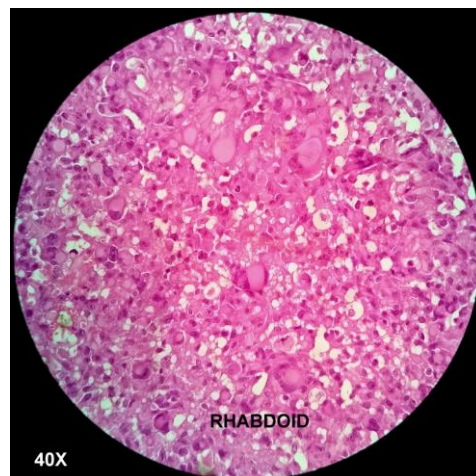


Fig. 6

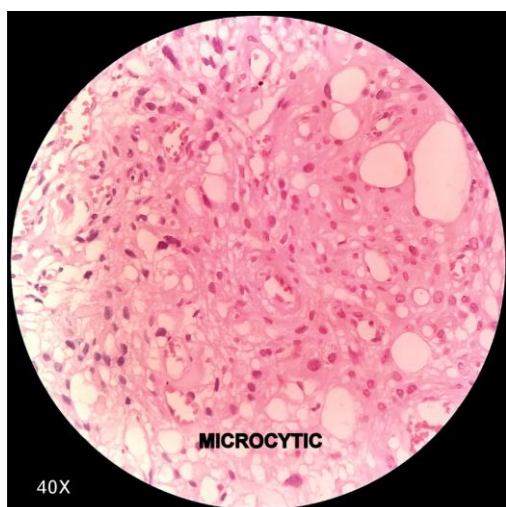


Fig. 4

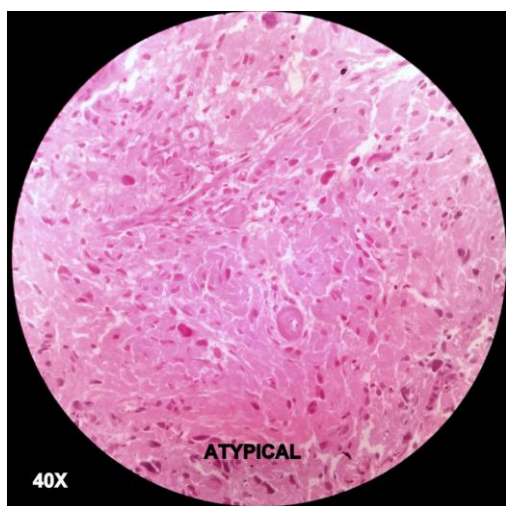


Fig. 5

Table 2: Sex distribution

Gender distribution	No of cases	Percentage
Male	21	36%
Female	36	64%

Table 3: Age distribution

Age distribution	No of cases	Percentage
1-10 yr	0	0
11-20yr	4	7.02%
21-30yr	6	10.53%
31-40yr	4	7.02%
41-50yr	21	36.84%
51-60yr	15	26.32%
61-70yr	5	8.77%
71-80yr	2	3.51%
81-90yr	0	0.00%
91-100yr	0	0.00%
Total	57	100%

Table 4: Histopathological variants

Histomorphology	No of cases	Percentage
Meningiothelial	19	33.33%
Psammomatous	5	8.77%
Transitional	16	28.07%
Angiomatous	6	10.53%
Fibroblastic	5	8.77%
Microcystic	2	3.51%
Atypical	2	3.51%
Rhabdoid	1	1.75%
Anaplastic	1	1.75%
Total	57	100%

Table 5: WHO Grading

WHO	No of cases	Percentage
I	53	92.98%
II	2	3.51%
III	2	3.51%
Total	57	100%

**Table 6: Location**

Location	No of cases	Percentage
Intracranial	47	82.46%
Spinal	9	15.79%
Extracranial	1	1.75%
Total	57	100%

## Discussion

Meningiomas account for 28-30% of primary central nervous system tumours and constitute 15% of the intracranial tumours and about 25% of the intraspinal tumours.<sup>1</sup>

Meningiomas unveil a heterogeneous histopathology, which may explain the repeated revisions of classification schemes. This study presents a review of 57 meningiomas classified according to the latest WHO classification, with the aim to investigate the frequency of various histopathological features.

Reddy. R et al<sup>5</sup> states that the most common age group between 40-60-yrs Male: Female -1:4. Out of 121 CNS lesions during the study period 19 cases were reported as Meningiomas. Out of 19 cases, majority were benign 89.6%, Atypical were 5.2% and Anaplastic were 5.2% of meningiomas.

Shah SR et al<sup>6</sup> study shows that most of the patients were female 34 (67%). The commonest age group was 40-59 years. The commonest site of tumor was convexity of brain 26 (60%). The commonest histopathological type was meningotheliomatous meningioma (39%). The 92% of the meningioma was WHO Grade I tumor.

Malik V et al<sup>7</sup> showed that meningiomas accounted for 20.5% of all CNS lesions. Average age of patients was 47.6 years. Females had higher predilection for meningioma. Cerebral convexity was the most favoured site (42.1%). Grade I meningiomas were 85.7%, grade II were 11.9% and grade III were 2.4%. Transitional meningioma was most common variant (53.2%) followed by atypical type (11.1%) and meningothelial type (9.5%). Males had much higher incidence of grade II meningiomas (7.9%) and grade III meningiomas (2.4%).

Desai P. B. et al<sup>8</sup> study showed that most common variant is meningothelial meningioma, 32 (64%) cases. According to the World Health Organization (WHO) grading, the most common WHO grade is grade I consisted of 45 (90%) cases and the most common site being intracranial. Female predominance was seen in meningioma.

Gadgil NM et al<sup>9</sup> study showed that the commonest age group affected was 41-60 years. Female predominance was seen. Commonest site was intracranial (88.2%). The meningeal lesions consisted of meningioma (96.6%) and non-meningioma lesions (3.4%). The commonest histopathological type of meningioma was transitional (24.2%) followed by meningotheliomatous (22.8%). The 85.6% of the meningioma was WHO Grade I tumor.

Patil, P. R et al,<sup>10</sup> Raza AKMM et al,<sup>11</sup> Jat KC et al,<sup>12</sup> Narmadha R et al,<sup>13</sup> Shrilakshmi S et al,<sup>14</sup> Samadi N. et al<sup>15</sup> studies show similar results

One of the cases had an extracranial origin and arising from scalp. Primary extracranial meningiomas of head and neck region are rare tumours, the majority being a secondary location of a primary intracranial tumour, accounting for 1-2% of all meningiomas and with a generally favourable prognosis.<sup>16</sup> According to Rushing EJ<sup>17</sup> et al, the vast majority of tumors affected the skin of the scalp.

## Conclusion

Meningiomas are slow growing tumors originating from meningeal layer of the brain and spinal cord, more common in females. Adults are most commonly affected than elderly. The histological subtypes and grading of meningiomas are associated with the patient's prognosis and management. Meningiothelial variant being the most common variant, belonging to WHO grade I meningiomas, are readily curable by resection.

**Conflict of Interest:** None.

## References

- Perry A, Louis DN, Scheithauer BW, Budka H, Von Deimling A. Meningiomas. WHO classification of tumours of the central nervous system. 2016;4:232-45.
- Cushing H. The meningiomas (dural endotheliomas): their source, and favoured seats of origin. *Brain* 1922;45:282-316.
- Thomas BG, Moen BH, Torp SH. The histopathological spectrum of human meningiomas. *Int J Clin Exp Pathol* 2012;5(3):231-42.
- Gattu. V. Histopathological analysis of meningiomas- A retrospective study. *SAS J Surg* 2017;3(1):25-9.
- Reddy. R. Histopathological spectrum of meningioma and its variants. *Asian Pac J Health Sci* 2016;3(1):151-5.
- Shah SR, Gonsai N, Makwana R. Histopathological study of meningioma in civil hospital, Ahmedabad. *Int J Curr Res Rev* 2013;5(3):76-82.
- Malik V, Punia RPS, Malhotra A, Gupta V. Clinicopathological study of meningioma: 10 year experience from a tertiary care hospital. *GJRA* 2018;7:1.
- Desai, P. B., & Patel, D. Histopathological study of meningioma. *Int J Med Sci Public Health* 2016;5:327-30.
- Gadgil NM, Margam SR, Chaudhuri CS, Kumavat PV. The histopathological spectrum of meningeal neoplasms. *Indian J of Pathology Oncol* 2016;3(3):432-6.
- Patil, P. R., & Sondankar, D. Clinicopathological Study of Meningioma. *Int J Med Res Rev* 2016;4:592-601.
- Raza AKMM, Ahmed F, Munn TA. Histomorphological spectrum of meningioma with variants and grading. *Adv Surg Res* 2017;1(1):15-7.
- Jat KC, Vyas SP, Bihari NA, Mehra K. Central nervous system tumors: a histopathological study. *Int J Res Med Sci* 2016;4:1539-45.
- Narmadha R, Dhanalakshmi S, Priyadarshini M, et al. Histomorphological spectrum of central nervous system tumours- A three-year retrospective descriptive study in a tertiary care centre. *J Evolution Med. Dent Sci* 2017;6(43):3362-6.
- Shrilakshmi S. Meningiomas: a clinicopathological study. *Int J Med Res Health Sci* 2015;4:827-31.
- Samadi, N., & Ahmadi, S. A. Meningioma: A clinicopathological evaluation. *Malays J Med Sci* 2007;14:46-52.

16. Possanzini P. Primary extra-cranial meningioma of head and neck: clinical, histopathological and immunohistochemical study of three cases. *Acta otorhinolaryngol Ital* 2012;32:336-8.
17. Rushing E, Bouffard J, McCall S, Olsen C, Mena H, Sandberg G et al. Primary Extracranial Meningiomas: An Analysis of 146 Cases. *Head Neck Pathol* 2009;3(2):116-30.

**How to cite this article:** Niranjan J, Priya VV, Shivarudrappa AS. Histopathological spectrum of meningiomas: A retrospective study. *Indian J Pathol Oncol* 2019;6(2):256-60.