

A case report of adenoid cystic carcinoma of larynx: A distinctly rare entity

Veenaa Venkatesh¹, Riyana R Thaj^{2,*}

¹Associate Professor, ²Post Graduate, Dept. of Pathology, Karpagam Faculty of Medical Science and Research, Coimbatore, Tamil Nadu, India

*Corresponding Author: Riyana R Thaj

Email: riyanathaj@gmail.com

Received: 15th October, 2018

Accepted: 24th November, 2018

Abstract

Introduction: Malignant tumors of minor salivary glands are relatively uncommon. In the larynx, ACC is extremely rare. These tumors are commonly arise in the subglottic region of larynx.

Materials and Methods: We present an unusual case of ACC in a 50 year old male. On laryngoscopic examination a growth was seen in the arytenoid region of larynx. An incisional biopsy was taken and sent for HPE

Results: A tumor was seen in the submucosal region with typical cribriform pattern and myxoid matrix. A diagnosis of ACC was noted

Conclusion: ACC is a very slow growing tumor but is notorious for local recurrence and distant metastasis. Hence caution is needed in such cases, especially when the tumor is seen beneath the mucosa. Failure of diagnosis ACC may lead to fatal outcome in some cases.

Keywords: Adenoid cystic carcinoma, Larynx, Prognosis.

Introduction

Adenoid Cystic Carcinoma (ACC) is a malignant salivary gland tumor, more common in minor salivary glands. It constitutes 2-4% of head and neck carcinomas.¹ There is no distinct risk factor for this malignancy. It is more common in minor salivary glands of oral cavity, most common site being hard palate followed by nasal cavity, paranasal sinuses, pharynx and larynx.² Larynx ACC is extremely rare. ACC of larynx is not associated with history of smoking unlike Squamous cell carcinoma (SCC).^{3,4} Although the clinical behaviour of extra laryngeal ACC is well known, currently only limited statistical case series are available for laryngeal ACCs.

Histologically ACC consists of cribriform, tubular and solid subtypes.⁵ In all these types the cells are basaloid with mucinous or hyaline matrix. Despite the etiological and histological differences between laryngeal SCC and ACC, basaloid variant of SCC needs to be distinguished from ACC, since basaloid SCC is well known entity in larynx and prognosis is much more favourable for ACC compared to basaloid SCC.

Laryngeal ACC tends to infiltrate into the surrounding structures slowly, such as thyroid and esophagus.⁶ Distant metastasis is more to lungs although regional lymph node deposits are uncommon. This tumor is also known for local recurrence.

We report a case of ACC of arytenoid region of larynx, diagnosed by histopathological examination of a direct laryngoscopy biopsy.

Case Report

We report a case of 56 year old male presenting with discomfort in the neck region during swallowing. The patient came to the ENT department. A complete clinical examination was done. No nodes were palpable. No hoarseness of voice was noted. A direct laryngoscopic

examination was done. A growth was identified in the right arytenoid region. An incisional biopsy was taken and sent for pathological examination.

Gross examination showed three tiny grey white soft tissue bits; altogether measured 2x1x0.5 cm, all of which were processed and embedded.

Microscopically, multiple sections studied showed fragments of tissue with a structure of stratified squamous epithelium with focal ulceration (Fig. 1).

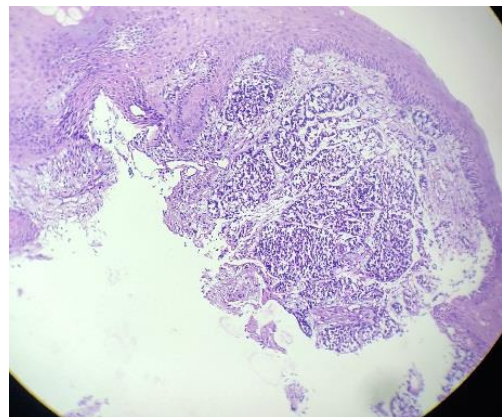


Fig. 1: Laryngeal biopsy showing an infiltrative tumor beneath the squamous epithelium. (H&E.10X)

Beneath the epithelium is seen an infiltrative tumor composed of basaloid cells arranged in cribriform pattern, small nests and in cords. The individual cells had scant cytoplasm and oval hyperchromatic nucleus (Fig. 2).

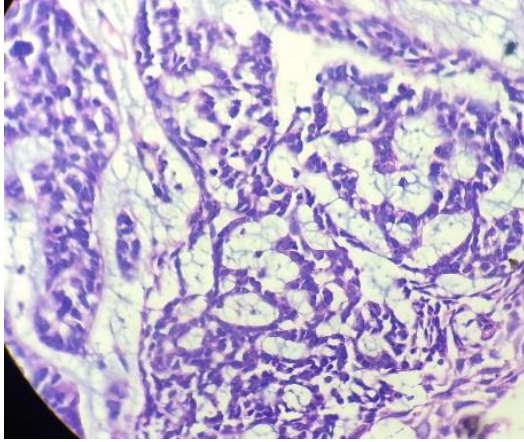


Fig. 2: Cribriform pattern of arrangement of tumor cells. (H&E.40X)

The intervening stroma was myxoid (Fig. 3).

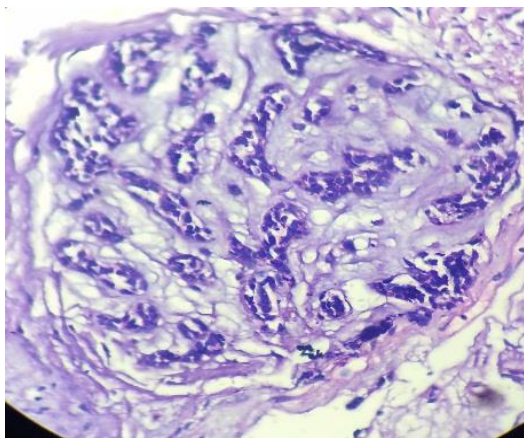


Fig. 3: Microscopy showing myxoid stroma characteristically seen in adenoid cystic carcinoma. (H&E.40X)

Mild nuclear atypia was noted. With these histopathological findings, a diagnosis of adenoid cystic carcinoma of larynx was made.

Discussion

ACC of larynx is a rare tumor, accounting for <1% of laryngeal malignancies. According to a study by Guanqiao et al, 175 well documented cases of ACC were identified the larynx.⁷ Laryngeal carcinomas are divided into three sub types depending on location: supraglottic, glottic and subglottic. Patients with supraglottic tumors present with dysphagia, patients with tumors in the glottis present with hoarseness or dyspnoea. However few patients are asymptomatic and reach the advance stage when they present to the hospital.^{9,10}

Among the laryngeal carcinomas, SCCs are the most common. Smoking is an important etiological factor for laryngeal SCC which leads to oxidative stress and elevated Reactive Oxygen Species which in turn lead to carcinoma.¹⁰ Mean age is sixth and seventh decade.

Less common tumors of larynx include other epithelial tumors, soft tissue tumors and neuroendocrine tumors. Laryngeal salivary gland carcinomas are rare because of low density of glands in the larynx. Among the salivary gland malignancies, ACC is the most common type. ACC is not associated with smoking which is different from SCC. ACC is a slow growing tumor and patients are asymptomatic for long period. Lymph node metastasis is uncommon in ACC but metastasis to other site like lung occur. Most common site in larynx is subglottis. The symptoms of ACC if present, include dyspnoea, dysphagia and dysphonia. Because of its indolent behaviour and late diagnosis, ACC is fatal in many cases. Hence investigations like CT are more important in early diagnosis. ACC occurs as a submucosal tumor and hence direct invasion into the adjacent structures including surrounding soft tissues and thyroid occur.¹¹

Histopathologically, three patterns are seen in ACC: cribriform, tubular and solid. Cribriform pattern is the most common and has the best prognosis. The solid pattern is the least common and has aggressive course.¹² Total laryngectomy is the treatment of choice for laryngeal ACCs. Some studies have shown that chemotherapy has a positive response in advanced cases.

The differential diagnosis to be considered in laryngeal ACC is basaloid SCC. However basaloid SCC shows tumor nests arising from the squamous epithelium of the mucosal layer, shows peripheral palisading of tumor cells and occasional keratinization. These features are absent in ACC, in which we can see tumor lying beneath the epithelium and shows myxoid matrix in most cases.

Conclusion

Laryngeal ACC are rare tumors accounting for less than 1% of laryngeal malignancies. The case report here is cribriform type of ACC. These tumors should be suspected when they are located in the submucosal location especially in a patient who is not at risk for SCC. Further radiological evaluations should be done to assess the extent of tumor. Surgery with wide margins with or without chemotherapy is recommended for these cases. Perineural invasion should be looked for and follow up of patient is mandatory to detect recurrence and distant metastasis.

Conflict of Interest: None.

References

1. Singh S, Gokkulakrishnan, Jain J, Pathak S, Singh KT. Adenoid cystic carcinoma of buccal mucosa. *J Maxillofac Oral Surg* 2010;9(3):273-6.
2. Ajila V, Hegde S, Nair GR, Babu SG. Adenoid cystic carcinoma of the buccal mucosa: A case report and review of the literature. *Dent Res J (Isfahan)* 2012;9(5):642-6.
3. Marchiano E, Chin OY, Fang CH, Park RC, Baredes S, Eloy JA. Laryngeal Adenoid Cystic Carcinoma: A Systematic Review. *Otolaryngol Head Neck Surg* 2016;154(3):433-9.
4. Tincani AJ, Del Negro A, Araújo PP, Akashi HK, Martins AS, Altemani AM, et al. Management of salivary gland adenoid cystic carcinoma: institutional experience of a case series. *Sao Paulo Med J* 2006;124:26-30.

5. Szanto PA, Luna MA, Tortoledo ME, White RA. Histologic grading of adenoid cystic carcinoma of the salivary glands. *Cancer*. 1984;54(6):1062-9.
6. Ganly I, Patel SG, Coleman M, Ghossein R, Carlson D, Shah JP. Malignant minor salivary gland tumors of the larynx. *Arch Otolaryngol Head Neck Surg* 2006;132:767-70.
7. Kozhanov LG, Volchenko NN, Romanova ES, Kozhanov AL, Kostin AY. [Adenoid cystic carcinoma of the larynx: a case report]. *Vestn Otorinolaringol* 2018;83(3):69-70.
8. Dexemble P, Huth J, Rebufy M, Chabrol A. Carcinome adénoïde kystique du larynx. A propos de deux cas. *Ann Otolaryngol Chir Cervicofac* 2003;120:244-8.
9. Zvrko E, Golubović M. Laryngeal adenoid cystic carcinoma. *Acta Otorhinolaryngol Ital* 2009;29:279-82.
10. Testa D, Guerra G, Conzo G, Nunziata M, D'Errico G, Siano M, Ilardi G, Vitale M, Riccitiello F, Motta G. Glottic-Subglottic adenoid cystic carcinoma. A case report and review of the literature. *BMC Surg* 2013;13(Suppl 2):S48.
11. Mantsopoulos K, Psychogios G, Bohr C, Zenk J, Kapsreiter M, Waldfahner F, Iro H. Primary surgical treatment of T3 glottic carcinoma: Long-term results and decision-making aspects. *Laryngoscope* 2012;122:2723-7.
12. DelNegro A, Ichihara E, Tincani AJ, Altemani A, Martins AS. Laryngeal adenoid cystic carcinoma: Case report. *Sao Paulo Med J* 2007;125:295-6.
13. Ganly I, Patel SG, Coleman M, Ghossein R, Carlson D, Shah JP. Malignant minor salivary gland tumors of the larynx. *Arch Otolaryngol Head Neck Surg* 2006;132:767-70.

How to cite this article: Venkatesh V, Thaj RR. A case report of adenoid cystic carcinoma of larynx: A distinctly rare entity. *Indian J Pathol Oncol* 2019;6(2):328-30.