

# Optical coherence tomography analysis of macula in diabetic patients undergoing cataract surgery

Anitha J<sup>1</sup>, N. Sindhu Khanna<sup>2,\*</sup>

<sup>1</sup>Assistant Professor, <sup>2</sup>Senior Resident, Dept. of Ophthalmology, Sapthagiri Institute of Medical Sciences and Research Center, Bangalore, Karnataka, India

**\*Corresponding Author: Sindhu Khanna**

Email: [khanna\\_sindhu@yahoo.com](mailto:khanna_sindhu@yahoo.com)

## Abstract

Optical coherence tomography analysis of macula in diabetic patients undergoing cataract surgery.

**Aim:** Optical coherence tomography analysis of macula in diabetic patients undergoing cataract surgery.

**Materials and Methods:** To compare the foveal thickness in diabetics before and after cataract surgery using optical coherence tomography. Diabetes subjects undergoing cataract surgery with various grades of retinopathy were included. Excluding those with preexisting macular edema, previous intraocular surgeries, causes of macular edema other than diabetes, anti-glaucoma medication and dense cataract.

**Results:** While the overall outcome of cataract surgery is excellent, patients with diabetes may have poor visual outcome than non-diabetics. Macular edema is the leading cause of poor visual outcome after cataract surgery.

**Conclusion:** In the present study we have noted that in diabetics macular thickness increases after cataract surgery. The worsening of macular edema is more prominent in eyes with diabetic retinopathy than in eyes without diabetic retinopathy.

**Keywords:** Cataract, Diabetes, Macular edema, OCT.

Cataract is one of the common complications of Diabetes mellitus. Classic diabetic snowflake cataract in young subjects is rare. The vast majority of lens opacities in adult diabetics are nuclear sclerotic in type, but they do progress more rapidly and become symptomatic at a younger age than in non-diabetics. Longstanding diabetics have many times the risk of visually significant cataract and of undergoing cataract surgery as do non-diabetics of comparable age. Cataract surgery in diabetics is more problematic than nondiabetics.<sup>1,2</sup>

Macular edema (ME) leads to poor visual outcome in diabetes subjects who undergo cataract surgery.<sup>3,4</sup> Fundus fluorescein angiography (FFA), slit lamp biomicroscopy and stereoscopic photography are insensitive to small changes in macular thickness.<sup>5</sup> These are best for qualitative assay of macula.

Optical coherence tomography (OCT) is an advanced method and has high resolution. It gives cross sectional analysis of different layers of retina based on their relative reflectivity. OCT is sensitive in assessing diabetic macular edema. It directly measures the macular thickness and documents any changes in thickness.

Central macular thickness in OCT is shown to correlate better with visual acuity than the presence of leakage on FA.<sup>6</sup>

With OCT clinicians can reliably detect and measure small changes in macular thickness. It is also useful in quantitatively assessing the efficacy of different treatment modalities.<sup>7</sup> OCT is highly reproducible in measuring macular thickness.<sup>8</sup>

Although widely recognized, the true incidence of macular edema after cataract surgery has not been clearly defined in literature. Thus this study was undertaken to

assess the incidence and progression of macular edema in diabetic subjects after cataract surgery using OCT.

## Aims and Objectives

### Aim

Optical coherence tomography analysis of macula in diabetic subjects undergoing cataract surgery.

### Objectives

To compare the foveal thickness changes in diabetics before and after cataract surgery.

### Inclusion and Exclusion Criteria

Diabetic subjects with senile immature cataract with various grades of retinopathy undergoing cataract surgery were included.

### Exclusion Criteria

1. Eyes with preexisting macular disease.
2. Diabetic subjects with prior intraocular surgery of any type.
3. Eyes with macular edema of other etiologies which could affect macular thickness like uveitis, choroidal retinal disease, age related macular degeneration.
4. Antiglaucoma medication like acetazolamide which can affect the foveal thickness.
5. Subjects with very dense cataract, which can limit the OCT evaluation of foveal thickness.

## Results

A total of 50 eyes of diabetic subjects were enrolled preoperatively. They underwent cataract surgery with posterior chamber intraocular lens implantation. Consequently, 50 study eyes of 50 study subjects completed follow ups on post-operative day 7 (100%), day 30 (100% completion), and day 90 (100% completion).

Study participants were grouped for comparison purposes by grades of diabetic retinopathy that is no diabetic retinopathy, mild non proliferative diabetic retinopathy (NPDR), moderate NPDR, severe NPDR. The mean change in foveal thickness from preoperative baseline was measured at postoperative day 7, 30, 90 and analyzed among comparative groups. Best corrected visual acuity (BCVA) was measured preoperatively and on postoperative day 7, 30, 90.

The mean age of subjects in our study is  $60.19 \pm 5.44$  years. Among 50 subjects in the study sample 27 subjects (54%) were male and 23 subjects (46%) were females.

Out of 50 subjects, 14 (28%) had no Diabetic retinopathy, 19 (38%) had mild NPDR, 14 (28%) had moderate NPDR and 3 (6%) had severe NPDR. Preoperative mean foveal thickness in subjects with No DR was  $214.29 \mu\text{m}$ , in mild NPDR subjects was  $217 \mu\text{m}$ , in moderate NPDR subjects was  $233.79 \mu\text{m}$  and in severe NPDR group was  $239 \mu\text{m}$ .

Among 50 eyes studied, mean foveal thickness (in micrometers) has increased from preoperative baseline of  $222.26$  to  $249.74$  at post-operative day 7, increased to  $253.4$  on postoperative day 30 and has come down to  $238.78$  on day 90. (Fig. 1)

Mean change in foveal thickness postoperatively from preoperative baseline in No DR group was  $23.71 \mu\text{m}$  at day 7,  $23.64 \mu\text{m}$  at day 30 and  $8.36 \mu\text{m}$  at day 90.

In mild NPDR group it was  $24.11 \mu\text{m}$  at day 7,  $27.21 \mu\text{m}$  at day 30 and  $14.89 \mu\text{m}$  at day 90.

In moderate NPDR group it was  $33.14 \mu\text{m}$  at day 7,  $34.64 \mu\text{m}$  at day 30 and  $16 \mu\text{m}$  at day 90.

In severe NPDR group it was  $40 \mu\text{m}$  at day 7,  $74.67 \mu\text{m}$  at day 30 and  $67.33 \mu\text{m}$  at day 90. (Table 1)

Mean Preoperative Best corrected visual acuity (BCVA) in logMAR among 50 subjects was  $0.92$  (Fig. 2)

In No DR group it was  $0.83$ , in mild NPDR group it was  $0.93$ , in moderate NPDR group it was  $0.97$  and in severe NPDR group it was  $1.13$ .

Mean BCVA in logMAR has improved from preoperative value of  $0.926$  to  $0.258$  on day 7, to  $0.19$  on day 30 and to  $0.148$  on day 90 among 50 subjects. (Table 2)

BCVA in No DR group was  $0.16$  at day 7,  $0.07$  at day 30 and  $0.12$  at day 90.

In mild NPDR group it was  $0.24$  at day 7,  $0.15$  at day 30 and  $0.16$  at day 90.

In moderate NPDR group it was  $0.32$  at day 7,  $0.28$  at day 30 and  $0.15$  at day 90.

In severe NPDR group it was  $0.53$  at day 7,  $0.57$  at day 30 and  $0.17$  at day 90. (Table 3)

Among our study population 1 subject (2%) developed macular edema (increase in  $> 30\%$  foveal thickness from preoperative baseline) at day 7.

12 subjects (24%) developed macular edema on day 30 and 4 subjects (8%) had macular edema on day 90.

Among 50 subjects, 38 subjects who did not develop macular edema had an increase in mean foveal thickness from preoperative baseline of  $220.95 \mu\text{m}$  to  $242.68 \mu\text{m}$  on day 7,  $238.39 \mu\text{m}$  on day 30 and  $228.74 \mu\text{m}$  on day 90.

12 subjects who developed macular edema on day 30 had increase in mean foveal thickness from preoperative baseline of  $226.42 \mu\text{m}$  to  $272.08 \mu\text{m}$  on day 7,  $300.92 \mu\text{m}$  on day 30 and  $270.58 \mu\text{m}$  on day 90 which was statistically significant ( $p < 0.001$ ).

Mean change in foveal thickness from preoperative baseline in the group who developed macular edema on day 30 was  $45.67 \mu\text{m}$  on day 7,  $74.5 \mu\text{m}$  on day 30 and  $44.17 \mu\text{m}$  on day 90 which was statistically significant ( $p < 0.001$ ).

In the group who did not develop macular edema had an increase of  $21.74 \mu\text{m}$  on day 7,  $17.45 \mu\text{m}$  on day 30 and  $7.79 \mu\text{m}$  on day 90.

BCVA in macular edema group (12 subjects) was  $1.08$  on preoperatively,  $0.40$  on postoperative day 7,  $0.47$  on day 30 and  $0.17$  on day 90.

BCVA in the group who did not develop macular edema was  $0.88$  preoperatively.  $0.21$  On postoperative day 7,  $0.10$  on day 30 and  $0.14$  on day 90.

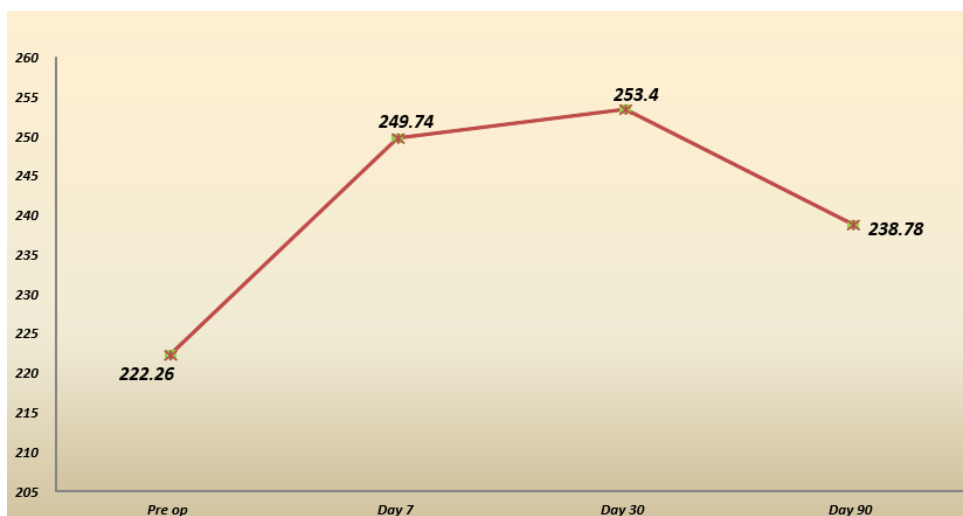
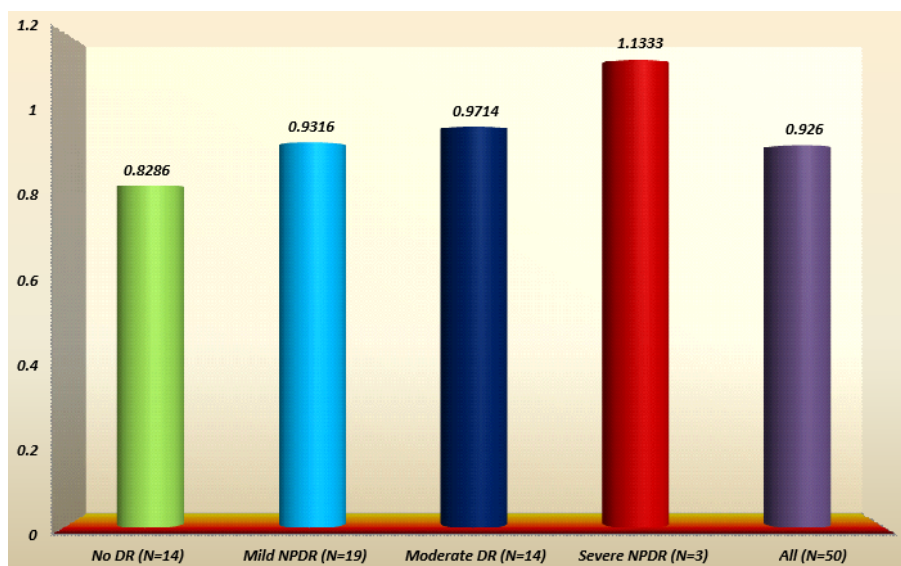


Fig. 1: Comparison of mean foveal thickness (micrometer) in study groups at different time

**Table 1: Mean change in the foveal thickness (micrometer) in study group according to grades of retinopathy**

Visit		N	Mean	SD	Min	Max	F value	P value
Day 7	No DR	14	23.71	17.171	-2	57	1.408	0.252
	Mild NPDR	19	24.11	18.968	3	65		
	Moderate NPDR	14	33.14	16.792	-8	53		
	Severe NPDR	3	40	16.643	28	59		
Day 30	No DR	14	23.64	17.283	9	72	3.499	0.023
	Mild NPDR	19	27.21	25.864	2	94		
	Moderate NPDR	14	34.64	33.353	-10	73		
	Severe NPDR	3	74.67	2.517	72	77		
Day 90	No DR	14	8.36	6.594	0	20	7.524	<0.001
	Mild NPDR	19	14.89	20.42	-6	87		
	Moderate NPDR	14	16	25.537	-15	71		
	Severe NPDR	3	67.33	24.987	40	89		



**Fig. 2: Mean pre-operative best corrected visual acuity (logMAR) according to grades of retinopathy**

**Table 2: Comparison of mean best corrected visual acuity (logMAR) in study group at different time (n= 50)**

Visit	Mean	SD	Min	Max	T value	P value
Pre-op	0.9260	0.17357	0.50	1.20	3.079	0.086
Day 7	0.2580	0.14010	0.00	0.60	0.075	0.785
Day 30	0.1900	0.20429	0.00	0.80	0.055	0.815
Day 90	0.1480	0.19298	0.00	0.80	0.330	0.569

**Table 3: Comparison of mean best corrected visual acuity (logMAR) in study group at different time points according to grades of retinopathy**

Visit		N	Mean	SD	Min.	Max.	'F' value	'p' value
Day 7	No DR	14	.1571	.10894	.00	.30	12.448	<0.001
	Mild NPDR	19	.2421	.11213	.00	.60		
	Moderate DR	14	.3214	.10509	.20	.50		
	Severe NPDR	3	.5333	.05774	.50	.60		
Day 30	No DR	14	.0714	.09945	.00	.20	9.046	<0.001
	Mild NPDR	19	.1526	.19824	.00	.80		
	Moderate DR	14	.2786	.18472	.00	.60		
	Severe NPDR	3	.5667	.05774	.50	.60		
Day 90	No DR	14	.1214	.20069	.00	.60	0.130	0.942
	Mild NPDR	19	.1632	.20333	.00	.80		
	Moderate DR	14	.1500	.19513	.00	.60		
	Severe NPDR	3	.1667	.15275	.00	.30		

## Discussion

Cataract is a major cause of visual impairment in diabetes subjects. The incidence and progression of cataract is high in subjects with diabetes mellitus. Studies emphasize early cataract extraction in diabetics. Cataract surgery has to be done before the lens opacity hinders detailed fundus examination.

Compared to non-diabetics, diabetes subjects may have poorer visual outcome. Macular edema is the important cause of this poor visual outcome after cataract surgery. In diabetics blood aqueous barrier is functionally impaired which leads to increased postoperative inflammation which in turn leads to sight threatening macular edema, aggravated by cataract surgery.<sup>9</sup>

The study was intended for analyzing the macular changes associated with cataract surgery in diabetics by using OCT.

The study included 50 diabetic subjects with visually significant cataract. The normative data of mean foveal thickness was high in diabetics with DR compared to those without DR. Also increase in mean foveal thickness correlated with severity of diabetic retinopathy. In diabetics after cataract surgery on post-operative day 7 and 30 there was increase in mean foveal thickness from preoperative baseline but has decreased on day 90.

In our study we found worsening of diabetic macular edema after cataract surgery, and the worsening is more pronounced in eyes with DR.<sup>10</sup> Cytokines including prostaglandins (PG) or vascular endothelial growth factor (VEGF), released from blood-ocular barrier after cataract extraction is thought to cause pseudophakic cystoid macular edema. Breakdown of the blood-ocular barrier in diabetic eyes, particularly in eyes with DR, is known to be greater than that in non-diabetic eyes.<sup>11</sup>

In our study one subject who underwent cataract surgery had posterior capsular rent and minimal vitreous loss. PCIOL was placed in the sulcus after anterior vitrectomy. This subject had maximum increase in the foveal thickness from preoperative baseline on post op day 7, 30 and it remained high on post op day 90 also. This could be because blood-retinal barrier breakdown is more pronounced in cases of complications like posterior capsular tear and vitreous loss.

Mean Preoperative Best corrected visual acuity (BCVA) in log MAR also correlated with grades of diabetic retinopathy. This cannot be relied upon because level of cataract is a confounding factor.

There was progressive improvement in Mean BCVA from pre-operative baseline on day 7, 30 and 90.

Mean BCVA correlated with Mean foveal thickness values on day 30 and day 90 but did not correlate on day 7, probably because of the presence of anterior segment inflammation, corneal striae and corneal astigmatism which was not stabilized on day 7, all of which decreased during further follow up visits.

A study reported that in diabetic retinopathy subjects, single measurements of foveal thickness by OCT correlates

well with BCVA and is a successful means of monitoring the macular edema.<sup>12</sup>

In a similar study it was found that there was a significant correlation between BCVA, foveal thickness and level of retinopathy.<sup>13</sup>

In our study ME is defined by changes in foveal thickness, as detected by OCT. We found that subjects with > 30% increase in foveal thickness showed spongy edematous abnormalities on OCT and experienced significant visual loss. Moreover, 30% cut off was high enough to prevent any overlap with the 10% coefficient of variation reported for repeat OCT testing. Therefore, for our study purposes we considered > 30% increase of foveal thickness as a significant cut-off to define ME.

A similar study<sup>14</sup> also defined ME as increase in foveal thickness of > 30% from preoperative baseline.

Among our study population 1 subject (2%) developed macular edema on day 7, 12 subjects (24%) developed macular edema on day 30 and 4 subjects (8%) had macular edema on day 90.

At day 7 one subject had macular edema which persisted on day 30 but decreased on day 90.

At day 30, 11 subjects (22%) who did not have macular edema on day 7 developed macular edema and 1 subject (2%) who had ME on day 7 continued to have ME on day 30. Therefore incidence of macular edema on day 30 was 24%.

Out of these 12 subjects who had ME on day 30, only 3 subjects (6%) continued to have macular edema on day 90, in the remaining subjects macular edema decreased. 1 subject (2%) who did not have macular edema on day 7 and 30 had developed macular edema on day 90. So the incidence of ME on day 90 was 8%.

In a study by Stephen J. Kim<sup>13</sup> et al, reported that there was 22% incidence of macular edema at 1 month post-op and in a similar study by Soon Il Kwon,<sup>14</sup> et al there was 18% incidence of ME at 1 month post-op.

In the present study frequency of occurrence of macular edema increased with severity of DR. This requires further evaluation as the sample size of severe NPDR was very less in our study.

Mean change in the foveal thickness in the subject group who developed macular edema on day 30 remained high on all post-op visits compared to the group who did not develop macular edema which was significant ( $p < 0.001$ ). This correlated with corresponding decrease in BCVA.

Out of 50 subjects 12 subjects developed macular edema. Majority of the subjects (>90%) without diabetic retinopathy changes preoperatively have a good visual prognosis with 20/40 or better visual acuity. One third of preexisting diabetic retinopathy subjects show progression of retinopathy. Although postoperative macular edema is more common in diabetics, it is found to resolve spontaneously in subjects with no or mild NPDR. Clinically significant ME tends to persist or may arise de-novo, or even worsen after cataract surgery in cases with moderate or severe NPDR. A thorough preoperative evaluation of their retinopathy status is mandatory in these subjects. The need

for cataract surgery, their retinopathy status and the risk of progression should be well discussed with the subjects and their relatives. It is not advisable to wait for the cataract to become denser as early surgery before the development of diabetic retinopathy will have better visual prognosis. Preoperatively diabetic retinopathy should be stabilized with appropriate treatment. Regular post-operative follow up is a must to prevent complications from diabetic retinopathy and maculopathy.<sup>15</sup>

We acknowledge some limitations to our study:

1. The number of eyes with severe NPDR was small.
2. We didn't have control group to compare with.

## Conclusion

In the present study we have noted that in diabetes subjects macular thickening increases after cataract surgery. The worsening of macular edema is more prominent in eyes with diabetic retinopathy than in eyes without diabetic retinopathy.

**Conflict of Interest:** None.

## References

1. Klein BEK, Klein R, Moss SE. Incidence of cataract surgery in the wilconsin epidemiologic study of diabetic retinopathy. *Am J Ophthalmol* 1995;119: 295-300.
2. Klein R, Klein BEK, Moss SE. Visual impairment in diabetes. *Ophthalmol* 1984;91:1-9.
3. Nelson ML, Martidis A. Managing cystoid macular edema after cataract surgery. *Curr Opin Ophthalmol* 2003;14:39.
4. Bhagat N, Grigorian RA, Tutela A, Zarbin MA. Diabetic Macular Edema: Pathogenesis and Treatment. *Surv Ophthalmol* 2009;54(1):1-32.
5. D. Huang, E.A. Swanson and C.P. Lin. Optical coherence tomography. *Sci* 991:1178–1181. Cited By in Scopus (2918)
6. Voo I, Mavrofrides EC, Puliafito CA. Clinical applications of optical coherence tomography for the diagnosis and management of macular diseases. *Ophthalmol Clin North Am* 2004;17(1):21-31.
7. Puliafito CA, Hee MR, Lin CP. Imaging of macular diseases with optical coherence tomography. *Ophthalmol* 1995;102:217–29.
8. Hee MR, Izatt JA, Swanson EA, et al. Optical coherence tomography of the human retina. *Arch Ophthalmol* 1995;113:325-32.
9. Pollreis A, Schmidt-Erfurth U. Diabetic Cataract—Pathogenesis, Epidemiology and Treatment. *J Ophthalmol* 2010:1-8.
10. Zaczek A, Zetterstrom C. Aqueous flare intensity after phacoemulsification in subjects with diabetes mellitus. *J Cataract Refract Surg* 1998;24:1099–1104.
11. Oshika T, Kato S, Funatsu H. Quantitative assessment of aqueous flare intensity in diabetes. *Graefes Arch Clin Exp Ophthalmol* 1989;27:518–20.
12. Akuraya H, Kangave D, Abu El-Asrar AM. The correlation between optical coherence tomographic features and severity of retinopathy, macular thickness and visual acuity in Diabetic macular edema. *Int Ophthalmol* 2005;26(3):93-9.
13. Stephen J. Kim, Robert Equi, Neil M. Bressler. Analysis of Macular Edema after Cataract Surgery in Subjects with Diabetes Using Optical Coherence Tomography. *Ophthalmol* 2007;114:881–9.
14. Kwon SI, Hwang DJ, Seo JY, Park IW. Evaluation of Changes of Macular Thickness in Diabetic Retinopathy after Cataract Surgery. *Korean J Ophthalmol* 2011;25(4):238-42.
15. Gupta A, Gupta V. Diabetic maculopathy and cataract surgery. *Ophthalmol Clin North Am* 2001;14(4):625-37.

**How to cite this article:** Anitha J, Khanna NS. Optical coherence tomography analysis of macula in diabetic patients undergoing cataract surgery. *Indian J Clin Exp Ophthalmol* 2019;5(2):164-8.