

Phacoemulsification in uveitic cataract at a tertiary care teaching center

Rimsha Thaseen^{1*}, Anuj², Rahul Sahay³, Shilpa Goyal⁴, Rahul Bhargava⁵

^{1,2}Junior Resident, ³Resident, ⁴Retina Consultant, ⁵HOD, Dept. of Ophthalmology, ^{1,3}Santosh Medical College, Ghaziabad, Uttar Pradesh, ⁴Guru Ka Langer Eye Hospital, Chandigarh, ⁵Rama Medical College, Ghaziabad, Uttar Pradesh, India

*Corresponding Author: Rimsha Thaseen

Email: drsheikhrimsha@gmail.com

Abstract

Introduction: Due to variation in etiology and presentation, it is difficult to predict the outcomes of phacoemulsification in patients suffering from uveitis. The present study evaluated outcomes of surgery at a tertiary care teaching hospital.

Materials and Methods: 64 eyes of 64 patients with uveitis were retrospectively studied for vision related outcome and complication rate after phacoemulsification surgery. However, after exclusion, 46 eyes were analysed.

Results: The mean age of patients with uveitis enrolled was 46.7±2.3 (range, 28-56 years). The mean duration of follow-up was 12.6±3.4 (range, 8-16 months). Improvement in vision was significantly better in males (P=0.05). Uveitis was silent for 6.3±2.6 months prior to performing surgery. Tuberculosis was the most commonly identified etiological factor followed by Fuch's iridocyclitis and Vogt's Koyanagi Harada disease, respectively. The frequent complications of surgery were recurrent uveitis, cystoid macular edema and after-cataract. Factors influencing vision were location of uveitis, intake of preoperative steroids and posterior segment pathology. At final follow-up, the vision was 0.24±0.07 Log MAR units.

Conclusion: Thorough control of inflammation prior to performing surgery is the key to good visual outcome in uveitis. Phacoemulsification with posterior chamber IOL implantation provided good vision when the inflammation is confined to the anterior segment of the eye. Visual prognosis compromise in diseases involving the central fundus.

Keywords: Cataract, Cystoid macular oedema, Intraocular lens implantation, Posterior capsule opacification, Uveitis, Vision.

Introduction

In uveitis, up to 50% patients may develop cataract during natural course of disease. Cataract developing as a complication of uveitis differs from age-related cataract in terms of etiology, presentation and prognosis. In uveitis, development of cataract is consequent to longstanding inflammation and to corticosteroids, which are often prescribed as a treatment option to control intraocular inflammation.¹ Uveitic cataract is often associated with secondary conditions like band shaped keratopathy and corneal deposits, which decrease visibility while performing surgery; inadequate pupillary dilatation due to presence of synechia, bleeding from new vessels in anterior chamber angle, presence of pupillary membranes, and zonular weakness may make the surgical procedure more challenging. Last, secondary manoeuvres like using pupil expanders or iris retraction devices and peeling of membranes may be necessary in some cases.²

Thus, it would not be an understatement to say that cataract surgery in uveitis differs significantly from conventional cataract surgery for senile cataract. Under these circumstances, the optimal surgery technique may differ from one surgeon to another depending on technique, equipment and surgical skill. Having said this, each patient with uveitis may respond differently to surgery. The probable reasons could be variation in etiology and pathologies in posterior segment. Moreover, in cases with total posterior synechia and black cataract, the surgical phaco-incision needs to be extended for manual removal of the nucleus.

Despite unpredictability in final vision after cataract surgery, most studies have reported that as compared to those without uveitis, cataract extraction may be associated increased inflammation post-operatively, macular edema and

posterior capsule opacification.³⁻⁴ Despite this, most surgeons believe that by carefully selecting patients, meticulous surgery and through control of inflammation before surgery, phacoemulsification followed by intraocular lens (IOL) implantation can be safely accomplished in patients with uveitis.⁵

In this study, we evaluated vision and complication rate of phacoemulsification surgery in patients suffering with uveitis at a tertiary care teaching hospital.

Materials and Methods

In this study, 64 eyes who had phacoemulsification with IOL implantation in patients suffering from uveitis between July 2015 and December 2017 were retrospectively analyzed. Random selection was done if both eyes were involved. All patients signed a written consent prior to surgery. The protocol of the research was approved by the institutional review board and the trial was approved by Ethics committee.

Inclusion Criteria

Cataract impairing vision and lenticular opacities impairing posterior segment visualization were considered eligible for surgery. Adequate pre-operative control of inflammation for minimum 3 months was considered pre-requisite for surgery. However, in cases with intermediate uveitis, disease activity in the vitreous may persist even when uveitis is in inactive stage.⁶

Exclusion Criteria

If follow-up was less than six months, macular edema was present, subluxated cataracts, diabetes and low endothelial cell counts, such patients were excluded from the study.

Preoperative Investigations

A battery of investigations was done including complete blood counts, erythrocyte sedimentation rate (ESR), blood sugar measurements, Mantoux test, and X-ray of chest, cervical spine and sacroiliac joints, respectively. Special investigations were advised whenever indicated like rheumatoid factor, angiotensin converting enzyme assay, anti-nuclear factor (ANF), human leucocyte antigen (HLA) typing and enzyme linked immunosorbant assay (ELISA) for TORCH agents, human immunodeficiency virus. Ultrasonography (B-scan) was performed in cases where visualization of retina was not possible due to black or mature cataract. Measurement of intraocular pressure was done by applanation tonometer. Grading of aqueous flare and cells was done by grading described by Hogan et al.⁷ Uveitis was classified as per standardization of uveitis nomenclature for reporting clinical data.⁸

Patient's data was collected. Variables included sex, age, uveitis etiology, baseline vision, duration of corticosteroid intake, frequency and duration of remission of uveitis prior to surgery, endothelial cell counts, follow-up (months) and complications.

Preoperative Medication

The regimen for pre-operative steroids was prednisolone, 1 mg/kg body weight for 7 days before surgery. These were continued after cataract surgery. The doses were tapered according to the inflammatory response over 3-6 weeks. They were prescribed in patients with history of macular oedema, recurrent uveitis, chronic anterior uveitis, and intermediate uveitis.

Technique of Phacoemulsification

The procedures were performed by one of the two experts in our teaching center. They were fellowship trained in phacoemulsification. Phacoemulsification was done as per the technique described previously.⁹ Five percent povidone-iodine solution was applied. A scleral tunnel incision (3mm) was made under local anaesthesia. The site of incision was superiorly. Two stab clear corneal incisions were made opposite to each other with 15 degree slit knife. Ocular viscosurgical device (OVD) was used to maintain AC. In case of non-dilating pupils, expanders were used. Trypan blue dye was used to better visualize anterior capsule. Anterior chamber entry was fashioned with a 2.8 mm keratome. Hydrodissection was done and nucleus was rotated within the bag. Emulsification was done using Visalis 500 (Carl Zeiss Meditech, Germany). The nucleus was thus fragmented and removed by stop-and chop method. Cortical material was removed by single-port canulae under AC maintainer. A hydrophobic acrylic lens was implanted in the capsular bag. Paracentesis was hydrated in the end. A subconjunctival injection of steroid and antibiotic was given at end of surgery.

Postoperative Medication

Topical Moxifloxacin 0.5% 6 times a day, 1% atropine 3 times a day and Prednisolone acetate 1% hourly was given to all patients. The dose of topical steroids was tapered over 6-8 weeks. Topical Nepafenac BD was given to patients with macular edema; in addition, these patients also received topical corticosteroids.

Follow-Up

Patients were followed up on first, third and seventh days after surgery. Thereafter, they were examined at weekly interval for two weeks. Later, every month for two months and at every three months after that. The schedule on these visits was to record of vision, examine the fundus with +90D lens. Aqueous flare and cells were graded by method described previously. All patients had OCT at one-month after. This was and repeated after three months. Those patients who took steroids prior to surgery, dose was gradually reduced as per reduction of inflammation. These patients also had measurement of blood sugar, blood pressure and urine testing.

Outcomes

The primary outcome of the study was improvement in corrected distance vision. Complication of surgery were the secondary outcome.

Statistics

SPSS software for windows (version 25) was used to carry out data analysis. For comparison, Snellen's acuity was converted into the log minimum angle of resolution (Log MAR) units. Preoperative and postoperative visual acuity was compared for statistical significance using the Mc Neymar's test. One-way analysis of variance was used when groups for comparison were more than two. When P-value less than 0.001, data was considered statistically significant.

Results

Eight patients did not come on the scheduled follow-up visits. Ten patients had to be excluded from the study as minimum follow-up period for inclusion was 6 months. Thus, the records of 46 patients was available for data analysis. The mean age of patients with uveitis enrolled in the study was 46.7 ± 2.3 (range, 28-56 years). The mean duration of follow-up was 12.6 ± 3.4 (range, 8-16 months). Improvement in vision was significantly better in males than females ($P=0.05$). Table 1 shows patients enrolled in the trial. Uveitis was silent for 6.3 ± 2.6 months prior to performing surgery.

Vision

Pre-operatively, the vision was 0.83 ± 0.46 . During follow up (day 7), the vision was 0.38 ± 0.08 . At final visit, the vision was 0.24 ± 0.07 . Pre-operative, 1 week PO and final vision is depicted in Fig. 1. The anatomical location of the disease influenced vision significantly (ANOVA, $P=0.046$). Patients with posterior segment uveitis had worse vision than those with anterior. The patients on oral preoperative steroids had a better vision as compared to those without. However, the final vision did not differ significantly between those who were on pre-operative steroids and those without oral steroids.

Table 1: Parameters

Description	
N, patients	64
Age (mean ± standard deviation), years	46.7±2.3
Gender	
Male	20
Female	28
Uveitis duration (months)	44±16
Follow up duration (months)	14.4±6.6
Etiology of uveitis	N (%)
Idiopathic	12(25)
Tubercular	12(25)
Fuch's Heterochromic iridocyclitis	8(16.66)
Vogt Koyanagi Harada Syndrome	4(8.33)
Ankylosing Spondylitis	4(8.33)
Multifocal choroiditis	2(4.1)
Toxoplasmosis	2(4.1)
Sarcoidosis	1(2)
Systemic lupus erythematosus	1(2)
Psoriasis	1(2)
Syphilis	1(2)

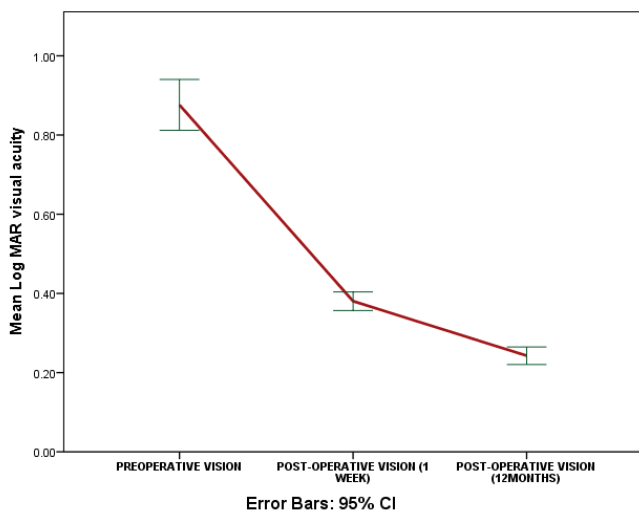


Fig. 1: Mean change in visual acuity

The cause of vision less than 6/60 Snellen were macular scar, cystoid macular edema, glaucoma, recurrence of uveitis in post-operative period, and posterior capsule opacification. Fig. 2 uveitic cataract and Figure 3, cystoid macular edema in a patient after surgery.

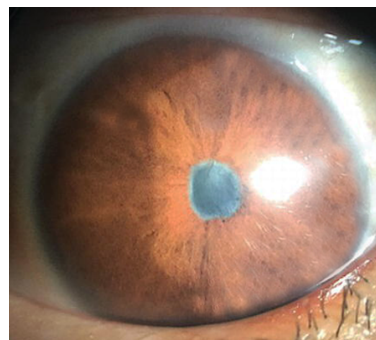


Fig. 2: Uveitic cataract in a patient

Intraocular Inflammation

Ten eyes (20.8%) had exaggerated post-operative inflammation. After corticosteroid therapy, 4(8.3%) had 2+ cells in anterior chamber at 4 weeks. Continuation of topical therapy for 6 weeks resulted in resolution of inflammation in two eyes. However, two eyes, had persistent vitreous haze at final follow up examination (P=0.04). Three eyes (6.25%) with exaggerated post-operative developed posterior capsule opacification (PCO) subsequently.

Complications

Posterior capsule rupture occurred in two eyes during surgery. After vitrectomy, a multi-piece IOL was implanted in these patients. Although none of the patients developed new-onset glaucoma, two patients who had medically controlled glaucoma prior to surgery developed rise in intraocular pressure after surgery. One of these has a sustained increase in IOP despite maximum tolerated topical therapy. This patient was referred to glaucoma specialist. Posterior capsule opacification occurred in three eyes after 2.6±1.4 months after surgery. Out of these, membranous type of PCO was seen in 2 eyes and fibrous type (Figure 3) in one eye. After 3 months of disease inactivity, Nd: YAG laser capsulotomy was offered to these patients. Macular edema (angiographically confirmed) was seen in 3 eyes (Figure 4) at the end of second post-operative month. In one eye, edema resolved with administration of topical nepafenac eye drops twice daily. However, in two eyes, CME was persistent at final follow-up examination.

Table 2: Causes of reduced vision after surgery

Complication	N	Percentage
Cystoid Macular Edema	3	6.25
Posterior Capsule Opacification	3	6.25
Recurrent Uveitis	4	8.3
Glaucoma	2	4.1
Macular Scar	2	4.1
Posterior Capsule rent	2	4.1

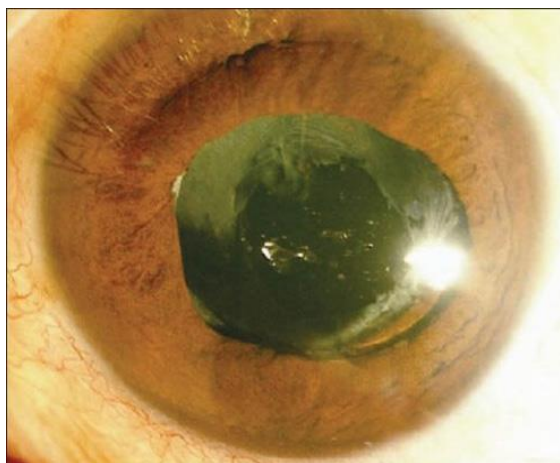

Fig. 3: Nd: YAG laser capsulotomy after cataract surgery in a patient with uveitis

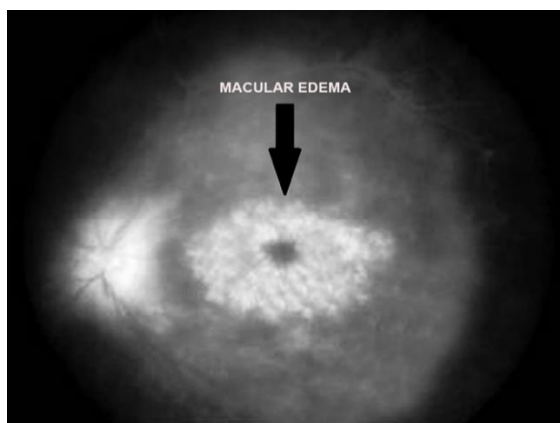


Fig. 4: Macular edema after surgery in a patient with uveitis

Discussion

Uveitis is a general term which refers to inflammation of the uveal tract due to numerous local and systemic conditions; thus, it has multifactorial etiology and causes a varying amount of inflammation in the eye. These conditions are commonly complicated with lenticular opacities over period. The cause and site of inflammation may be the critical factors which determine visual outcome in uveitis. This holds good for juvenile rheumatoid arthritis in which outcome of cataract surgery is poor due to exaggerated post-operative inflammation.¹⁰⁻¹¹ In this study, 93% patients had a good vision when the inflammation was confined to the anterior segment of eye. In contrast only 84% patients had improvement when uveitis was predominantly, posterior. In a prospective study by Okhravi et al in patients with uveitis, patients with anterior uveitis had a better visual at 6 months (96%) as compared to posterior (81%).¹²

Most authors believe that preoperative control of inflammation is the key to good outcome of surgery in patients suffering from uveitis. In our study preoperative steroids were prescribed to patients with intermediate uveitis, recurrent uveitis and those had macular oedema previously. However, Kosker et al obtained a vision of 20/40 or better in

94.5% eyes following phacoemulsification without administering preoperative but rather intravenous prednisolone (1mg/kg) during surgery. However, only patients with uveitis confined to anterior eye were evaluated in their study¹³ In contrast, Kang and Lee found that vision at 6 months was 20/40 or better in 64% and in a study by Foster et al, 87% eyes achieved this feat; at 25 months follow-up.¹⁴⁻¹⁵

Glaucoma is a commonly reported sequelae of cataract surgery with IOL implantation in eyes with uveitis. Kawaguchi et al reported raised IOP in 11(8.4%) eyes and Tejawani et al in 3(2.9%) of eyes.¹⁶⁻¹⁷ No new case of glaucoma was reported in the present study. Instead, patients with medically controlled glaucoma prior to surgery developed rise in IOP. All but one case was well controlled with topical medications.

Increased post-operative inflammation is a yet another sequela of cataract surgery in uveitic eyes. Estafanous et al¹⁸ found increased inflammation in 16(41%) eyes, and Krishnan et al¹⁹ in 19(53%) eyes. The rates were considerably higher as compared to our study. Judicious use of pre-operative steroids in our study could probably account for the difference in observations. One of the common causes of compromised vision after cataract surgery in uveitis is cystoid macular edema. Seamone et al²⁰ reported CME in of 12%, and Brinkman et al²¹ in 52% eyes at 12 and 13 months, respectively. Thorough control of inflammation prior to surgery and absence of any adverse events during surgery could probably explain the lower incidence (6.25%) of CME in our study.

In conclusion, complete control of inflammation prior to surgery is the key to good visual outcome in uveitis. Phacoemulsification with posterior chamber IOL implantation provided good vision when the inflammation is confined to the anterior segment of the eye. Visual prognosis compromise in diseases involving the central fundus.

Acknowledgements

We are thankful to www.indianmedicalstats.com for statistical analysis in this study.

Conflict of Interest: None.

References

1. Bhargava R, Kumar P, Bashir H, Sharma SK, Mishra A. Manual suture less small incision cataract surgery in patients with uveitic cataract. *Middle East Afr J Ophthalmol* 2014;21(1):77-82.
2. Bhargava R, Kumar P, Sharma SK, Kumar M, Kaur A. Phacoemulsification versus small incision cataract surgery in patients with uveitis. *Int J Ophthalmol* 2015;8(5):965-70.
3. Rauz S, Stavrou P, Murray PI. Evaluation of foldable intraocular lenses in patients with uveitis. *Ophthalmol* 2000;107(5):909-19.
4. Dana M R, Chatzistefanou K, Schaumberg D A. Posterior capsule opacification after cataract surgery in patients with uveitis. *Ophthalmol* 1997;104:1387-93.

5. Bhargava R, Kumar P, Sharma SK, Arora Y. Phacoemulsification Versus Manual Small Incision Cataract Surgery in Patients with Fuchs Heterochromic Iridocyclitis. *Asia Pac J Ophthalmol (Phila)* 2016;5(5):330-4.
6. Ganesh SK, Babu K, Biswas J. Phacoemulsification with intraocular lens implantation in cases of pars planitis. *J Cataract Refract Surg* 2004;30(10):2072-6.
7. Hogan MJ, Kimura SJ, Thygeson P. Signs and symptoms of uveitis. I. Anterior uveitis. *Am J Ophthalmol.* 1959;47(5 Pt 2):155-70.
8. Oliver GF, Stathis RM, Spurrier NJ, Smith JR. Use of Standardization of uveitis nomenclature for reporting clinical data at 10 Years. *Ophthalmol* 2017;124(7):1084-5.
9. Bhargava R, Sharma SK, Chandra M, Kumar P, Arora Y. Comparison of endothelial cell loss and complications between phacoemulsification and manual small incision cataract surgery (SICS) in uveitic cataract. *Nepal J Ophthalmol* 2015;7(14):124-34.
10. Matsuo T, Fujiwara M, Matsuo N. Inflammation after cataract extraction and intraocular lens implantation in patients with rheumatoid arthritis. *Br J Ophthalmol.* 1995;79(6):549-53.
11. Lobo AM, Papaliadis GN. Perioperative evaluation and management of cataract surgery in uveitis patients. *Int Ophthalmol Clin* 2010;50(1):129-37.
12. Okhravi N, Lightman SL, Towler HM. Assessment of visual outcome after cataract surgery in patients with uveitis. *Ophthalmol* 1999;106(4):710-22.
13. Kosker M, Sungur G, Celik T, Unlu N, Simsek S. Phacoemulsification with intraocular lens implantation in patients with anterior uveitis. *J Cataract Refract Surg* 2013;39(7):1002-7.
14. Kang YH, Lee JH. Phacoemulsification and posterior chamber intraocular lens implantation in uveitis. *Korean J Ophthalmol* 1997;11(2):94-7.
15. Foster CS, Rashid S. Management of coincident cataract and uveitis. *Curr Opin Ophthalmol* 2003;14(1):1-6.
16. Kawaguchi T, Mochizuki M, Miyata K, Miyata N. Phacoemulsification cataract extraction and intraocular lens implantation in patients with uveitis. *J Cataract Refract Surg* 2007;33(2):305-9.
17. Tejwani S, Murthy S, Sangwan V. Cataract extraction outcomes in patients with Fuchs' heterochromic cyclitis. *J Cataract Refract Surg* 2006;32:1678-82.
18. Estafanous MF, Lowder CY, Meisler DM, Chauhan R. Phacoemulsification cataract extraction and posterior chamber lens implantation in patients with uveitis. *Am J Ophthalmol* 2001;131(5):620-5.
19. Krishan R, Meisler DM, Lowder CY, Estafanous M. Long term follow-up of extracapsular cataract extraction and posterior chamber intraocular lens implantation in patients with uveitis. *Ophthalmol* 1998; 105:1765-1769.
20. Seamone CD, Deschênes J, Jackson WB. Cataract extraction in uveitis: comparison of aphakia and posterior chamber lens implantation. *Can J Ophthalmol* 1992;27(3):120-4.
21. Brinkman CJJ, Los GJ, Breebart AC. Cataract extraction in patients with chronic posterior uveitis. *Acta Ophthalmol* 1990;68:151-4.

How to cite this article: Thaseen R, Anuj, Sahay R, Goyal S, Bhargava R. Phacoemulsification in uveitic cataract at a tertiary care teaching center. *Indian J Clin Exp Ophthalmol* 2019;5(2):241-5.