

Ophthalmomyiasis externa: A case report

Rahul Raghunath Borade^{1*}, Nilakshi S. Pradhan², Pravin M. Bhat³

¹PG Resident, ²Principal and HOD, ³Associate Professor, Dept. of Shalakyatantra, Sane Guruji Hospital, Pune, Maharashtra, India

*Corresponding Author: Rahul Raghunath Borade

Email: boraderahul@gmail.com

Abstract

Purpose: To report an unusual case of ophthalmomyiasis in a healthy individual from western part of India.

Materials and Methods: A 23 years old patient with complaints of redness, severe burning sensation, foreign body sensation and excessive lacrimation in his right eye was examined and diagnosed with ophthalmomyiasis caused by larvae of *Oestrus ovis*. The patient was successfully treated with combination of Antibiotic and Steroid through topical route.

Results: A 23 years patient with presence of larvae was immediately examined and larvae's were removed and sent for identification. The organisms were found to be *Oestrus ovis*, the patient was treated with topical Tobramycin 0.3% combined with fluorometholone 0.1%. The complaints resolved completely with no ocular or systemic associations on further investigations.

Conclusion: This is one of the uncommon condition in urban areas. The most common organism causing ophthalmomyiasis is *Oestrus ovis*. *Oestrus ovis* is found in sheep and goat, humans are the accidental hosts and treatment should be aimed to immobilize and removal with secondary treatment of symptoms.

Keywords: Larvae, *Oestrus ovis*, Ophthalmomyiasis externa.

Introduction

Ophthalmomyiasis is a rare ocular disorder caused by infestation of ocular tissue by larvae of flies of the Dipterian orthopoda.¹ Larvae mainly invades in preexisting traumatic or neoplastic ulcerated or necrotic wounds. Necrotic and decomposed tissue attracts flies. Mechanical removal and oral Ivermectin are effective mode of treatment.²

Case Report

A 23 years old male patient was brought to the outpatient department of Sane Guruji Arogya Kendra, Sumatibhai Shah Ayurved College, Hadapsar, Pune on 13th August 2018. He complained of symptoms like pain, foreign body sensation, swelling, burning also excessive watering from his right eye. He gave history of two days back being hit by a fly in his right eye while riding on vehicle, he also mentioned the fly was removed subsequently. There was no significant history of ocular problems later that day so none of the medications was taken, but things started worsening the very next day with above mentioned symptoms.

On examination his visual acuity was 20/20 in both the eyes. Eyelids of the right eye were mildly oedematous. Conjunctiva on lateral side of the affected eye was congested followed by lacrimation. There was no pre-auricular lymphadenopathy noted. Extra ocular movements of both eyes were normal. Pupillary reaction of both eyes were normal. The most important finding from slit-lamp examination revealed was, presence of white tiny larvae like organisms crawling over the conjunctiva, 02 small 1-2mm long organisms were spotted in the lower fornix and similar in upper fornix. The organisms were freely motile and actively avoiding the light of the slit-lamp. These organisms moved freely over the palpebral conjunctiva and were seen darting in the forniceal spaces, so a need for emergency removal aroused. After topical use of anaesthetic

eye drops of proparacaine 0.5% two of the spotted organisms were removed with the help of fine plane forceps and also a bag like membrane was removed from lower fornix and further removal of other two organisms in the upper forniceal area. The organisms were placed in normal saline and sent to laboratory for identification, which were further mounted and photographed.

Fundus examination of the patient was done by Direct as well as indirect ophthalmoscopy which didn't reveal presence of intraocular organisms. Topical antibiotics and steroid drops combination of Tobramycin 0.3% with fluorometholone 0.1% was prescribed. A followup was taken the consecutive day and found negative, which revealed that treatment responded well. Diagnosis was made on the basis of identification of organisms, which were found to be *Oestrus ovis*.

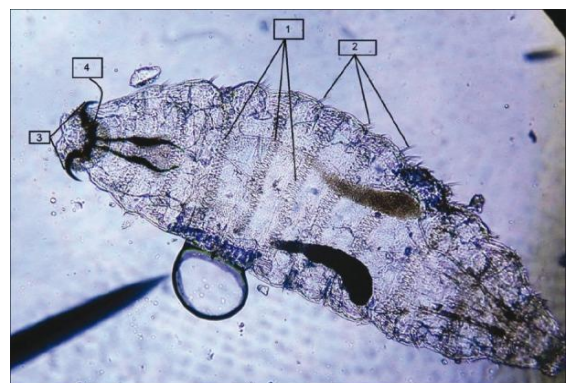


Fig. 1

Oestrus ovis larvae showing 1) Segments with intersegmental spine bands, 2) Tufts of brown hooks on the margins of each body segment, 3) Oral hooks, and 4) Oral hooks seen attached to the internal cephalopharyngeal skeleton.

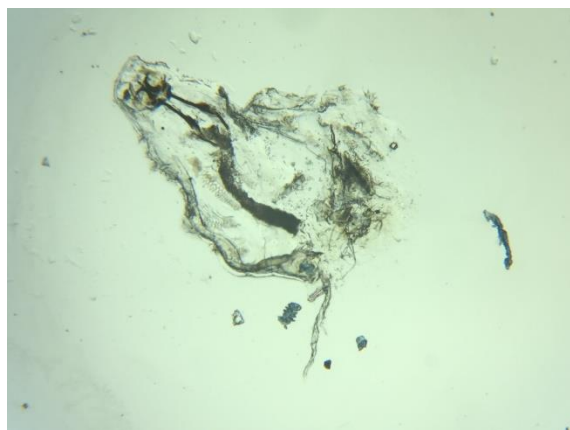


Fig. 2

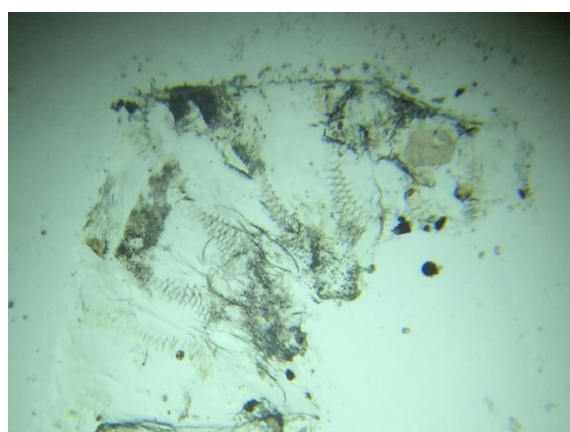


Fig. 3

Microscopic image of Larvae separated from patients eye, confirming identity as *O. Ovis* from the above images.

Discussion

Ophthalmomyiasis, which is infestation of the insect larvae in the eye, is known to occur in parts of Asia.¹ Humans are accidental hosts. Based on cases reported human myiasis is categorised clinically into six types i.e, dermal and sub-dermal, facial cavity, wound (trauma), Gastrointestinal, vaginal and generalised Myiasis. Causative organisms are three dipetran families including Oesteridae, Calliphoridae and Sarcophagidae.²

In this case, the organism was identified as *Oestrus ovis* larvae, it is most commonly affecting organism in cases of Human Myiasis reported till date.³ *O. Ovis* larvae is a sheep nasal botfly which becomes yellowish gray fly in size of 10-12 mm long. *O. ovis* has capability of hosting immediately after birth. The life cycle of *O. Ovis* larvae starts from laying of eggs by adult female botfly around nostrils of sheep and goats, eggs hatch and larvae migrates into sinuses. There larvae grows and after several weeks passes out from host and pupate on ground. Adult flies pupate from

larvae and their lifespan ranges upto one month and so on cycle continues.

Basically ophthalmomyiasis is of three types,

1. External type in which the infestation is externally on the ocular surface.
2. In Internal type of ophthalmomyiasis the larvae are seen deep into eyeball or sometimes the larvae can be seen within the subretinal spaces or the vitreous cavity.
3. Orbital Myiasis is more of complicated type, wherein the larvae darts deep into the orbit and damage the surrounding tissues.⁴

Our case was of external type of ophthalmomyiasis which was presented with marked conjunctival congestion and rest of ocular parts were found to be normal including anterior segment as well as the posterior segment excluding the other two types of ophthalmomyiasis Internal and Orbital which are destructive. Ophthalmomyiasis is generally misdiagnosed in ophthalmic patients presenting with complaint of unilateral redness and most of them come from areas near sheep or goat farms. So thorough workup is very important and also examining the patient with every possible aspect to come to a proper diagnosis. The condition is easily treatable, but if delay occurs in removal of the causative organism (larvae) it may lead to deep invasion into the eye or orbit, causing severe damage to the eye and other tissues.⁵ Our patient was middle aged which made him more immune to the risk of penetration of larvae and also devoid of any systemic diseases which may have prevented further penetration of larvae deep inside the eye or to the orbital cavity. The treatment responded well as planned and patient got remarkable relief in the symptoms the very next day after removal of the larvae and topical application of antibiotics and steroid combination eye drops therapy.

References

1. Maurya RP, Mishra D, Bhushan P, Singh V P and Singh M K (2012) Orbital Myiasis: Due to Invasion of Larvae of Flesh Fly (*Wohlfahrtia Magnifica*) in young child: rare presentation. *Case Rep Ophthalmol Med* 2012, doi:10.1155/2012/371498.
2. Maurya R P, Yadav I, Singh VP, Bhushan P. Orbital Myiasis (*Dermatobia Hominis*) Complicating secondary squamous cell carcinoma of medial rectus muscle. *J Clin Exp Ophthalmol* 2015;6:404. doi:10.4172/2155-9570.1000404
3. White GB. Manson's Tropical Diseases. 20th ed. New Delhi: Harcourt; 1996. Myiasis; pp. 1526–32.
4. Zumpt F. Ophthalmomyiasis in man, with special reference to the situation in Southern Africa. *S Afr Med J* 1963;37:425-8.
5. Dunbar J, Cooper B, Hodgetts T, Yskandar H. An outbreak of human external ophthalmomyiasis due to *Oestrus ovis* in southern Afghanistan. *Clin Infect Dis* 2008;46(11):e124–6.

How to cite this article: Borade RR, Pradhan NS, Bhat PM. Ophthalmomyiasis externa: A case report. *Indian J Clin Exp Ophthalmol* 2019;5(2):260-1.