

A study of histo-morphological changes of preputial skin

Kavya. S¹, Volga Harikrishnan^{2*}, Chitra Srinivasan³

¹IIIrd Year Student, ²Associate Professor, ³Professor, ¹⁻³Dept. of Pathology, Saveetha Medical College and Hospital, Saveetha nagar, Kuthambakkam, Thandalam, Chennai, India

*Corresponding Author: Volga Harikrishnan

Email: drhsvol@gmail.com

Abstract

Introduction: Prepuce is the skin covering the glans penis. The normal histological appearance of the prepuce shows a keratinized stratified squamous epithelium with ridged appearance and is rich in nerves, Schwann cells, Meissner's corpuscles, lymphoid cells, and capillaries. While the prepuce is more commonly perceived as a vestigial organ, several studies exist to demonstrate its importance in keeping the glans penis warm and protecting it in utero. The various lesions existing in the prepuce range from infectious to non-infectious (inflammatory, neoplastic, etc.). This study aims to observe the wide spectrum of lesions affecting the prepuce.

Materials and Methods: A Retrospective cross-sectional analysis of preputial skin sent for analysis over a period of 10 months to the department of Pathology was done. Review of the histopathological findings, clinical findings, age, and clinical presentations was done

Results: In this study, there is an increased incidence of chronic balanoposthitis in the study population. Preputial abnormalities were found to be more common in patients between 21 to 30 years of age. The most common clinical presentation observed in the patients is phimosis

Conclusion: This study has revealed the existence of several common misconceptions about the prepuce and demonstrates the incidence of various prepuce lesions among the population.

Keywords: Chronic balanoposthitis, Condylomata acuminatum, Phimosis, Prepuce.

Introduction

The prepuce or foreskin is a layer of skin that covers the glans penis. It is a double-layered fold in which the outer layer is a continuation of the skin over the glans penis and the inner layer resembles a mucous membrane. A sheath of muscle known as the dartos muscle is present beneath the skin.

World Health Organization (WHO) states that the prepuce is not just a vestigial organ but has a possible implication in keeping the glans penis moist, protecting it in utero and enhancing sexual pleasure.¹ The blood supply to the preputial skin is from superior and inferior external pudendal arteries. The nerve supply to the penis is by the dorsal nerve of the penis.² The formation of the prepuce begins dorsally almost at 12 weeks of gestation with the ventral completion of the prepuce at about 16 weeks of gestation.³

While some cultures insist on male circumcision, the surgical removal of preputial skin, it is not widespread in India. According to a WHO report, in 2007 less than 20% of the male population in India were circumcised.¹ The preputial skin is usually non-retractable at birth as it is still attached to the glans penis (physiological phimosis). It becomes easily retractable in early childhood from about 2 to 6 years without any pain or tightness.

Any abnormality in the preputial skin can result in phimosis, the inability to retract the preputial skin or balanoposthitis, inflammation of the foreskin. Aposthia refers to a condition in which the prepuce is absent at birth. Micropathia refers to a condition in which the prepuce does not fully cover the glans penis.

Pathological phimosis is a condition in which the prepuce gets adhered to glans penis secondary to adhesions or scarring due to infection, inflammation or trauma.

Pathological phimosis and physiological phimosis with recurrent attacks of balanoposthitis or UTIs require treatment.⁴ Penile lesions may be due to infections caused by microorganisms such as *Candida albicans*, *Trichophyton rubrum*, etc. Non-infectious penile lesions can be classified by clinical presentation as papulosquamous (e.g., psoriasis), inflammatory (e.g., lichen sclerosus, lichen nitidus, lichen planus), vascular (e.g., angiokeratomas), or neoplastic (e.g., carcinoma in situ, invasive squamous cell carcinoma).⁵

This study aims to analyse the spectrum of lesions occurring in the preputial skin of patients and observe the histomorphological changes in various lesions.

Materials and Methods

This is a cross-sectional retrospective study. All cases related to preputial skin sent for analysis to the Department of Pathology in our institution over a period of 10 months (March 2018 to December 2018) have been included in this study. None of the cases were excluded as all the reported cases contained adequate material. A sample size of 93 was analyzed. All patients whose preputial biopsy samples were sent for preputial skin analysis have been included in this study regardless of age, presenting complaints, etc. Data regarding the age of the patient, clinical presentation, and histopathological findings were collected from archives of Pathology and a complete analysis was carried out.

Results

This retrospective study was done in the Department of Pathology of Saveetha Medical College with a sample size of 93. All the 93 patients had sent a sample of their preputial skin to the pathology laboratory for histopathological analysis. The following findings were observed from the collected data.

The inability to retract the preputial skin was found to be a very common clinical presentation with all 93 patients complaining of the same. Along with this symptom, patients also experienced variety of other symptoms. Out of the 93 patients, 9 patients presented with difficulty in micturition, 7

patients presented with burning micturition, 7 patients presented with ballooning of prepuce, 7 patients presented with recurring UTI and 6 patients presented with pain in glans penis as shown in Fig. 1.

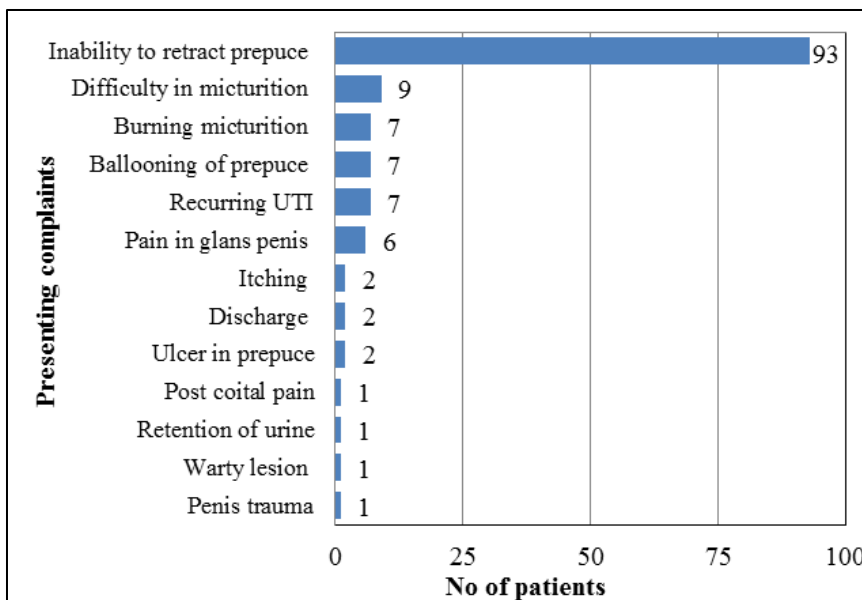


Fig. 1: Clinical Presentations

It was found that histomorphological changes in the prepuce were more common in the age group of 21 to 30 years (23%) with patients between 0 to 10 years coming in as a close second (19%) as shown in F 2.

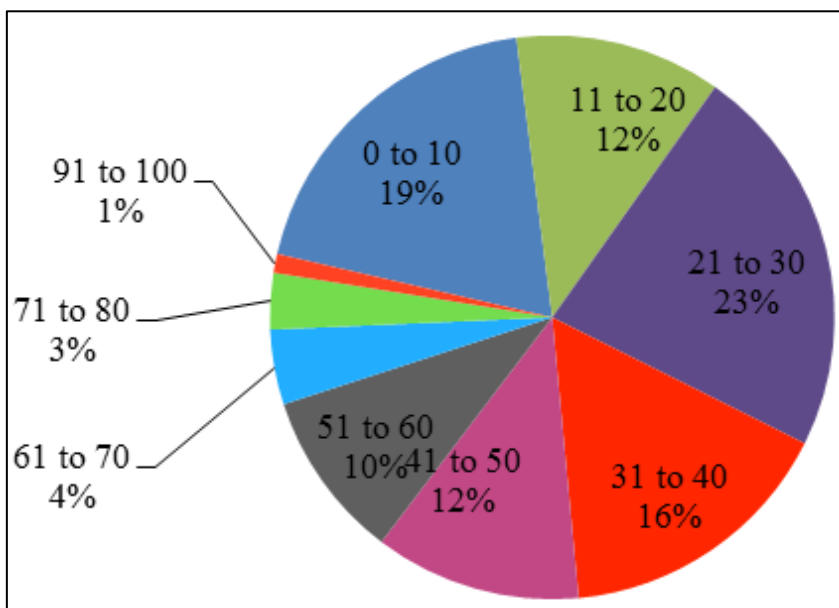


Fig. 2: Age distribution of preputial lesions

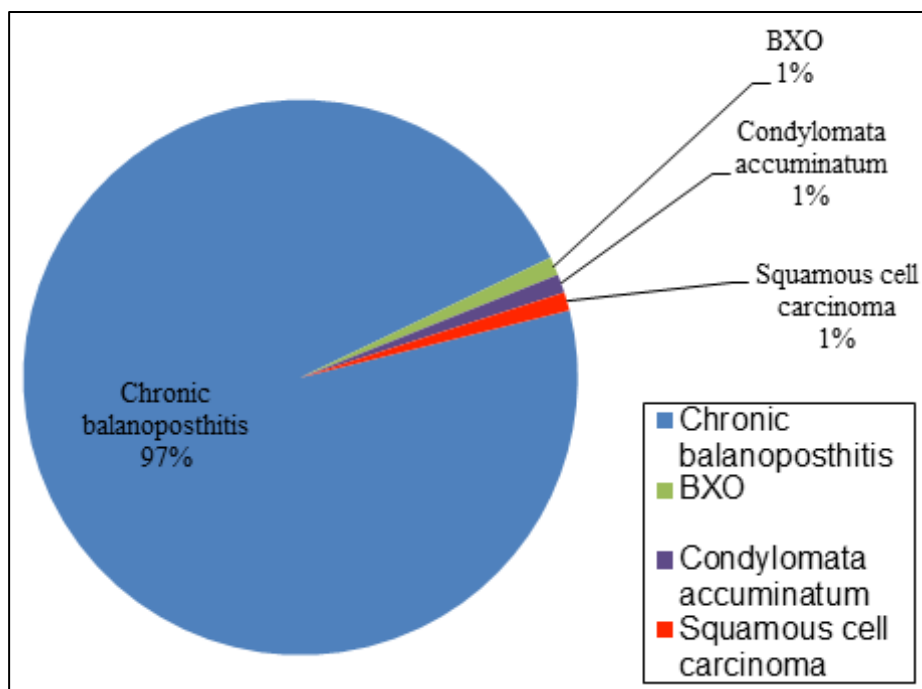


Fig. 3: Histopathological Diagnosis

The distribution of various prepuce lesions among the different age groups was found to be uneven. Chronic balanoposthitis was found to be a common diagnosis in all age groups. Whereas balanitis Xerotica Obliterans (BXO) was noted in the age group 11 to 20. Condylomata accuminatum was diagnosed in the age group 51 to 60. Squamous cell carcinoma was found to be more common in elderly males occurring in the age group 71 to 90.

Histopathological findings in the samples sent suggest that 97% of the patients suffer from chronic balanoposthitis. Another 1% was affected with BXO, 1% with condylomata accuminatum. 1% of the population was diagnosed with squamous cell carcinoma as shown in Fig. 3.

Balanoposthitis presented as a nonspecific inflammatory infiltrate with lymphocytes, plasma cells and macrophages. Epithelial changes such as squamous hyperplasia and ulceration were also noted in some cases.

Balanitis Xerotica Obliterans presented as thinning of epidermis with edematous and sclerosed lamina propria. Basal vacuolar degeneration of basal layer, diffuse fibrosis and dense band like infiltrate of lymphocytes were also be observed

Condylomata accuminatum presented as acanthosis, parakeratosis, hyperkeratosis and a prominent granular layer with superficial chronic inflammatory infiltrate in the dermis. Perinuclear cytoplasmic “halos” with slightly enlarged hyperchromatic nuclei (koilocytosis) were seen in superficial epithelial cells.

Squamous cell carcinoma presented as a neoplasm in the stroma as irregular nests and sheets of squamous cells, with varying degrees of pleomorphism, individual cell keratinization and keratin pearl formation.

Discussion

Normal histology of the prepuce shows that the surface is lined by variably keratinized stratified squamous epithelium. It has a ridged appearance and is rich in nerves, Schwann cells, Meissner's corpuscles, lymphoid cells, and capillaries. Inner mucosa is devoid of hair follicles, sweat glands and sebaceous glands but contains smooth muscle bundles.⁶

A study by Sneppen et al shows that among all boys aged 0-18 with foreskin-related problems, 95% reported with complaints of phimosis or the inability to retract the preputial skin.⁷ A similar observation was recorded in our study with all 93 patients (100%) complaining of inability to retract prepuce. The same study reported that 27% of the study population complained of difficulty in micturition or pain during micturition.⁷ This resembles the results of our study in which 16 patients (17%) complained of either difficulty in micturition or burning micturition.

A Brazilian study demonstrated that cutaneous lesions were observed in 15.2% of the participants. It was found that balanoposthitis was responsible for a majority (77.6%) of the lesions.⁸ Our study showed a similar result with chronic balanoposthitis being the diagnosis for over 97% of the study population.

Condylomata accuminatum is a Human papilloma virus infection that presents as a wart in the genital region with the sub preputial region being the most common site. It is predominantly a sexually transmitted disease although other modes of transmission do exist.⁹ A study by Kliewer et al. reveals that 0.17% of men were diagnosed with anogenital warts or condylomata accuminatum.¹⁰ In our study, 1% of the study population was affected with condylomata accuminatum.

Lichen sclerosus is a chronic, progressive, sclerosing inflammatory dermatosis of unclear etiology. In men, genital involvement is termed as Balanitis Xerotica Obliterans. A study regarding pediatric preputial pathology reported that 84.8% of the excised foreskins showed a suggestion histomorphological abnormalities with 34.5% of specimens having evidence suggestive of BXO.¹¹ Balanitis xerotica obliterans (BXO) is associated with 4–6% of patients with penile squamous cell carcinoma (SCC). Hence, proper follow up is required to manage the disease. Sometimes the patients present with obstructing voiding symptoms due to severe phimosis.¹² A similar study by Naji et al on histomorphological changes in the preputial skin reported that in 8 cases (15%), histological evidence of BXO was observed.¹³ The findings of our study differ from these observations with only 1% of study population being diagnosed with BXO.

The European Association of Urology reports that squamous cell carcinoma of the penis have the highest incidence among other penile carcinomas with a frequency of 48% to 65%. The EAU also states that penile squamous cell carcinoma arises from the inner epithelium of the prepuce or the glans.¹⁴ Our study reported only one case of preputial carcinoma which also turned out to be squamous cell carcinoma

An American study found that only 7% of the non-cancer study population were phimotic, whereas phimosis was frequent (52%) in the patients with squamous cell carcinoma of the penis.¹⁵ A similar finding was observed in our study with phimosis being observed in the squamous cell carcinoma case reported in our study.

As the prepuce is found to play an essential role in keeping the glans penis moist, it is important to preserve the preputial skin whenever possible. Recent findings demonstrate that the prepuce can be preserved in selected cases of penile degloving procedures, phimosis or hypospadias repair, and penile cancer resection.¹⁶

Conclusion

From this study, we can conclude that the incidence of preputial pathology was high in patients aged 21-30 years with chronic balanoposthitis being a common diagnosis in all age groups. The small sample size of this study (93 patients) may limit the results of the study from defining the real incidence of this disease. But this study gives an approximate idea of the conditions ailing the prepuce. The results of this study reveals the existence of several misconceptions related to preputial skin lesions with several conditions remaining unreported due to the stigma associated with the preputial skin. Preputial abnormalities should not be ruled out as phimosis as it may also be a sign of penile carcinoma or condylomata acuminatum. Early diagnosis, appropriate treatment and the necessary

surgical intervention are essential for the continued well-being of the patients.

Conflict of Interest: None.

References

1. Weiss H, Polonsky J, Bailey R, Hankins C, Halperin D. Male circumcision: global trends and determinants of prevalence, safety and acceptability. World Health Organization and the Joint United Nations Programme on HIV/AIDS (UNAIDS). 2007.
2. Cold CJ, Taylor JR. The prepuce. *BJU international*. 1999;83(S1):34-44.
3. Liu X, Liu G, Shen J, Yue A, Isaacson D. Human glans and preputial development. *Differ* 2018;103:86-99.
4. Kumar R, Pareek R. A Holistic approach to Phimosis in Children. *J Ayurveda Integr Med Sci* (ISSN 2456-3110). 2018;3(1):66-9.
5. Teichman JM, Mannas M, Elston DM. Noninfectious Penile Lesions. *Am Family Physician* 2018;97(2).
6. Taylor JR, Lockwood AP, Taylor AJ. The prepuce: specialized mucosa of the penis and its loss to circumcision. *Br J Urol* 1996;77(2):291-5.
7. Sneppen I, Thorup J. Foreskin morbidity in uncircumcised males. *Pediatr* 2016;137(5):e20154340.
8. Romero FR, Romero AW, Almeida RM, Oliveira Jr FC, Tambara Filho R. Prevalence and risk factors for penile lesions/anomalies in a cohort of Brazilian men ≥ 40 years of age. *Int Braz J Urol* 2013;39(1):55-62.
9. Buechner SA. Common skin disorders of the penis. *BJU Int* 2002;90(5):498-506.
10. Kliewer EV, Demers AA, Elliott L, Lotocki R, Butler JR et al. Twenty-year trends in the incidence and prevalence of diagnosed anogenital warts in Canada. Sexually transmitted diseases. 2009 Jun 1;36(6):380-6.
11. Yardley IE, Cosgrove C, Lambert AW. Paediatric preputial pathology: are we circumcising enough? *Ann Royal Coll Surg Engl* 2007;89(1):62-5.
12. Chipollini J, De la Rosa AH, Azizi M, Shayegan B, Zorn KC et al. Patient presentation, differential diagnosis, and management of penile lesions. *Can Urol Assoc J* 2019;13(2S1).
13. Naji H, Jawad E, Ahmed HA, Mustafa R. Histopathological examination of the prepuce after circumcision: Is it a waste of resources?. *Afr J Paediatr Surg* 2013;10(2):164.
14. Hakenberg OW, Compérat EM, Minhas S, Necchi A, Protzel C. EAU guidelines on penile cancer: 2014 update. *Eur Urol* 2015;67(1):142-50.
15. Velazquez EF, Bock A, Soskin A, Cudas R, Arbo M. Preputial variability and preferential association of long phimotic foreskins with penile cancer: an anatomic comparative study of types of foreskin in a general population and cancer patients. *Am J Surg Pathol* 2003;27(7):994-8.
16. Haseebuddin M, Brandes SB. The prepuce: preservation and reconstruction. *Curr Opin Urol* 2008;18(6):575-82.

How to cite this article: Kavya S, Harikrishnan V, Srinivasan C. A study of histo-morphological changes of preputial skin. *Arch Cytol Histopathol Res* 2019;4(2):150-53.