

## Adenoid Cystic Carcinoma of Hard Palate: A Case Report and review of literature

Shrikant Sonune<sup>1,\*</sup>, Suyog Tupsakhare<sup>2</sup>, Kishor Patil<sup>3</sup>, Mahesh Gabhane<sup>4</sup>,  
Shilpa Kandalgaonkar<sup>5</sup>, Shraddha Walekar<sup>6</sup>

<sup>1</sup>Senior Lecturer, <sup>2</sup>Reader, <sup>3</sup>Senior Lecturer, <sup>4</sup>Senior Lecturer, <sup>5</sup>Professor, <sup>6</sup>Postgraduate Student,  
Dept. of Oral Pathology & microbiology, SMBT Dental College & Hospital, Sangamner, Maharashtra, India

**\*Corresponding Author:**

E-mail: drshrikantwinner@gmail.com

### ABSTRACT:

Salivary gland neoplasm of the head and neck region are consisting of 1-5% of the total malignancies. Adenoid cystic carcinoma (ACC) is the one of the most common malignancy of the salivary gland. It is considered as one of the an intermediate grade of salivary gland neoplasms. ACC is characterized by slow growth, which causes extensive invasion and aggressive ability for early metastatic deposits, the factors which makes the behavior of the neoplasm aggressive. Here with, reporting a case of adenoid cystic carcinoma involving the left side of the hard palate, along with its review of literature.

**Key words:** Adenoid Cystic Carcinoma, Palate, Salivary gland neoplasm.

### INTRODUCTION

Adenoid cystic carcinoma is one of the common salivary gland malignancy. It is clinically deceptive due to its small size and slow growth, which results in its extensive invasion and ability to metastasize in early phases. The factors which make the prognosis of the neoplasm questionable when present.<sup>1</sup> These tumors can originate from any type of salivary gland tissue; however almost half of them occur in minor salivary glands, while the other 50% involve the parotid and submandibular glands.<sup>2</sup>

Typically, ACC shows slow growth with high propensity for spread through perineural sheath, local recurrence and distant metastatic deposits involving bones, lung, and liver.<sup>3</sup> Histologically, three growth patterns can be recognized for ACC are solid, tubular and cribriform. This histological typing is important for prognosis. Tubular pattern has the best prognosis, the predominant solid pattern the worst, being associated with the highest incidence of distant metastasis and perineural infiltration with, consequently, 15 years survival rate of 5%.<sup>2,3</sup>

Here, reporting a case of ACC in 60 yr male patient involving the left posterolateral part of the hard palate.

### CASE REPORT

A 60 year old male patient reported to the Department of Oral Pathology, Microbiology and Forensic Odontology, SMBT Dental College, Hospital and Postgraduate research institute, Sangamner, with the chief complaint of swelling in upper back teeth region since 2-3 months. The history reveal that swelling had started insidiously and had steadily increased to present size. The swelling was associated with dull aching continuous pain which was started 1½ months ago. Recently patient also

experienced tingling sensation in the region of left ala of nose & cheek. No history of any discharge, trauma.

Medical, Surgical, Family and Personal histories were not noteworthy. With respect to dental history, patient gives history of exfoliation of upper left posterior teeth one year before. Patient was conscious cooperative average in built and all vital signs were within acceptable range on the day of presentation.

Extraoral examination (Fig 1) reveals diffuse swelling in left side zygoma region, 4 X 6 cm in size, extending superoinferiorly from level of outer canthus of eye up to ala-tragus line, mediolaterally from left ala of nose till zygomatic prominence. Overlying skin was normal and not fixed to the lesion. On palpation local temperature was slightly raised. The swelling was tender, firm to hard in consistency, No regional lymphadenopathy was found.

On inspection, introrally (Fig 2) swelling is present in left posterolateral part of hard palate on edentulous ridge extending from midpalatine raphe up to buccal vestibule. Swelling is smooth on palatal side; on ridge area it shows ulceroproliferative growth along with nodular swelling obliterating buccal vestibule. On palpation swelling is soft to firm in consistency showing erythematous areas in the region of ulcer. Swelling does not show any sinus or fistula formation. No discharge, no sloughing is present.

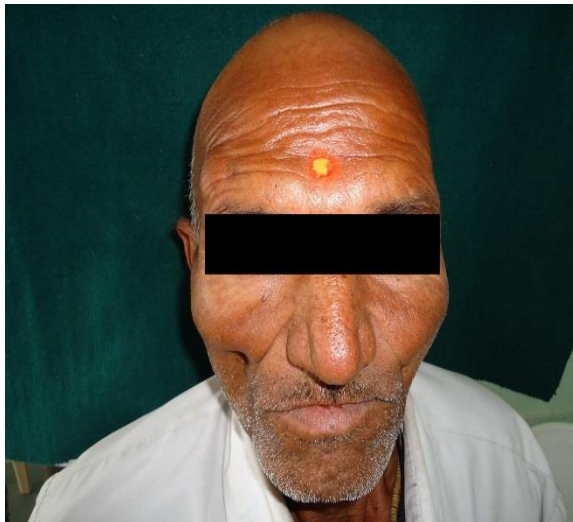On the basis of history and clinical examination, the lesion was diagnosed provisionally as salivary gland neoplasm. The clinical differential diagnosis includes reactive or inflammatory condition of minor salivary glands, low grade malignancy involving maxillary sinus and benign or low grade neoplasm of mesenchymal origin of maxilla.

Panoramic radiographic examination shows lesion cause destruction of left palatal vault lateral margin of nasal cavity and median nasal septum is deviated slightly to right side. The floor of maxillary sinus appears to be completely eroded by the extension of the lesion into the sinus.

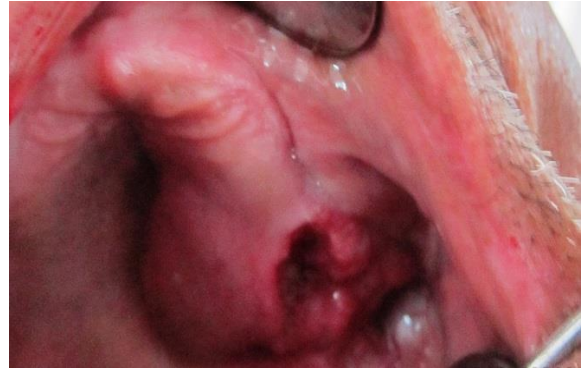Radiographic examination of Water's sinus view (Fig 3) shows diffuse radio opacity in left maxillary sinus, obliterating the sinus space, Mediolaterally extending from median nasal septum up to zygoma. Superoinferiorly extending from lower border of orbit involving palate. Computed tomography (Fig 4) shows heterogeneous soft tissue density mass involving left nasal cavity maxillary sinus and infratemporal fossa with ill-defined margins medially and posteriorly with erosion of the lower border of orbit. This suggest that growth has invaded in maxillary sinus cavity.

X-ray chest reveal no plural or parenchymal abnormalities. Incisional biopsy was done and tissue send for evaluation. Hematoxylin and Eosin stained tissue section (Fig 5, 6) shows proliferation of isomorphic population of cells arranged in cribriform, tubular and solid pattern, with predominant cribriform pattern. Isomorphic cell population shows large hyperchromatic nuclei with scanty eosinophilic cytoplasm, increased nuclear cytoplasmic ratio. At places duct like spaces are seen which are filled with homogeneous eosinophilic material.

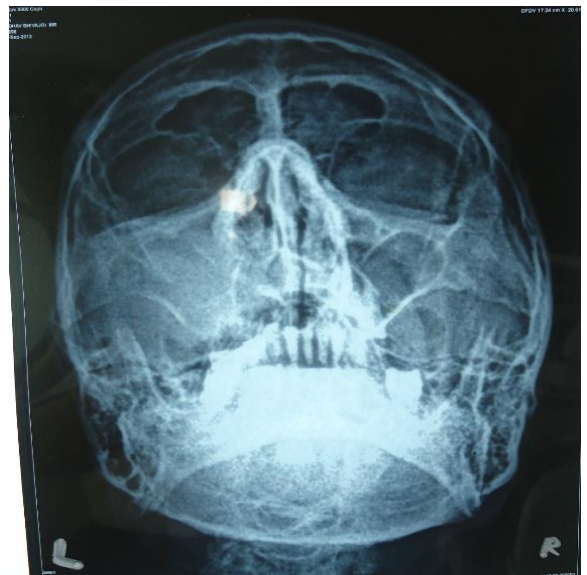The histopathological impression was suggestive of ACC. Patient was referred to regional cancer centre for further treatment. Left subtotal maxillectomy was done. Six month follow up after treatment did not reveal any local recurrence of lesion. In order to rule out lung metastases, X- ray chest was done which did not reveal any pleural or parenchymal abnormalities.



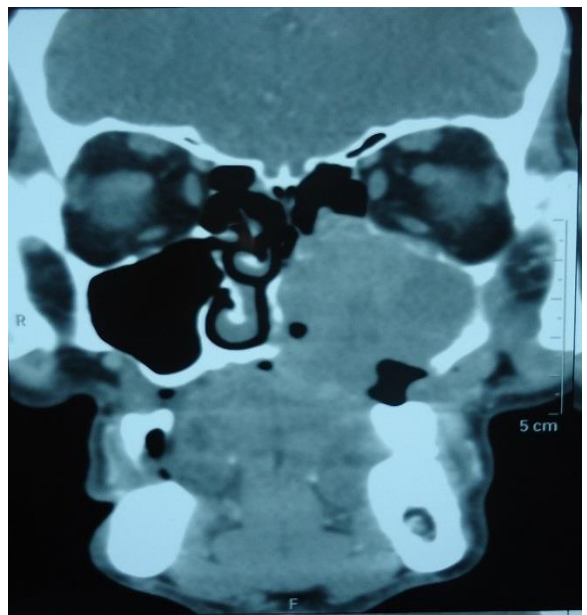**Fig. 1: Clinical presentation with Extraoral view**



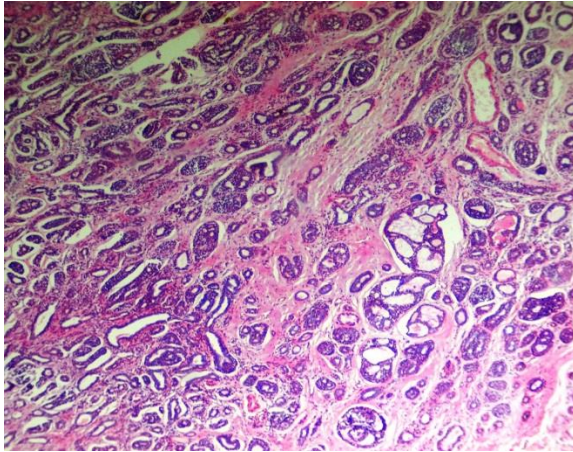
**Fig. 2: Clinical presentation with Intraoral view**



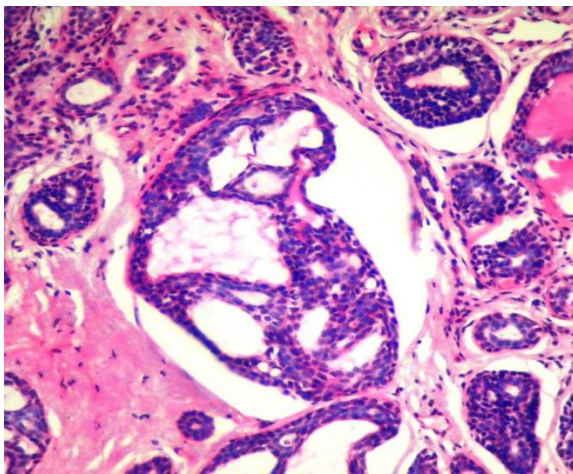
**Fig. 3: Radiographic presentation with Water sinus view**



**Fig. 4: Computed tomography**



**Fig. 5: Histopathological Presentation (100x)**



**Fig. 6: Histopathological Presentation (400x)**

## DISCUSSION

ACC was first described by Billroth in 1859.<sup>4</sup> The term 'adenoid cystic carcinoma' was introduced by Ewing (Foote and Frazell) in 1954.<sup>5</sup> According to Eveson and Cawson, ACC is seen mostly in middle age adults with slight female predilection.<sup>5</sup> In the present case, patient was 60-year-old male.

ACC can occur in any salivary gland but, approximately 50-60% develops within minor salivary glands. The palate being the most common site for minor salivary gland tumors. The other tumors sites are parotid & submandibular glands with fairly even distribution in these two sites.<sup>5</sup>

Other oral sites include tongue; buccal mucosa and lower lip with rare occurrence. Extraoral sites are mucous glands of upper airway, bronchial glands, sweat glands, ceruminous glands of ear, breast & vulva.<sup>6</sup> In the present case, ACC was involving the intraoral minor salivary glands of posterior palatal region. It is most common site of involvement with ACC.<sup>4</sup>

Pain is the common and important finding, occurring early in the course of the disease before

there is a noticeable swelling is observed.<sup>5</sup> Present case shows different clinical course, i.e. first and foremost feature of prominent swelling is present and as the growth continues then pain is experienced by the patient. Such clinical course is explained by Ellis GL et al.<sup>6</sup> Intraoral ACC are uncommon and characterized by slow growth, protracted clinical course, multiple and/or delayed recurrences and late distant metastases. Tumors in the palate or maxillary sinus may show radiographic evidence of bone destruction.<sup>5</sup> Present case showing the palatal bone destruction, also involving floor of orbit, extending upto median nasal septum and extend up to zygoma.

The clinical behavior of ACC is a paradoxical initially. Tumor growth is slow, but its clinical course is progressive.<sup>6</sup> It invades tissues and gets fixed to underlying structures and skin.<sup>7</sup> Secondly, operative intervention is usually feasible, but multiple local recurrences are common. Third, metastatic spread to regional lymph nodes is uncommon, but distant spread to the lungs and bones is usually seen. Lymphatic spread is uncommon however, in very extensive cases, may be involved by direct extension. In long standing cases distant metastasis occurs through the blood stream most commonly to the lungs and bones.<sup>8</sup>

Five year survival rates are high, 10 to 20 year survival rates are drastically low.<sup>6</sup> ACC possess a strong neurotropism, with a tendency to invade nerves adjacent to the lesion.<sup>9</sup> It shows perineural spread towards the skull base.<sup>7</sup> Present case showing slow progressive growth; do not show lymph node involvement and metastasis.

## HISTOPATHOLOGY AND GRADING OF THE TUMOR<sup>10</sup>

Growth patterns and cytological details in ACC establish the diagnostic criteria and grading for this neoplasm. The primary three growth patterns are seen in adenoid cystic carcinoma.

**a. Cribriform variant:** Extensive sheets, or cribriform nests composed of small, hyperchromatic nucleus slightly separated basal/myoepithelial cells and small, at times inconspicuous duct like structures, containing secretory products. Round to oval, often fairly uniformly sized intercellular spaces are seen, termed as pseudo cysts. Pseudo cyst containing granulofibrillar material at times with a reticular pattern, which develop in relation to the basal/myoepithelial cells.

**b. Tubular variant:** Presence of bilayered duct like structures are seen which are composed of an inner layer of cuboidal to columnar ductal cells with moderate amounts of eosinophilic cytoplasm and outer, smaller hyperchromatic cells.

**c. Solid variant:** Arranged as variable, at times fairly uniformly sized groups or as sheets of small, hyperchromatic tumor cells, which are excess



proliferations of the basal/myoepithelial cell component. Small duct like structures must be identifiable among the basaloid cells. Cells with the above features, with nests or sheets of basaloid form 30% or more of the neoplasm.

Grading of the tumor.

**a. GRADE I:** The tumor consisting only of cribriform and tubular pattern.

**b. GRADE II:** A mixture of cribriform, tubular and solid growth patterns, but solid growth pattern less than 30% of the tumor.

**c. GRADE III:** Tumors with predominantly solid growth pattern. (>30% or more of the tumor). The most important prognostic factors include primary lesion size (T), anatomical localization, presence or absence of metastasis (M) at diagnosis time, invasion of the facial nerve and the histopathology grade (G).<sup>11</sup>

CT scans are important to delineate the tumor mass, to plan the extent of surgery and to search for recurrences during follow up postoperatively.<sup>8</sup> Possible treatments of ACC include surgical therapy, radiotherapy, chemotherapy and combined therapy (surgery and radiotherapy, radiotherapy and chemotherapy), the latter being treatment of choice in most cases. Only surgical removal or radiotherapy may fail to eliminate the possibility of recurrence in surgical margins, as well as the occurrence of metastasis in cervical lymph nodes, lungs, bones and brain.<sup>9</sup>

## CONCLUSION

As salivary gland neoplasm being the diverse group of tumors, with different histological characteristics and behavior patterns, Long-term follow up of patients with salivary gland neoplasms is mandatory because of the frequently indolent but infiltrative behavior associated with late loco-regional recurrence and distant metastases of adenoid cystic carcinoma.

## REFERENCES

1. Marx R E, Stern D: Oral and Maxillofacial Pathology, A rational for diagnosis and management; page 550-3.
2. Khalili M, Salamat F; A 20-Year Retrospective Study of Salivary Gland Adenoid Cystic Carcinoma in a Sample of Iranian Patients 2009; ENT Journal, Vol. 6, No. 1, Page 1-5.
3. Soprani F, Armaroli V, Venturini A, Emiliani E., Casolino D.; A rare case of adenoid cystic carcinoma of the nasopharynx manifesting as Horner's syndrome: discussion and review of the literature. *Otorhinolaryngologica Italica* 2007; 27, 216-219.
4. R. B. Lucas, Pathology of tumors of the oral tissues, fourth edition, page: 330-35.
5. Neville, Damm, Allen, Bouquet; Oral and Maxillofacial Pathology, second edition, page: 426-8.
6. Ellis GL, Auclair PL, Gnepp DR, Adenoid cystic carcinoma, *Surgical Pathology of Salivary glands*, Philadelphia, WB Saunders, 1991; 333-346.
7. Kanneppady S K, Sakri S B, Chatra L, Prashanth Shenoy K. Adenoid Cystic Carcinoma – A Case Report And Review Of Literature. *Malaysian Dental Journal*. July-Dec 2010. Vol 31 No 2, Page 79-83.
8. Tripathi P, Nahar P, Padmavathi BN, Ahmed J, Adenoid Cystic Carcinoma of the Palate: A Case report with Review of Literature. *J Cancer Sci* (2010), 2: 160-162. doi:10.4172/1948-5956.1000043
9. Tincani AJ, Del Negro A, Araújo PP, Akashi HK, Martins AS, Altemani AM, et al. Management of salivary gland adenoid cystic carcinoma: institutional experience of a case series. *Sao Paulo Med J*. 2006; 124(1):26-30.
10. Dardick I, Color atlas/text of salivary gland tumor pathology, 149-57
11. Batsakis JG, Luna MA, el-Naggar A, Histopathologic grading of salivary gland neoplasms: III. Adenoid cystic carcinomas. *Ann Otol Rhinol Laryngol*. 1990;99(12):1007-9.